

EPILEPSY SURGERY

Teeradej Srikijvilaikul, M.D.

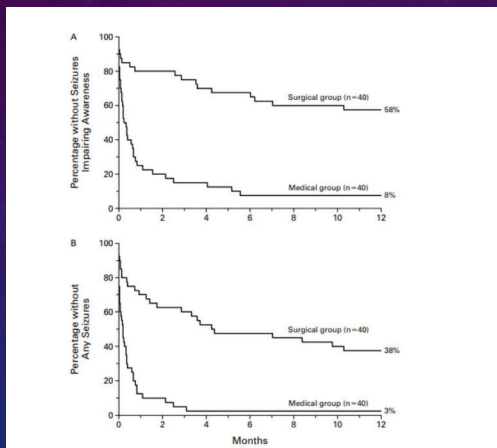
INDICATION

Intractable to medical treatment

- Acceptable seizure control cannot be achieved, despite adequate trials with potentially effective drugs, at dose or levels that are associated with no side effects or with acceptable side effects only
- At least 2 first-line drugs



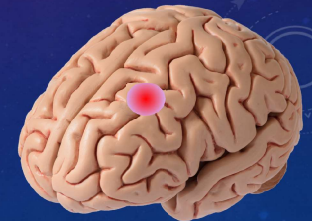Surgery vs AEDs



Wiebe S, et al. NEJM 2001; 345:311-318

“COMPLETE RESECTION OR DISCONNECTION OF THE CORTICAL AREAS OR NETWORKS RESPONSIBLE FOR GENERATION OF SEIZURES (EPILEPTOGENIC ZONE)”

- Resection
- Disconnection
- Laser ablation
- Focused ultrasound
- Thermocoagulation
- Radiosurgery



Strong anatomico-electro-clinical hypothesis

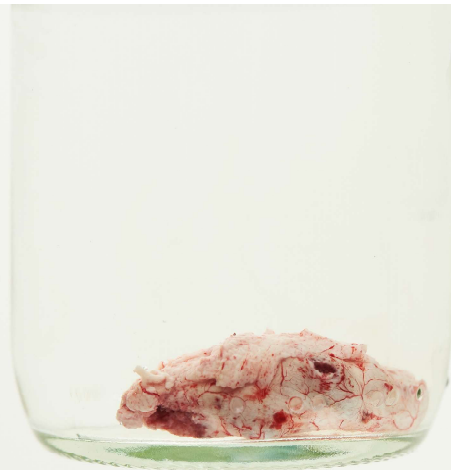MRI +ve	Invasive	MRI-ve	Invasive
Noneloquent	None	No lesion identified	SEEG
Eloquent	SDE/depth +/- SEEG		
Depth of sulcus	SDE/depth or EcoG/depth		
More than 1 lesions	SEEG		
Deep lesion (insula/cingulate)	SEEG		

Adapted from Najm I, Youmans & Winn 7th eds Textbook of Neurosurgery

Lesions

Focal

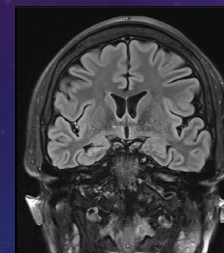
- Hippocampal sclerosis (Temporal)
- Cortical dysplasia
- Tumors
- Cavernoma
- AVM
- Misc



Hippocampal sclerosis

Outcomes after Temporal Lobectomy for Temporal Lobe Epilepsy with Hippocampal Sclerosis

Teeradej Srikijvilaikul MD*, Sukulya Lerdum MD**,
Supatporn Tepmongkol MD**, Shanop Shuangshoui MD***



- N=148, Mean FU 3.6 years (2-6 yrs)
- 95 (64.2%) Seizure free at least 2 years @ 2 yrs FU
- 47 (77.1%) Seizure free at least 2 years @ 4 yrs FU

Original Article

Long-Term Seizure Outcome after Temporal Lobectomy for Hippocampal Sclerosis

Teeradej Srikijvilaikul MD^{1,2}, Chusak Limotai MD^{3,4}

¹ Department of Neurosurgery, Prasat Neurological Institute, Bangkok, Thailand

² Prasat Neurological Epilepsy Center, Prasat Neurological Institute, Bangkok, Thailand

³ Chulalongkorn Comprehensive Epilepsy Center of Excellent, The Thai Red Cross Society, Bangkok, Thailand

⁴ Division of Neurology, Department of Medicine, Faculty of Medicine, Chulalongkorn University, Bangkok, Thailand

- 2004-2008 (single surgeon)
- N=112 , Mean 8.1 years (5-11 yrs)
- 61 (54.5% seizure free since surgery)
- 89.3% seizure free >2 years at last follow-up
- 43 (38% stopped AEDs)
- Preop 2nd GTC poor predictor

Cavernoma

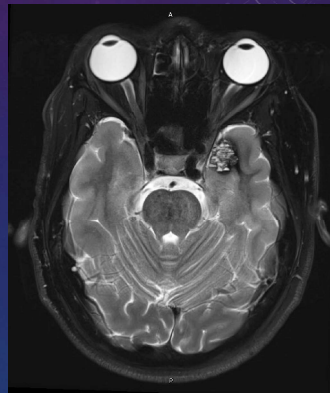
Temporal (N=27)

Lesionectomy (+ hemosiderin)

Lesionectomy + mesial structures
Lesionectomy & intraop EcoG

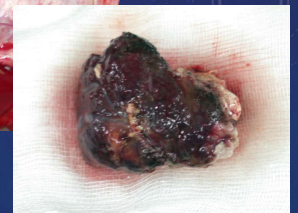
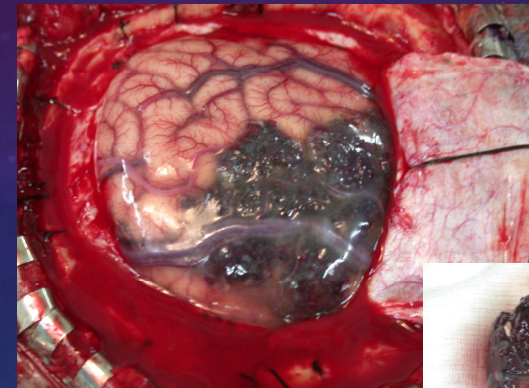
Reoperation (1)

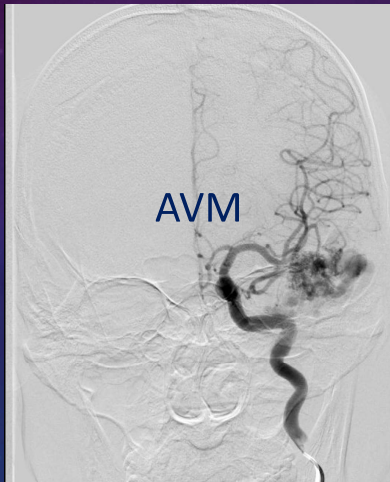
- Engel I 23 (85%)(Off AED 7)
- Engel II 1
- Engel IV 1



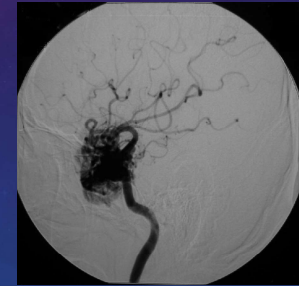
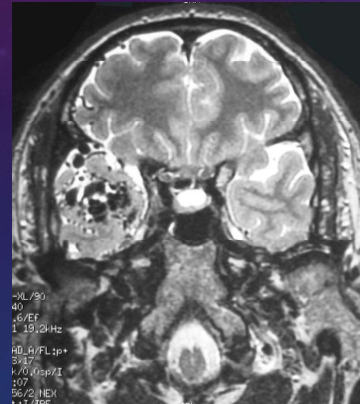
Extratemporal (N=7)

- Engel I 4
- Engel II 1
- Engel IV 1 (Pulvinar)





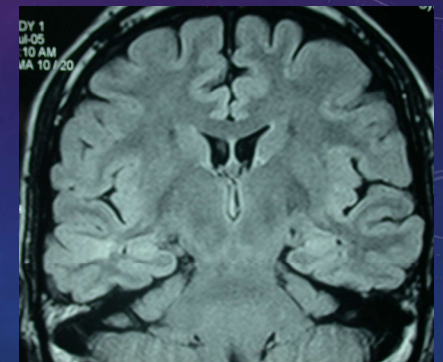
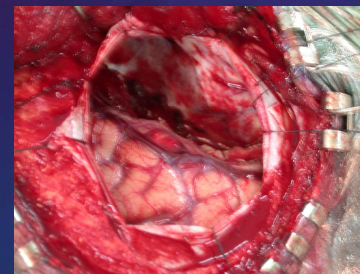
Embolization & Temporal lobectomy



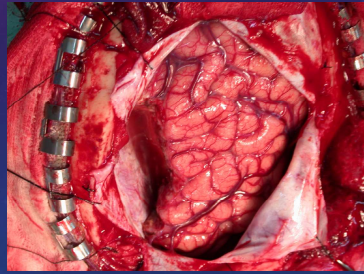
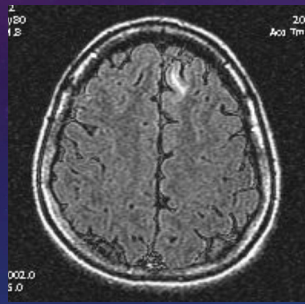
Focal cortical dysplasia

- N=56 Good outcome in FCD type II
- Complete removal of abnormal MRI

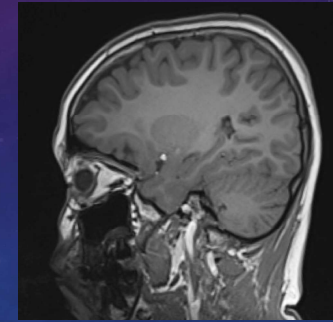
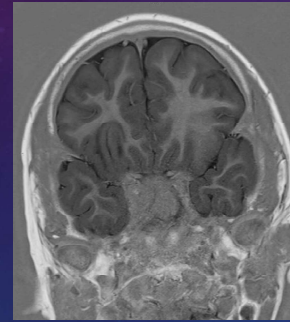
Temporal



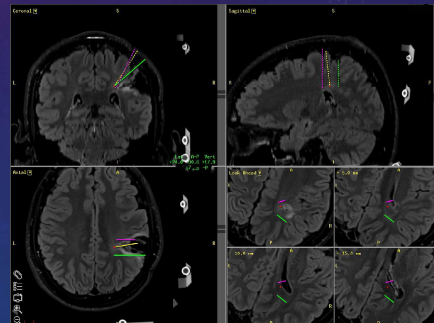
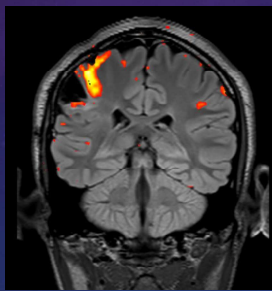
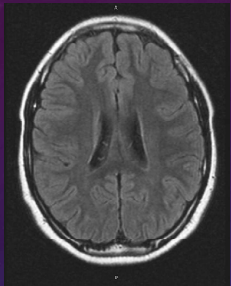
FCD



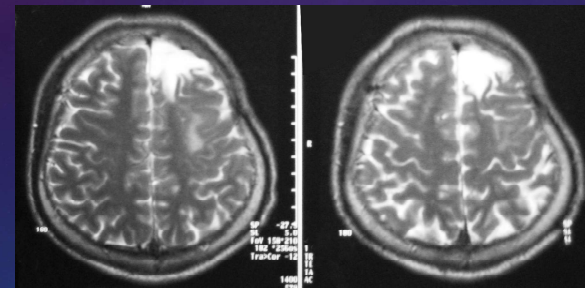
FCD



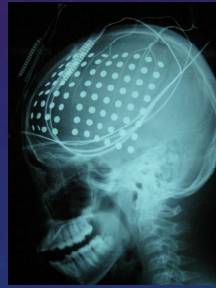
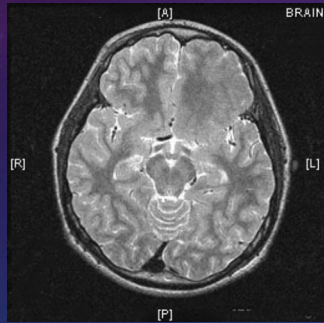
FCD recurrent seizures



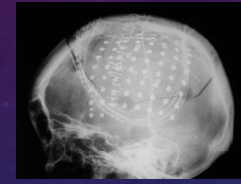
FCD



FCD

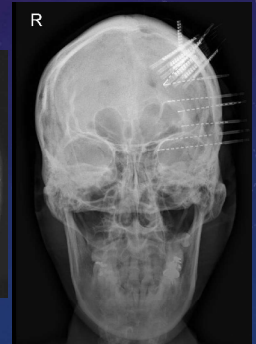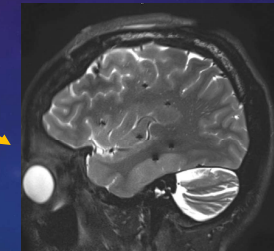


FCD



2005

VNS
2006

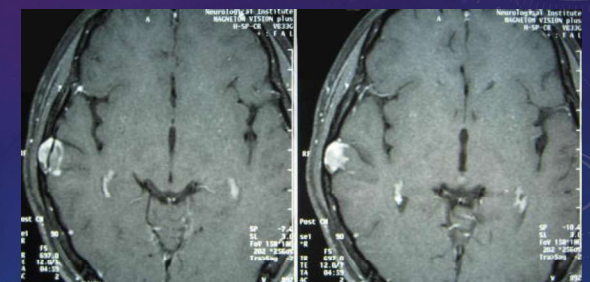
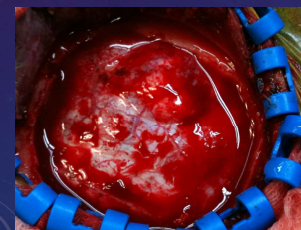
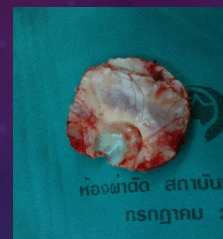

SEEG 2015

Tumors

- DNET
- Ganglioglioma
- Astrocytoma
- Oligodendroglioma
- PXA

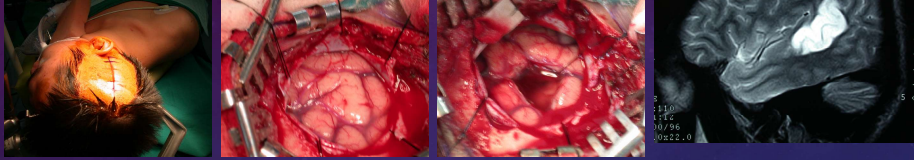
DNET



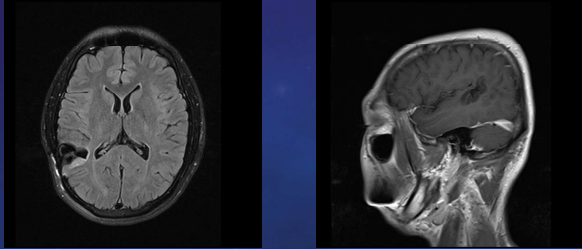
Lesionectomy & intraop ECoG

DNET

2004
Lesionectomy



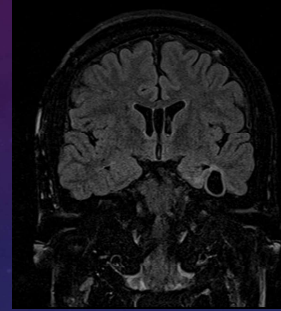
2012



DNET

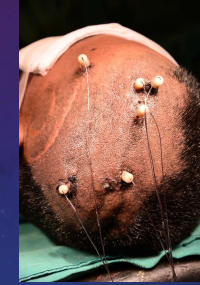2018

2012

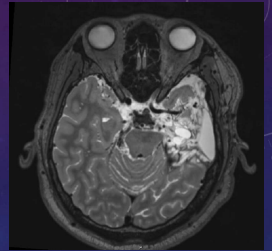


TL & AH

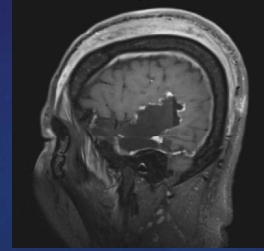
2017



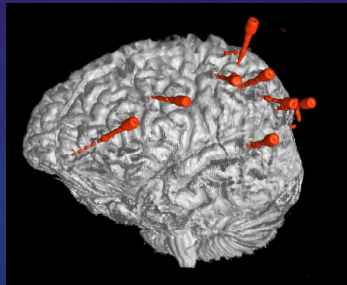
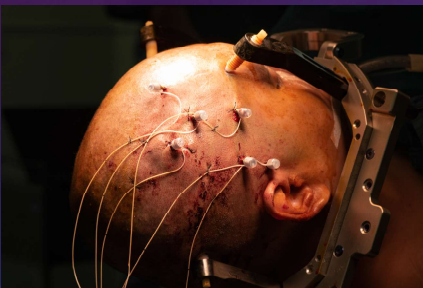
SEEG



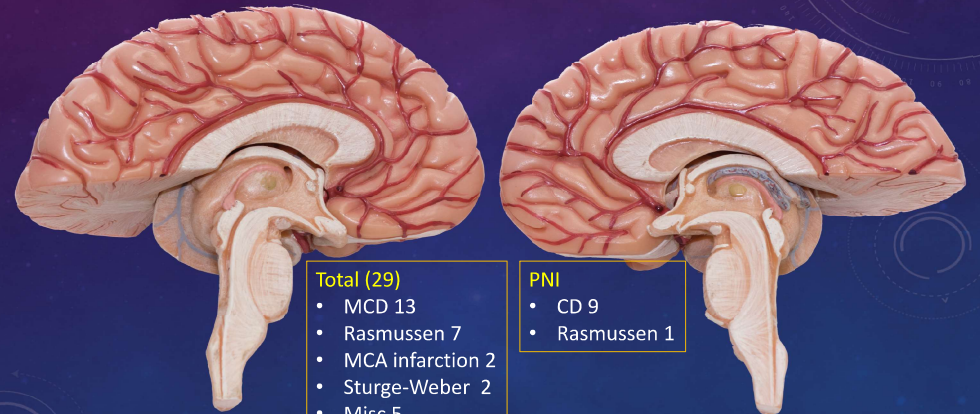
Extended resection



Nonlesional



Hemispherectomy



Total (29)

- MCD 13
- Rasmussen 7
- MCA infarction 2
- Sturge-Weber 2
- Misc 5


PNI

- CD 9
- Rasmussen 1

Hemispherectomy (2004-2011)

Outcomes	N	Engel I	Engel II-III
6 months	20	15 (75%)	5 (25%)
1 year	18	10 (55.6%)	8 (44.4%)

Wongyai P, Desudchit T, Srikijvilaikul T.



Thank you

Pediatric Epilepsy Surgery

8th-9th November 2018 Prasad Neurological Institute