

Epilepsy Surgery

An aerial photograph of a mountain range. The foreground is filled with a dense layer of white, fluffy clouds. Below the clouds, the rugged, brownish-grey peaks and valleys of the mountains are visible. The sky above is a clear, bright blue.

Teeradej Srikijvilaikul, M.D.
Prasat Neurological Epilepsy Center

Outlines

- Indications
- Definition of epilepsy surgery zone
- Presurgical evaluations
- Type of surgery

Epidemiology

- The 2nd most common chronic neurologic condition seen by neurologists
- Prevalence: 0.5-1% general population in developed countries
- Incidence 40-70/100,000 population (developed countries), 100-190/100,000 (developing countries)

Goal of therapy in epilepsy

- No seizures
- No adverse events
- Improvement of quality of life

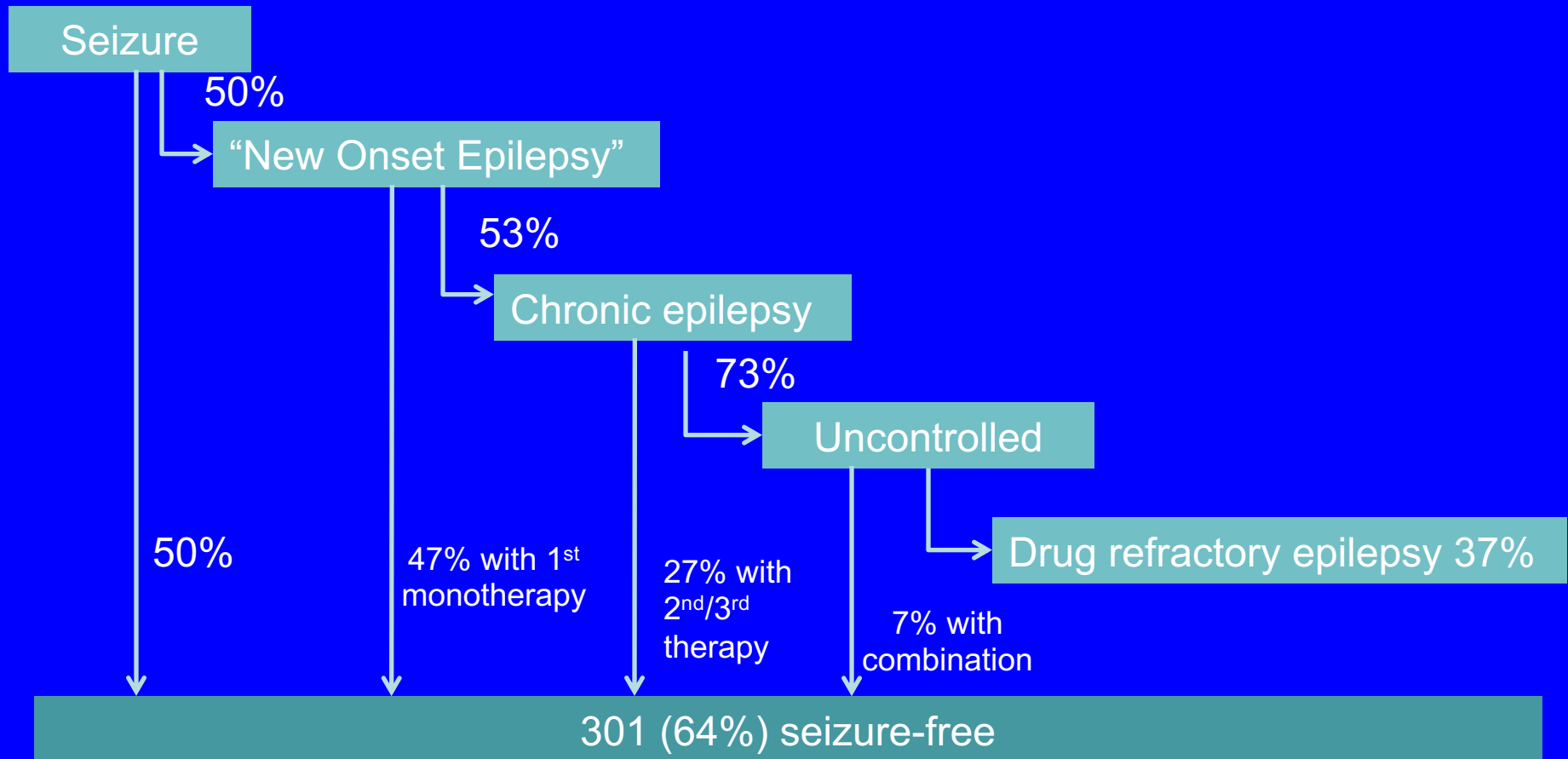
Indication

Intractable to medical treatment

- Acceptable seizure control cannot be achieved, despite adequate trials with potentially effective drugs, at dose or levels that are associated with no side effects or with acceptable side effects only
- At least 2 first-line drugs



Achievement of seizure freedom in newly diagnosed epilepsy (n=470)



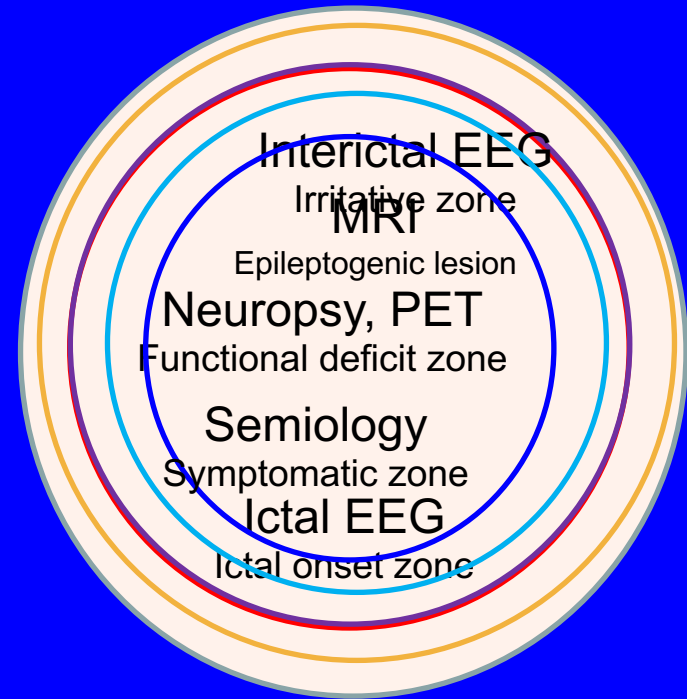
Preoperative workup

- Location
- Extension
- Adverse events

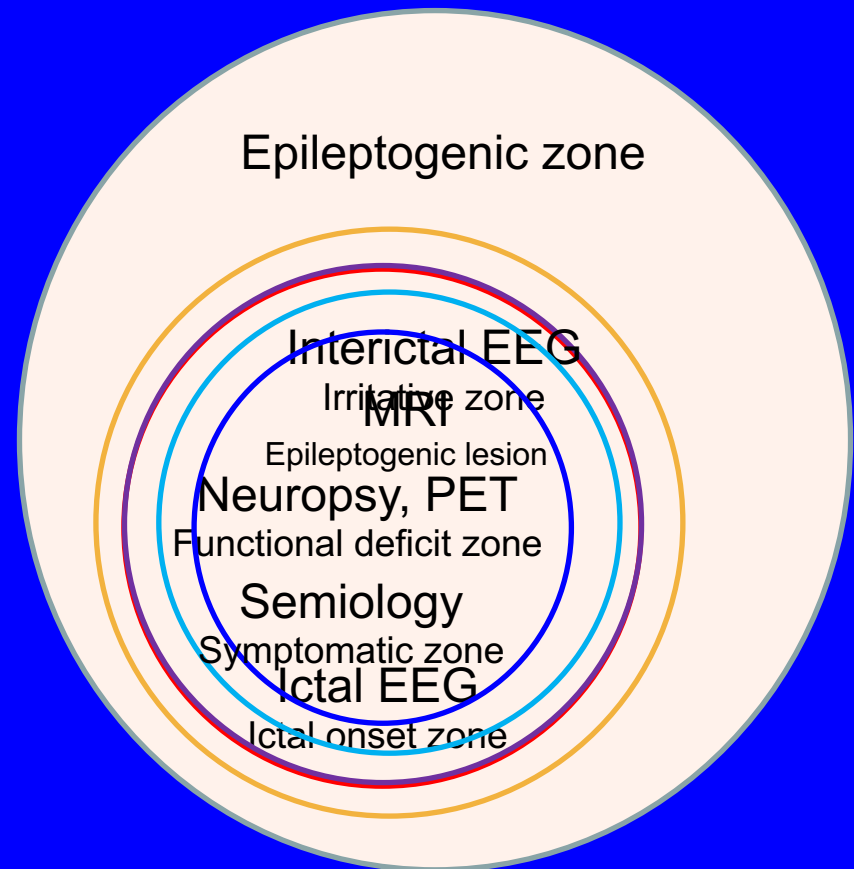
Principal considerations

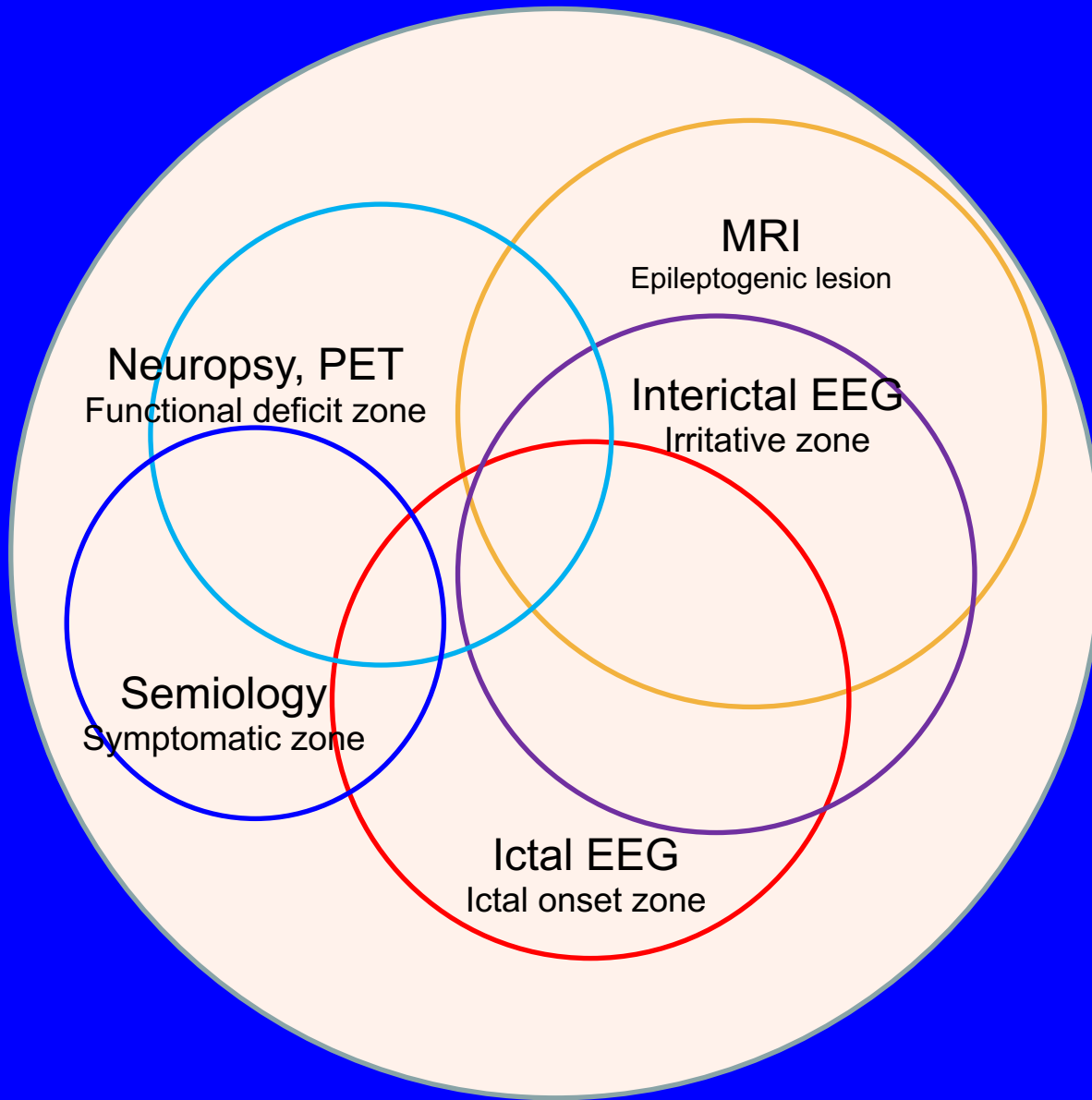
- Epileptogenic zone
- Symptomatogenic zone
- Irritative zone
- Ictal onset zone
- Epileptogenic lesion
- Functional deficit zone

Seizure Free



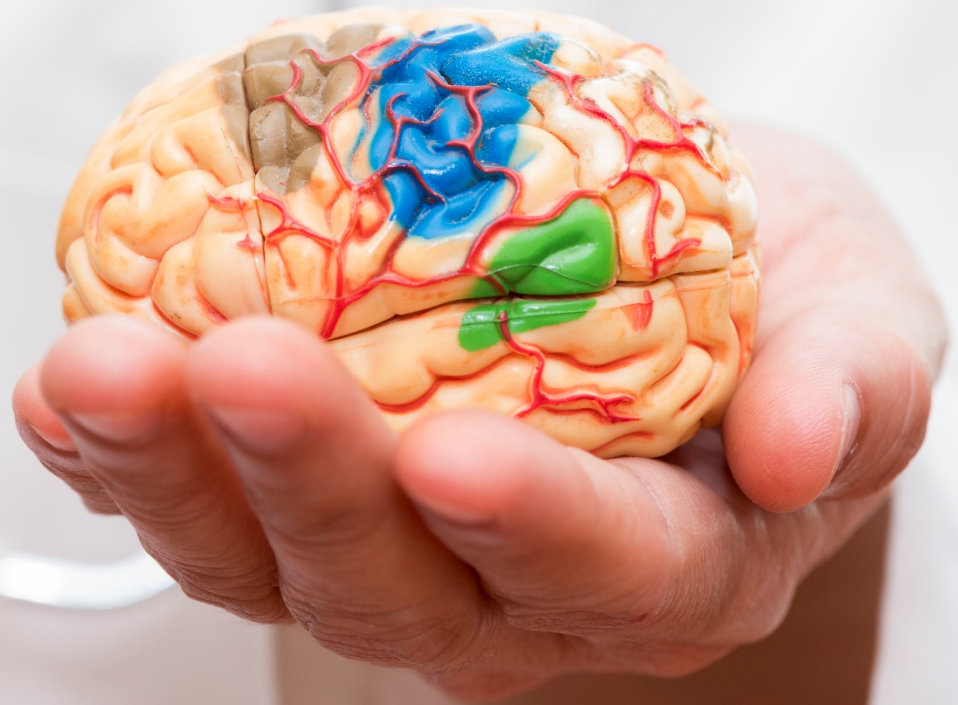- Seizure free with medication
- Seizure reduction
- Recurrent seizures





Presurgical evaluations

- H&P
- Routine EEG, 24-hour video EEG, MRI
- Neuropsychological test, neuropsychiatric evaluation
- Ictal SPECT, PET, fMRI



Epilepsy surgery

Resection

- Temporal lobectomy
- Extratemporal lobectomy
- Lesionectomy
- Hemispherectomy
 - Radiosurgery
 - Laser ablation
 - Thermocoagulation

Palliative

- Multiple subpial transections
- Corpus callosotomy
- Vagal nerve stimulation
- Deep brain stimulation
- Responsive neurostimulation

Surgically remediable syndrome

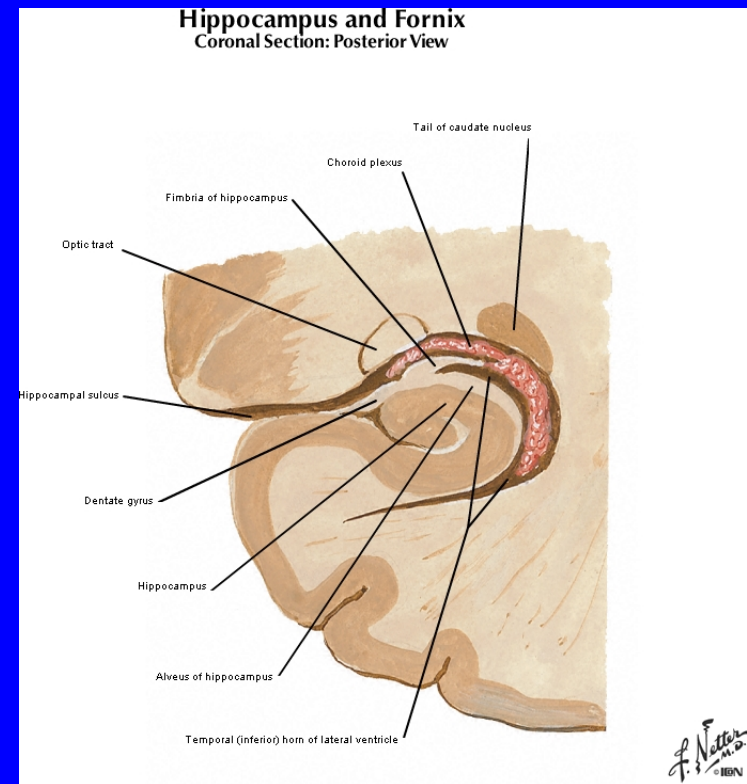
- Good understanding pathophysiology
- Frequently resistant or refractory to antiepileptic medications
- Noninvasive presurgical evaluation
- Good chance of seizure free after epilepsy surgery

Surgically remediable syndrome

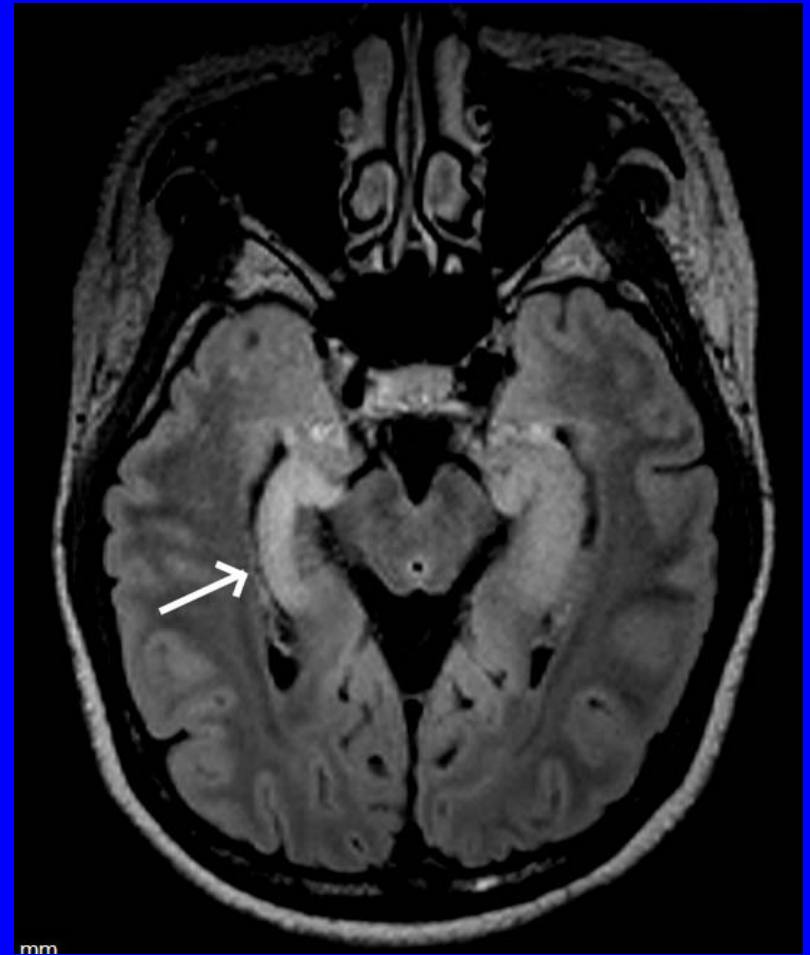
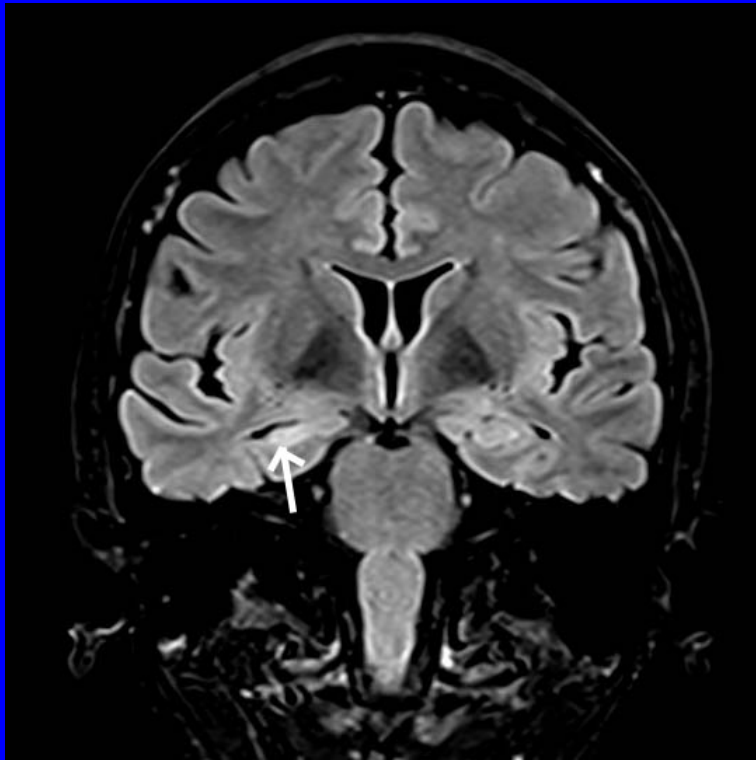
- Focal epilepsy syndrome
 - Mesial temporal lobe epilepsy (MTLE)
 - Hippocampal sclerosis
 - Lesional neocortical epilepsy
 - Low grade glioma, cavernoma, cortical dysplasia
 - Diffuse hemispheric epilepsies
 - Rasmussen's encephalitis, hemimegalencephaly, Sturge-Weber syndrome

Temporal lobe epilepsy

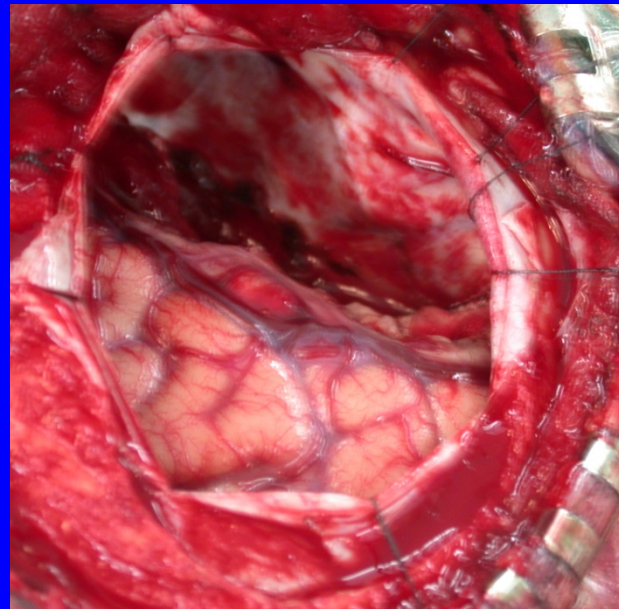
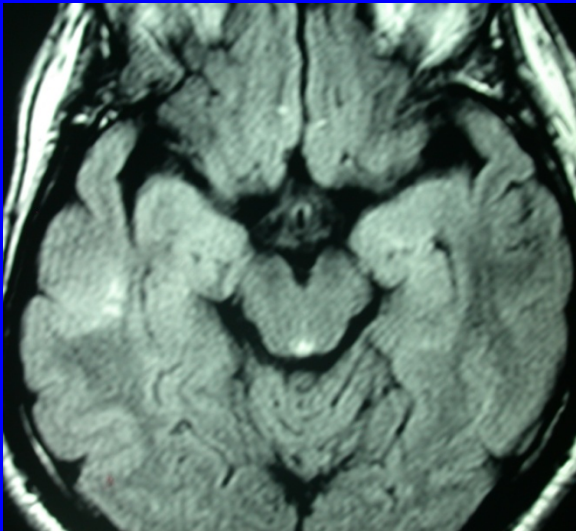
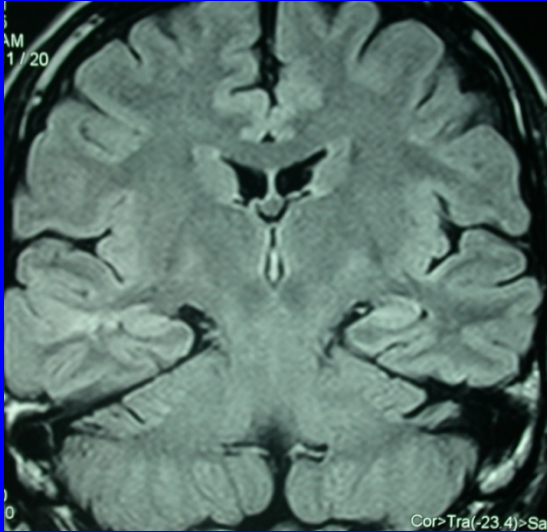
- Hippocampal sclerosis
- Tumors
 - Ganglioglioma, DNET, Glioma
- Malformative lesions
 - Cortical dysplasia
 - Vascular malformations
- Cavernoma, AVM
- Trauma
- Inflammatory/ infectious
- Non-specific lesions



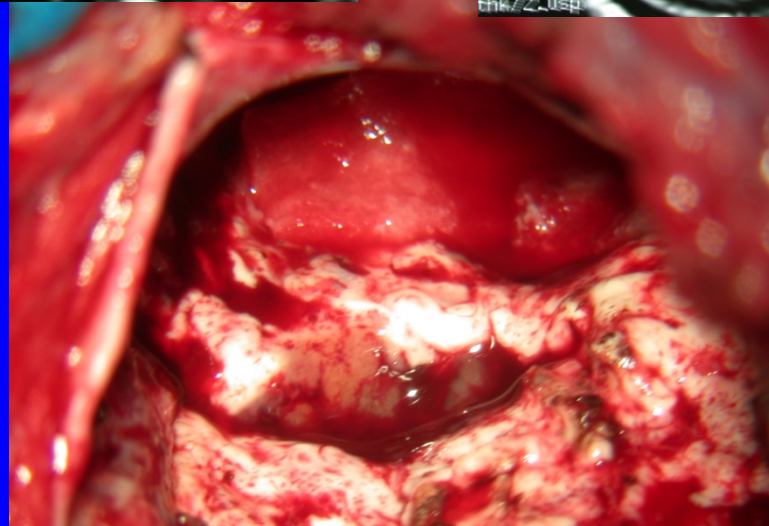
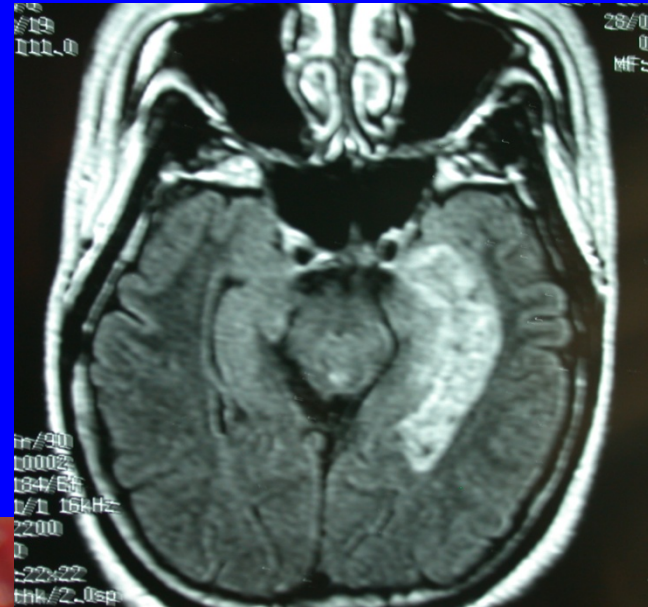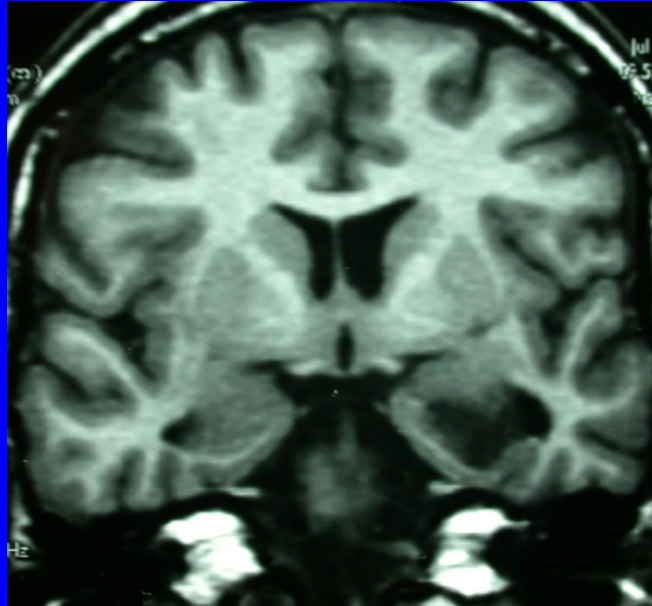
Hippocampal sclerosis



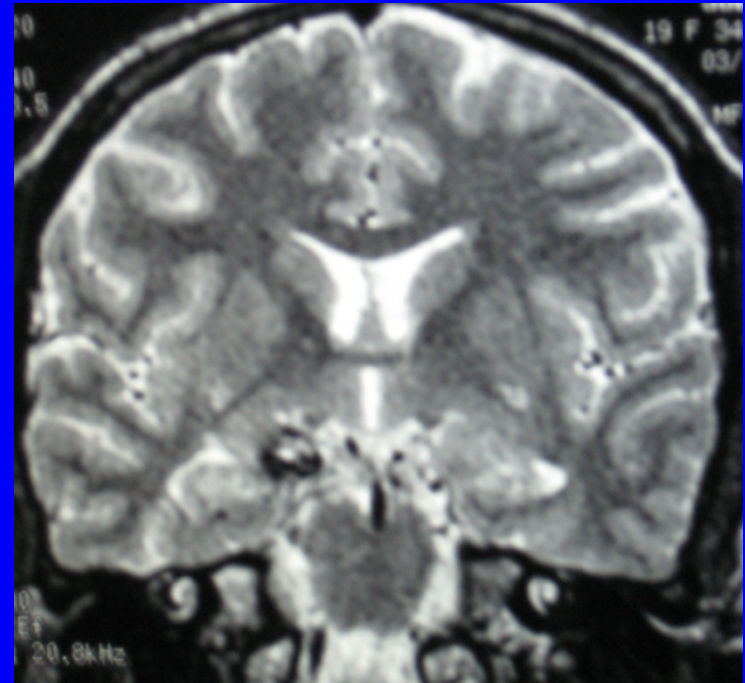
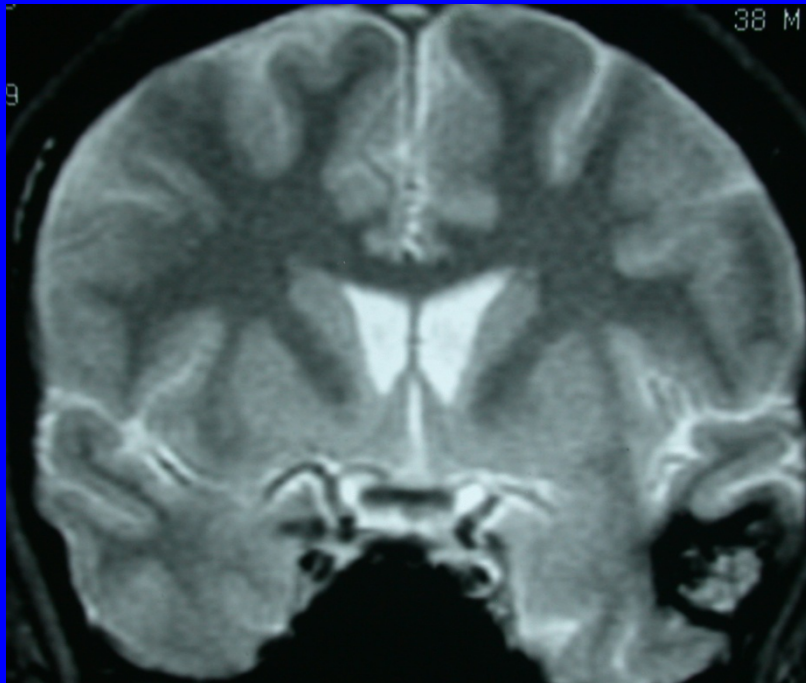
Cortical dysplasia



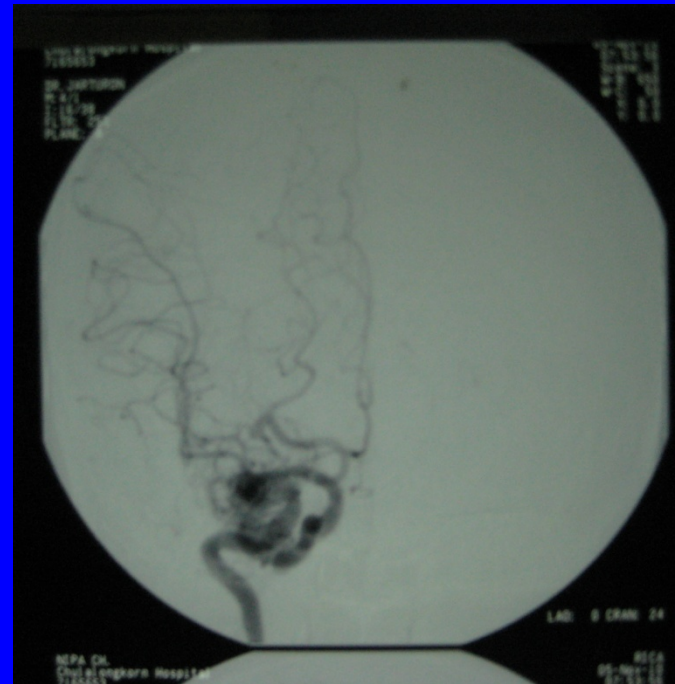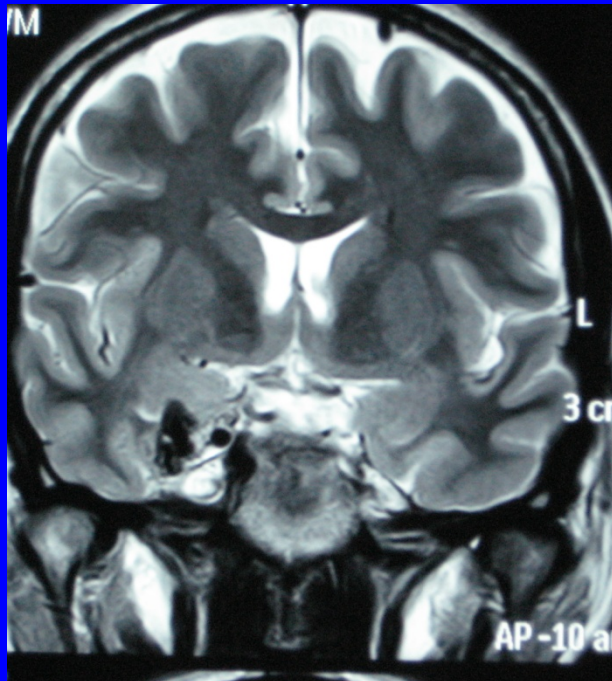
Low grade tumor



Cavernoma



AVM



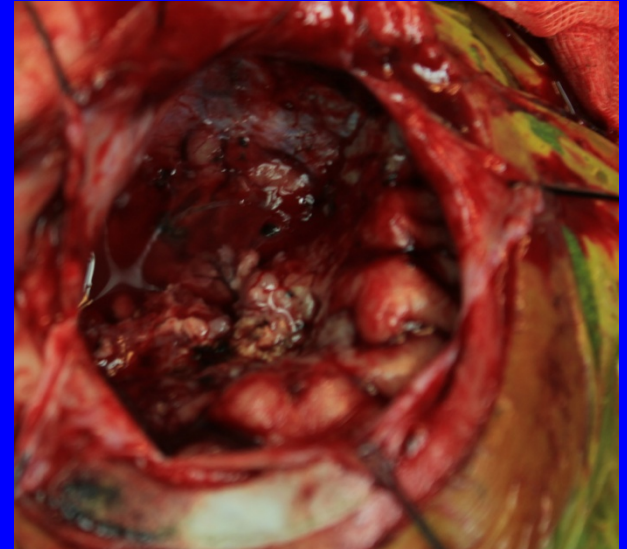
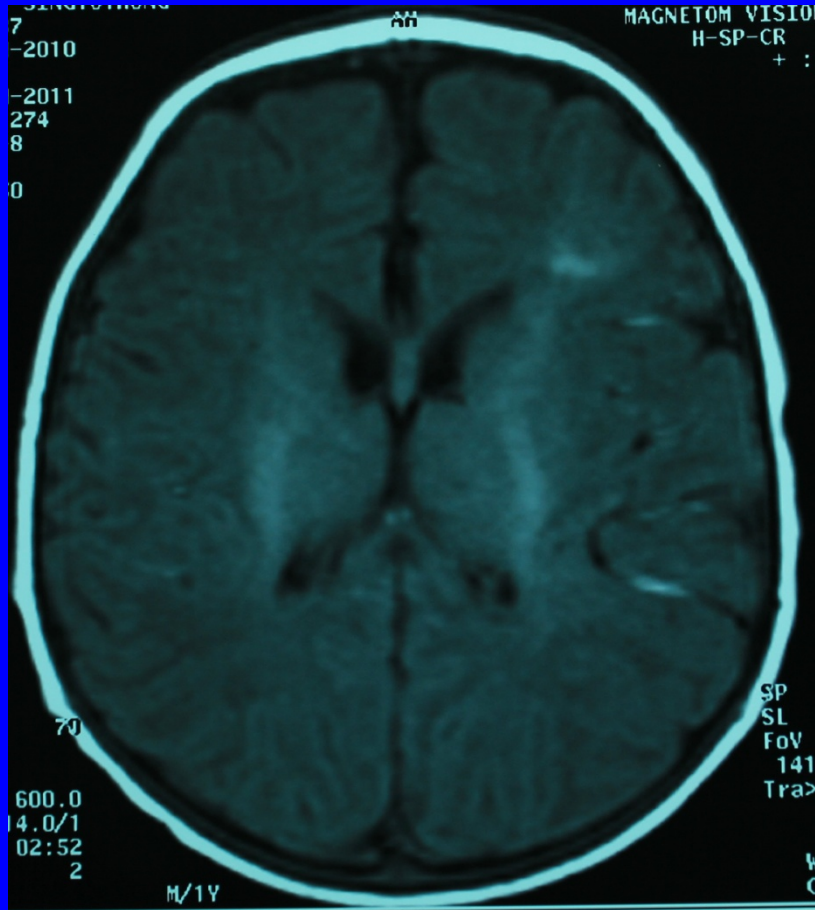
Extratemporal resection

- Frontal
- Parietal
- Occipital
- Multilobar
- Nonlesional

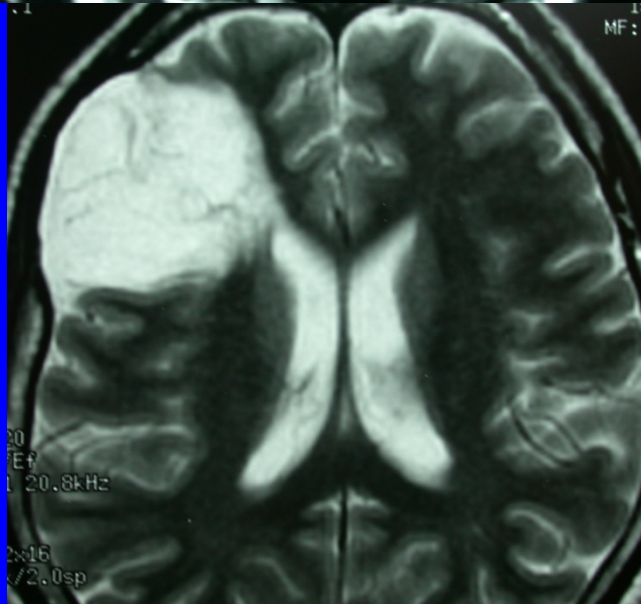
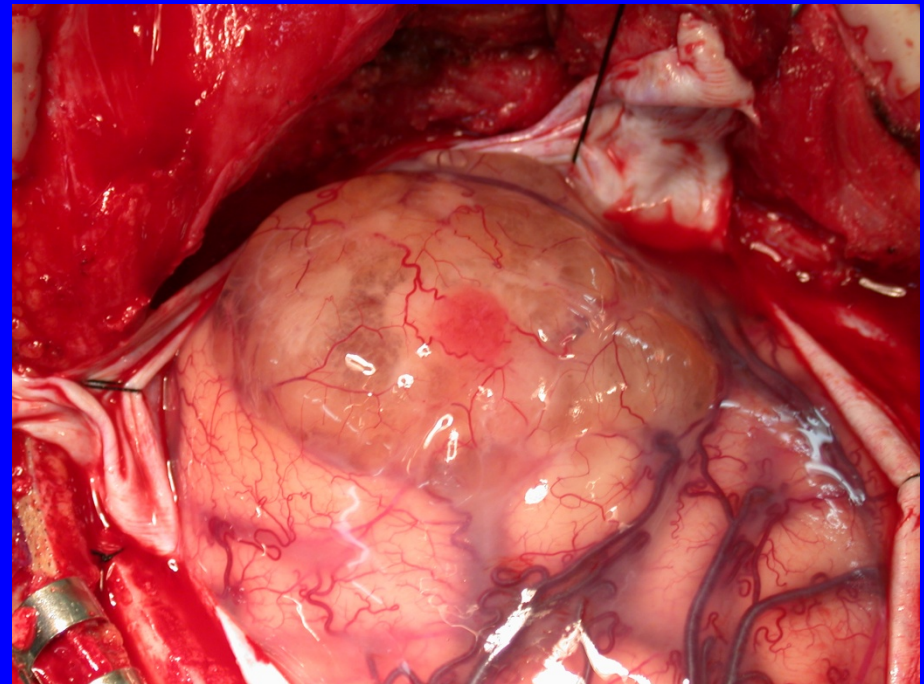
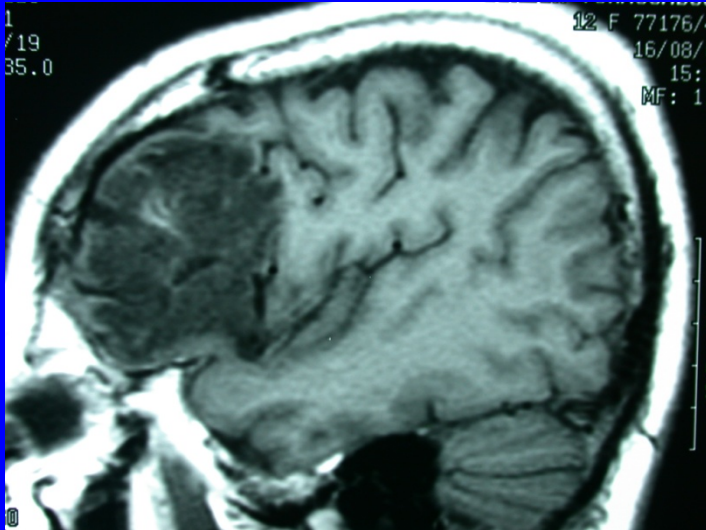
Pathologies

- Cortical dysplasia
- Tumor
- Cavernoma
- AVM
- Trauma, etc.
- Nonlesional

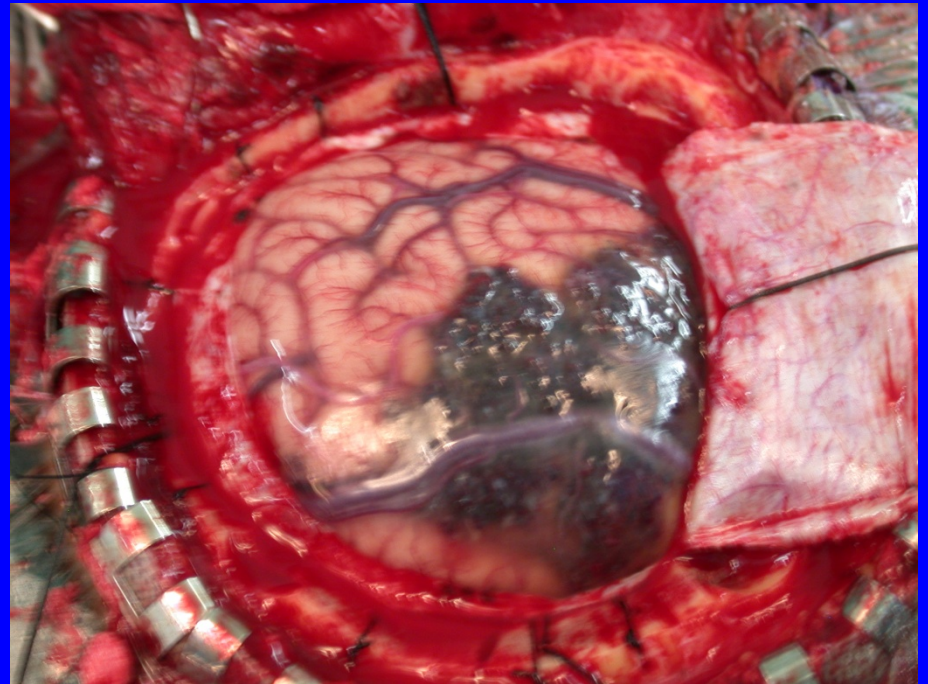
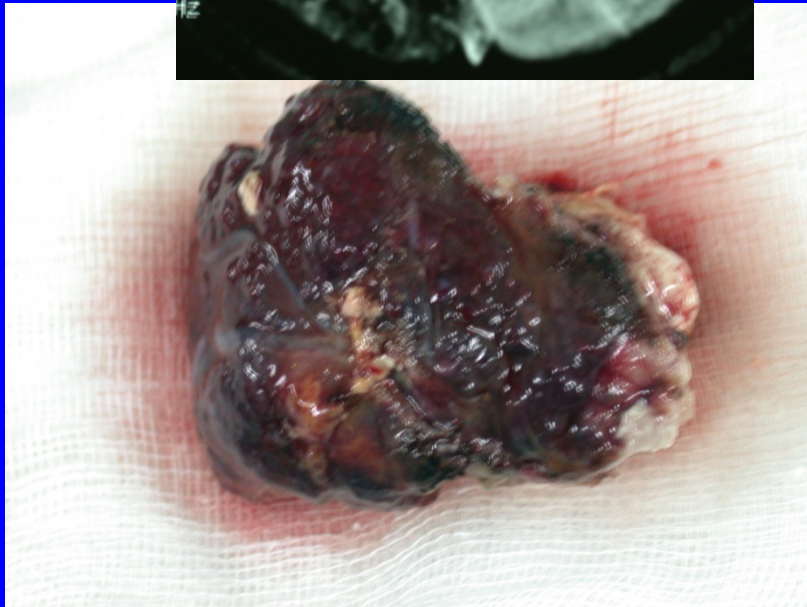
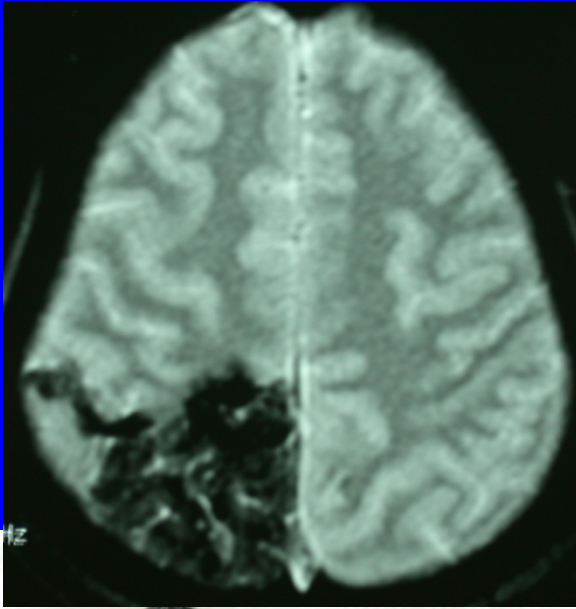
Cortical dysplasia



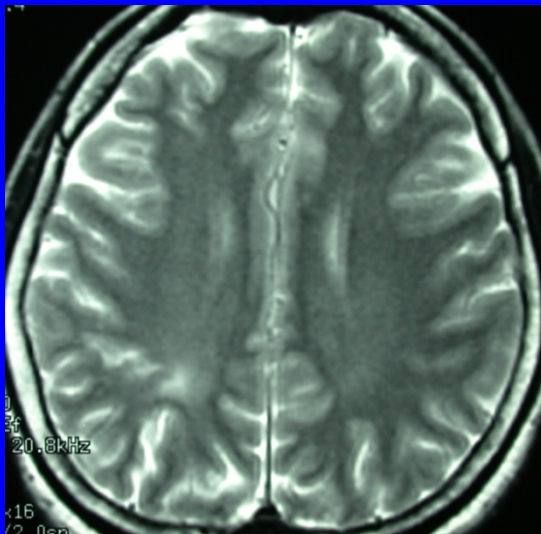
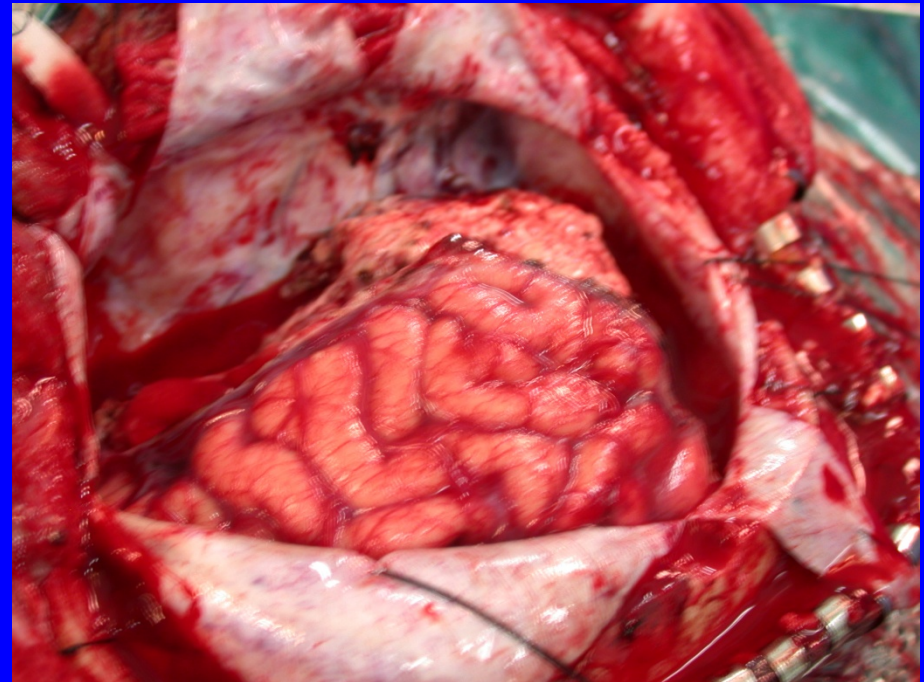
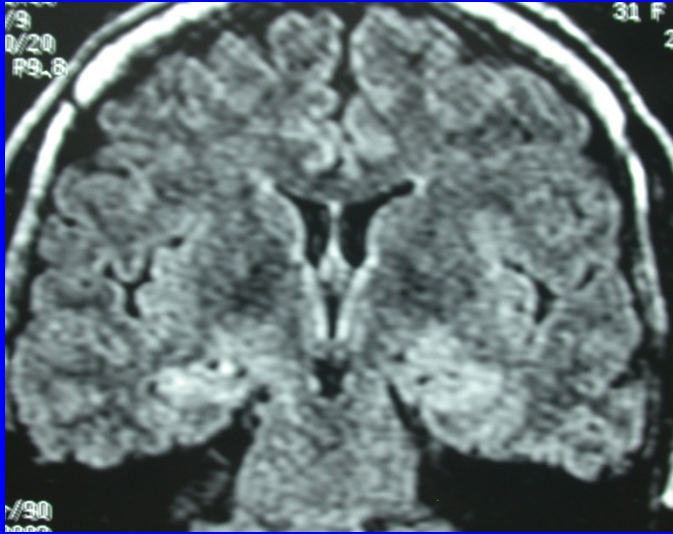
Frontal DNET



Parietal cavernoma



Multilobar resection



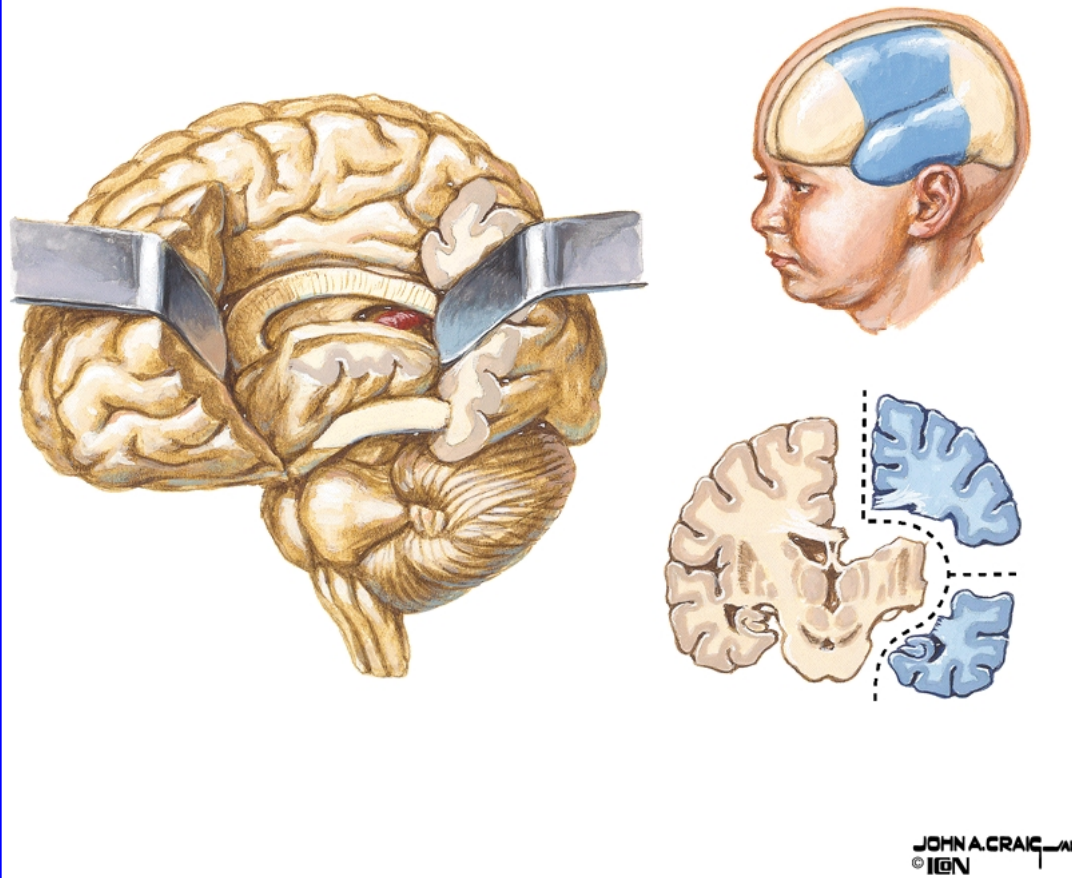
Hemispherectomy

Indications:

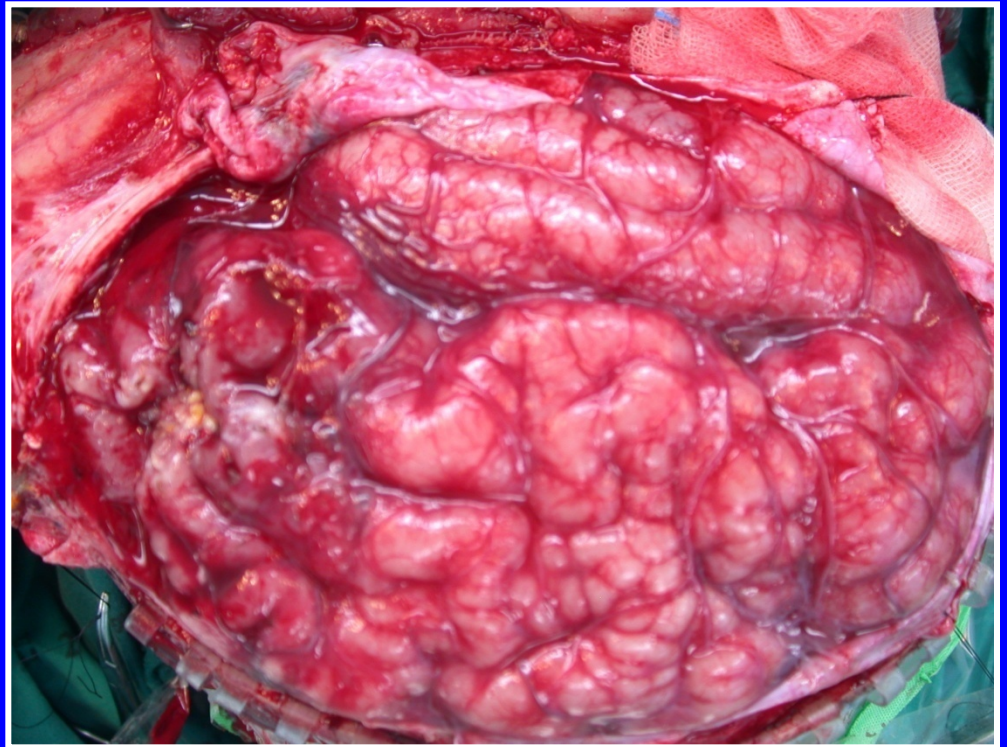
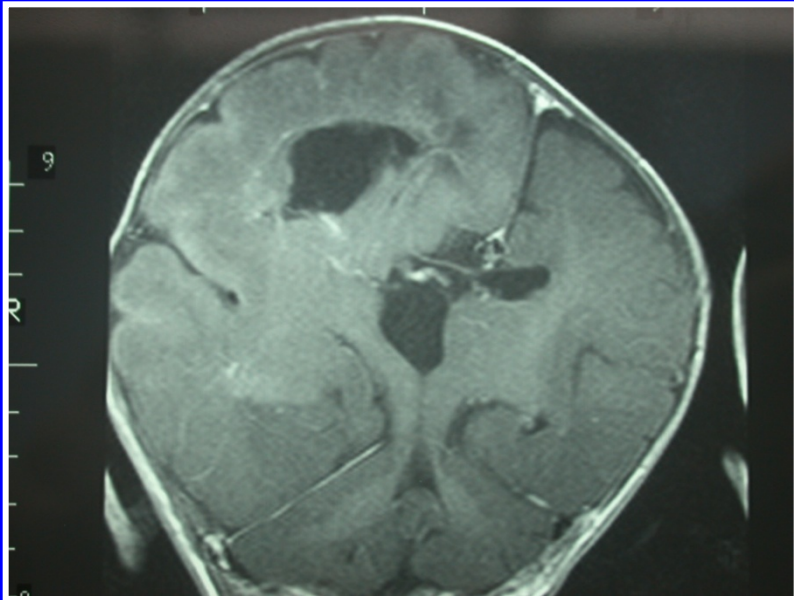
- Rasmussen's encephalitis
- Sturge-Weber syndrome
- Hemimegalencephaly
- Infantile hemiplegic epilepsy

Hemispherectomy

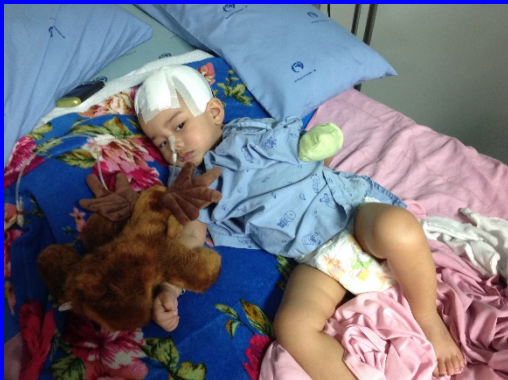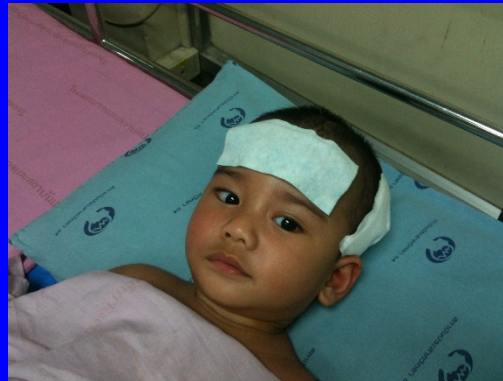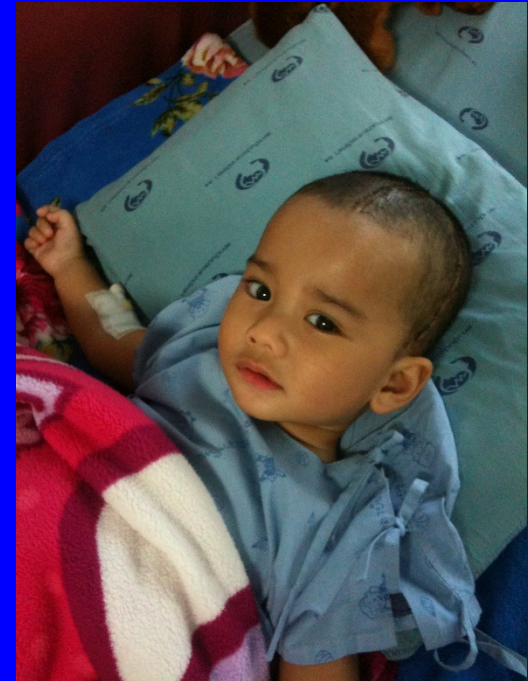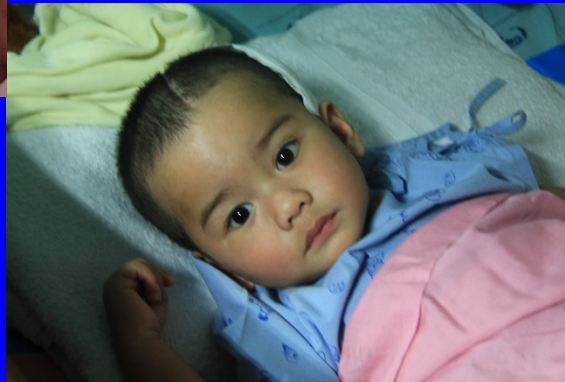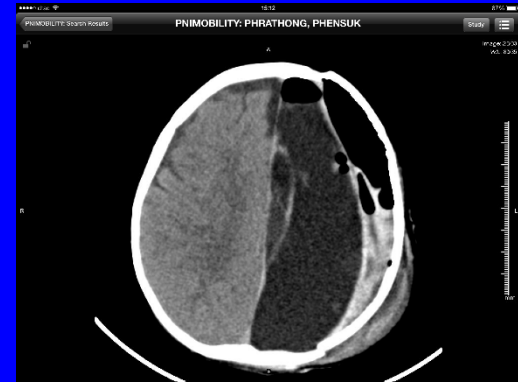
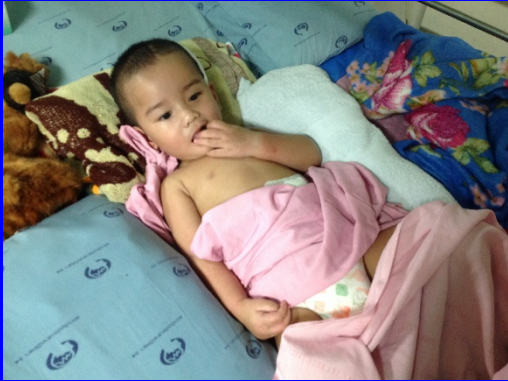Resective Surgery
Hemispherectomy

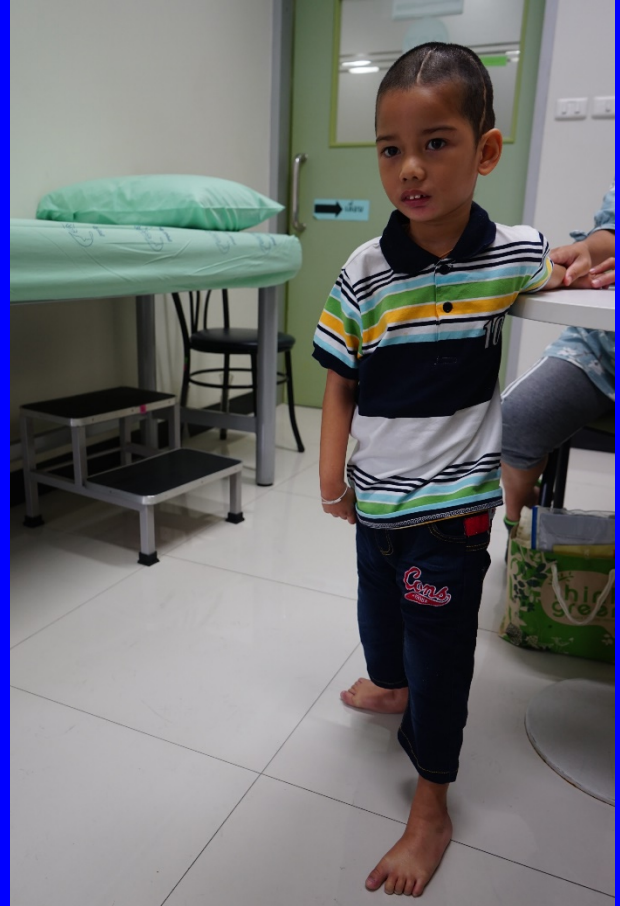
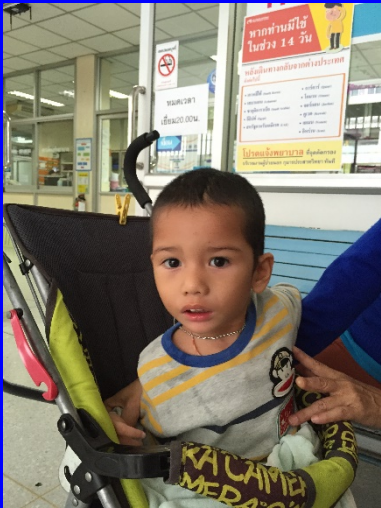
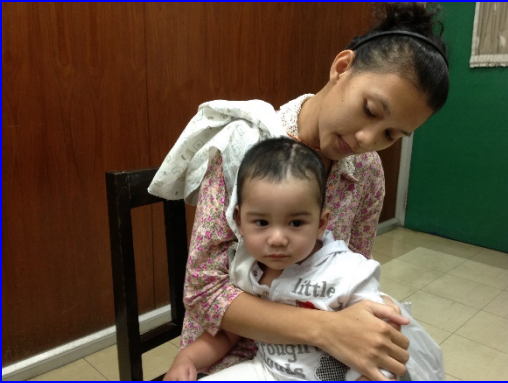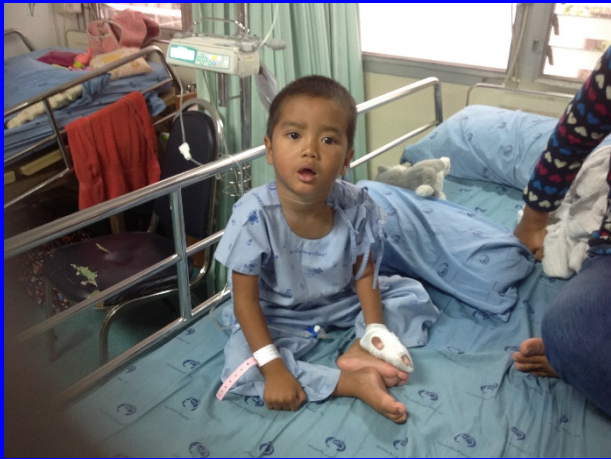Hemimegalencephaly



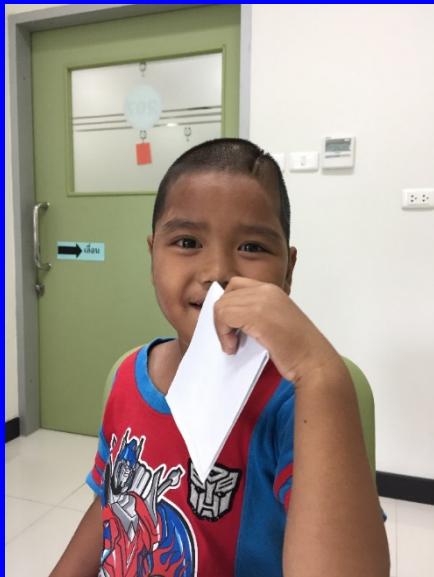
1/11/2013 Left CD







2557

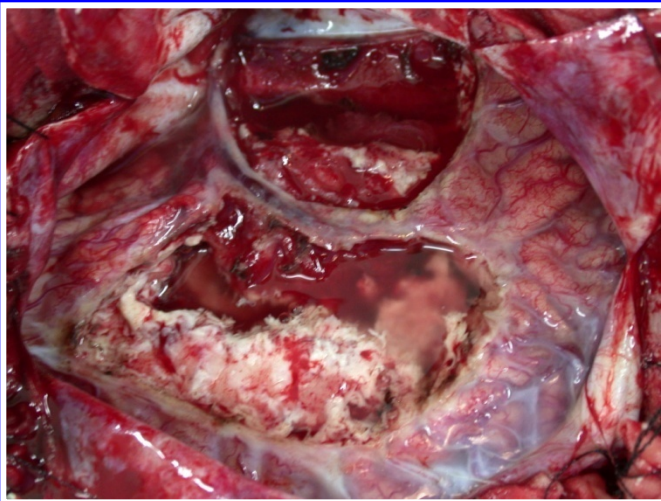
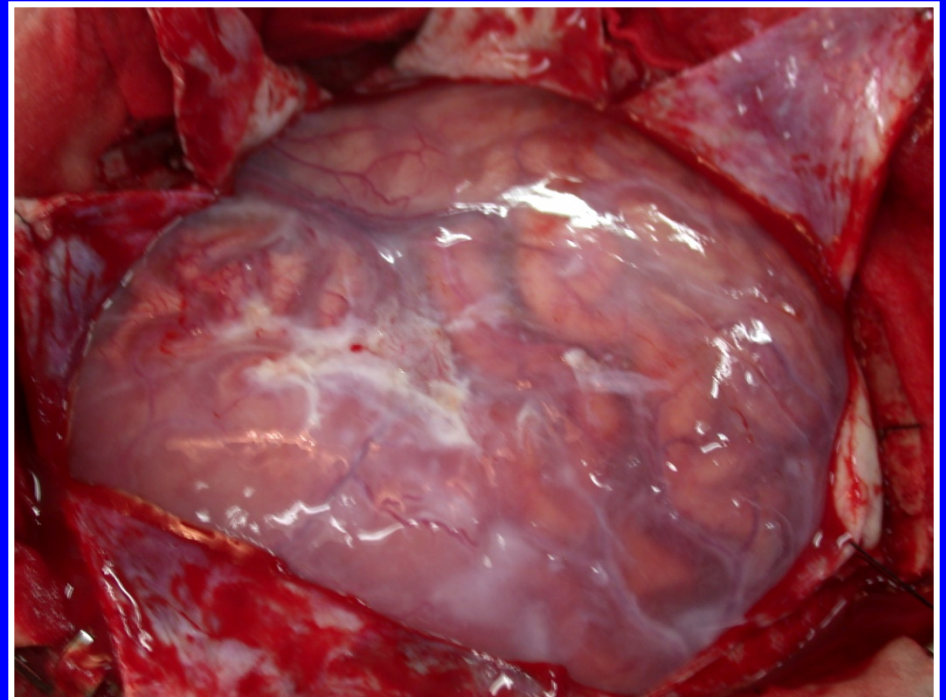
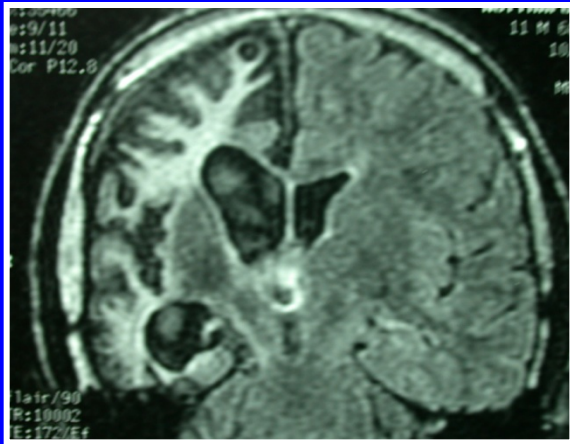


12/2559

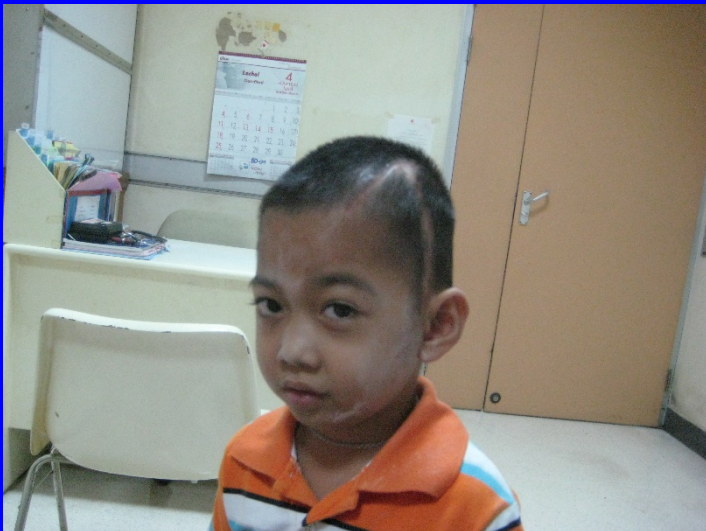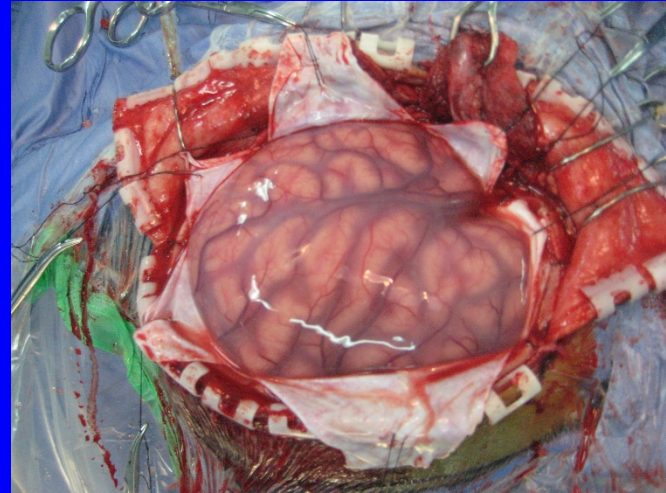
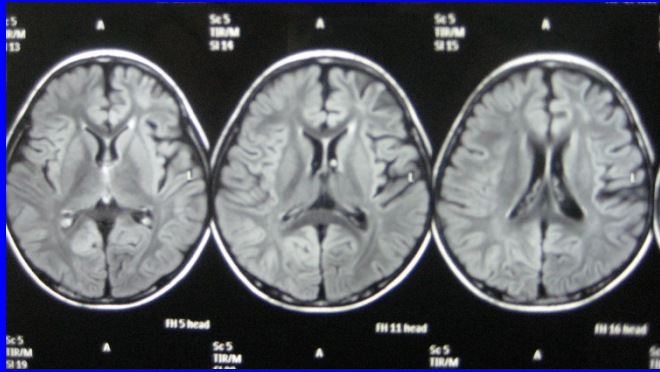


6/2560

Rasmussen's encephalitis



Rasmussen's encephalitis 3/8/2001

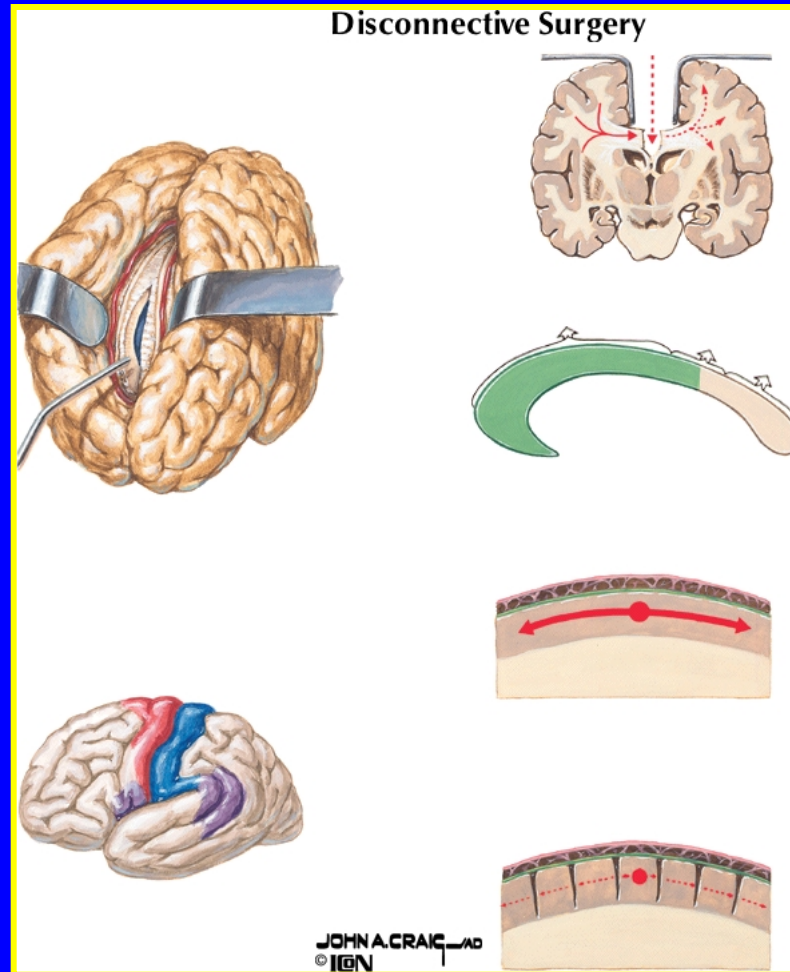


Palliative surgery

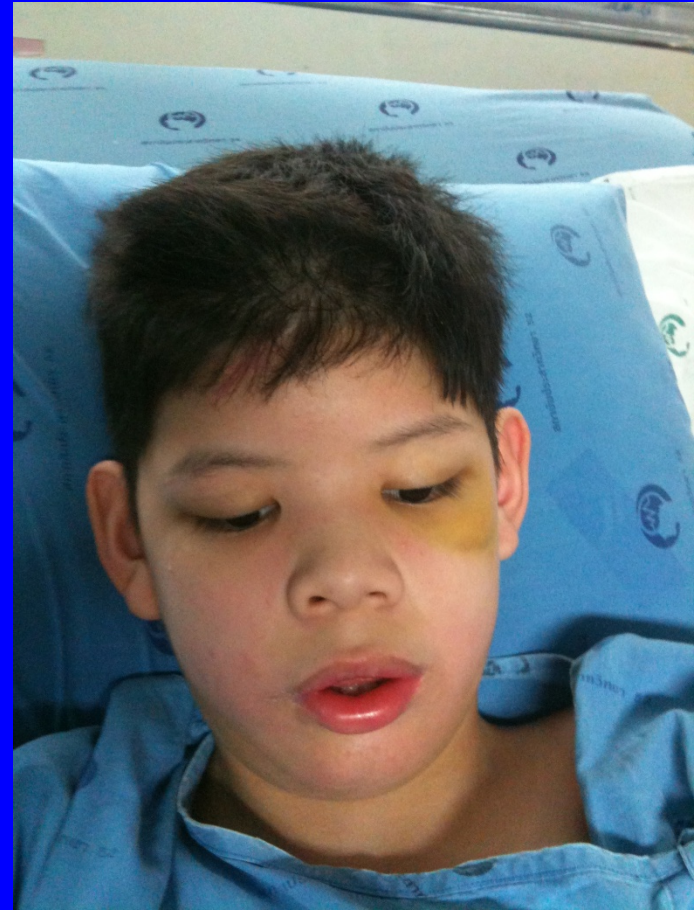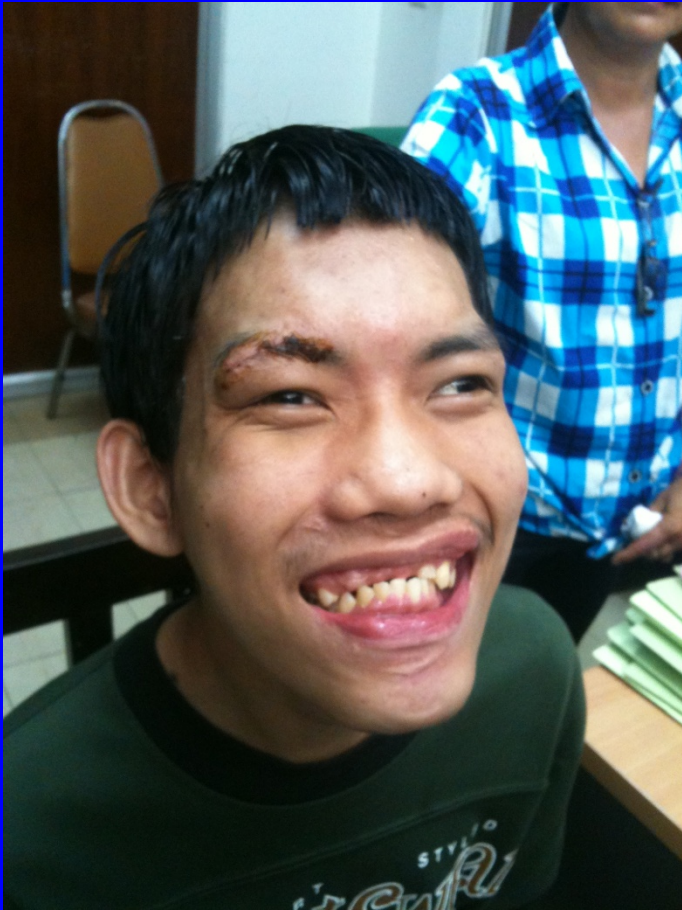Corpus callosotomy

- Cryptogenic or symptomatic generalized epilepsy (“Drop attacks, atonic seizures”)
- Lennox-Gastaut syndrome
 - Anterior 2/3 corpus callosotomy
 - Posterior 1/3 corpus callosotomy
- Disconnection syndrome

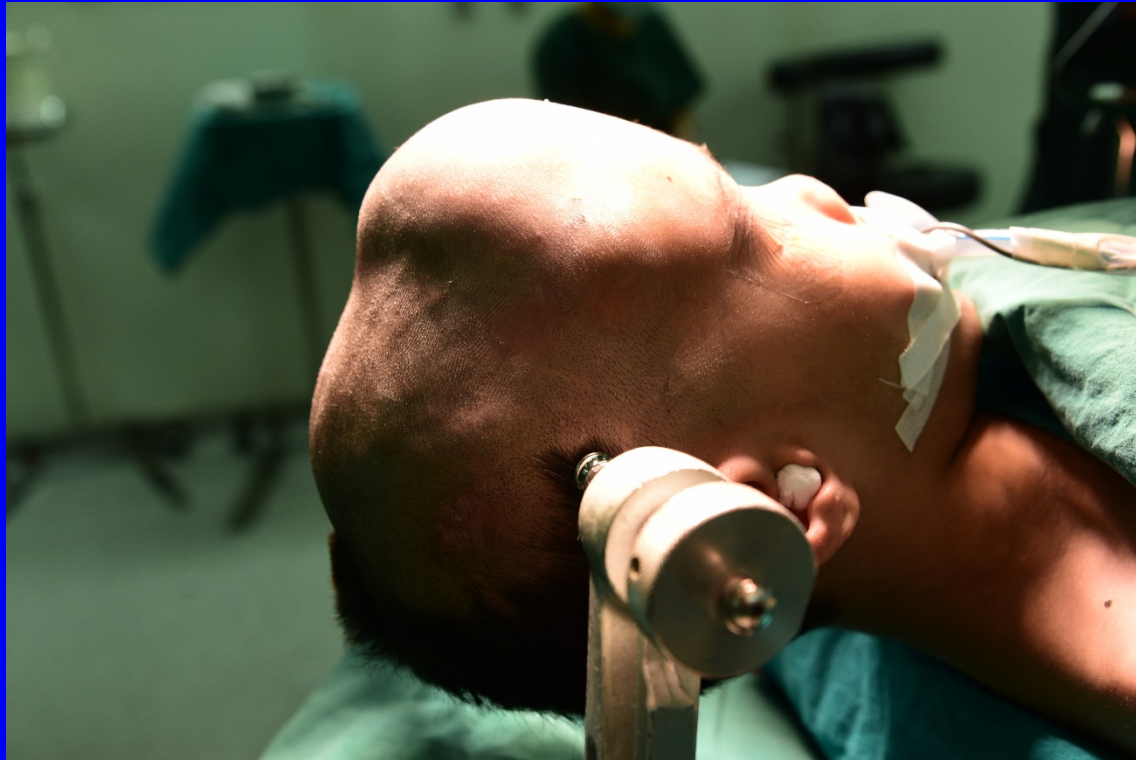Corpus callosotomy



Epileptic fall



Corpus callosotomy

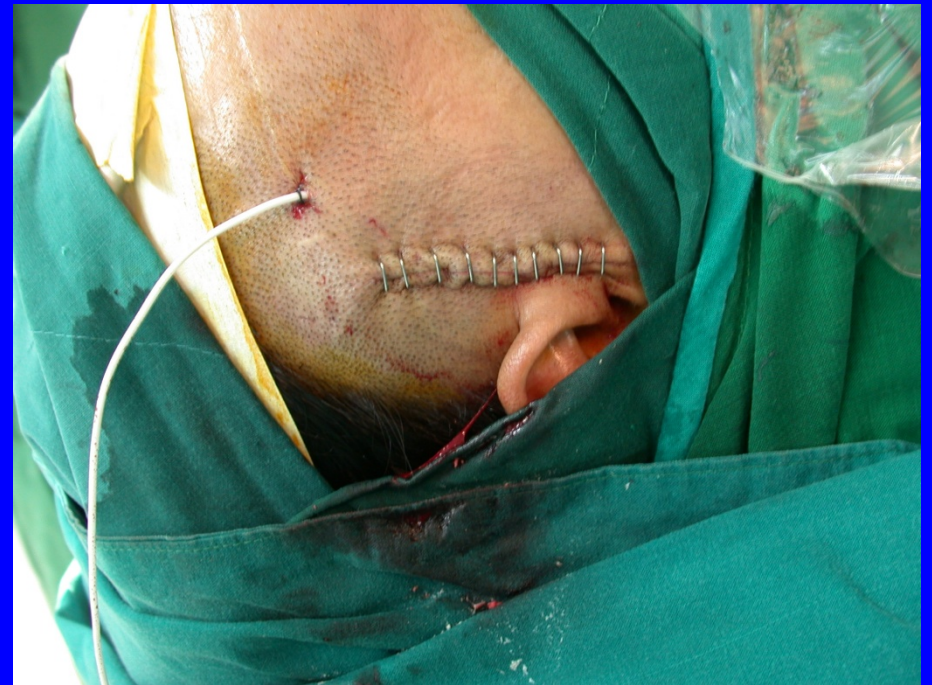


Invasive EEG

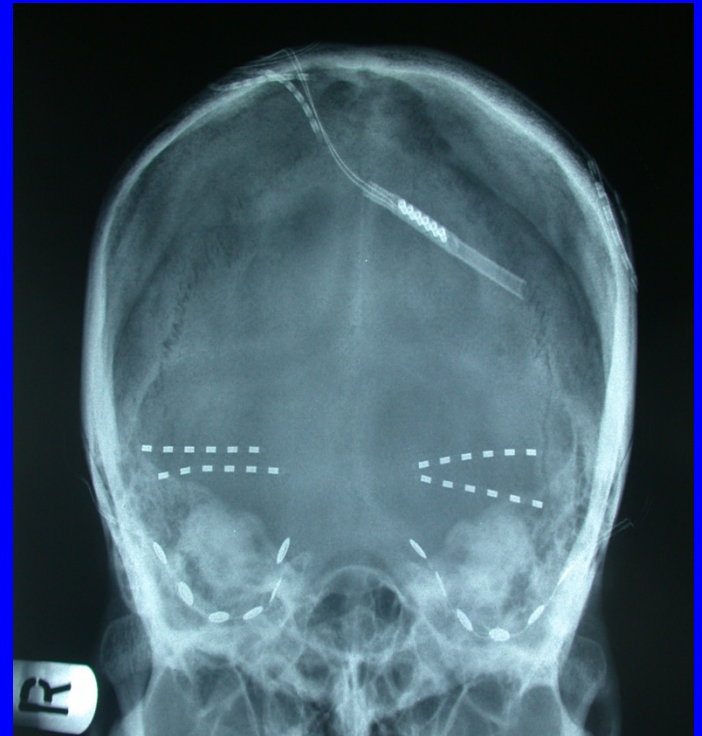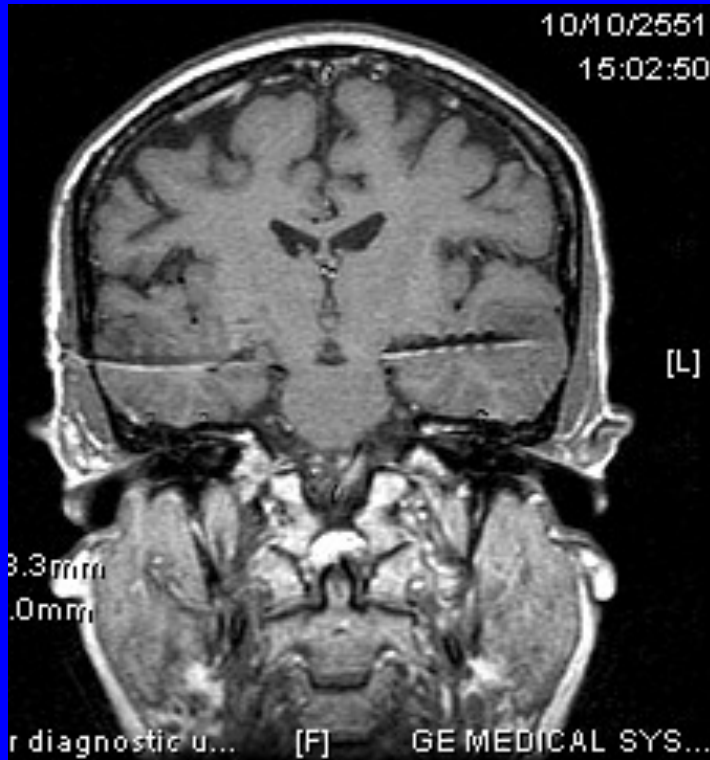

Indications

- Nonlesional
- Eloquent cortex
 - Motor/sensory
 - Speech
- Extent of resection

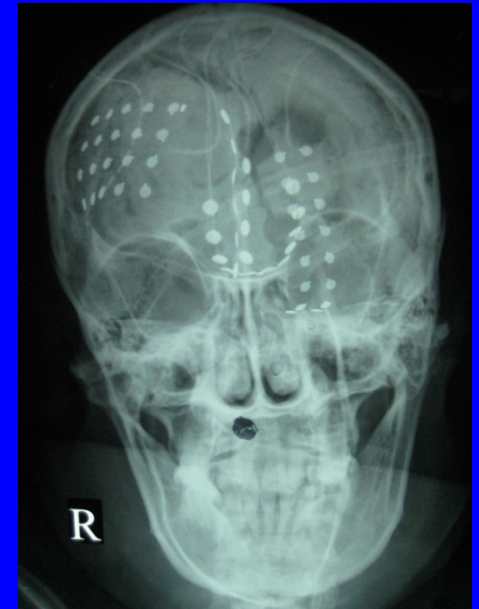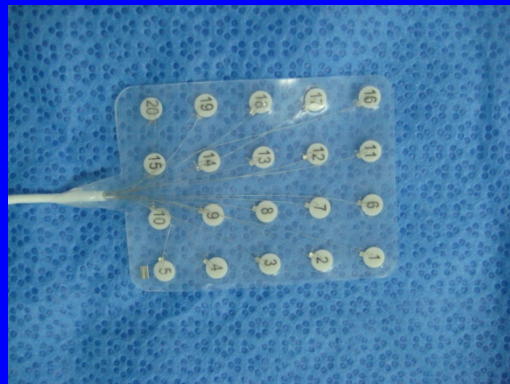
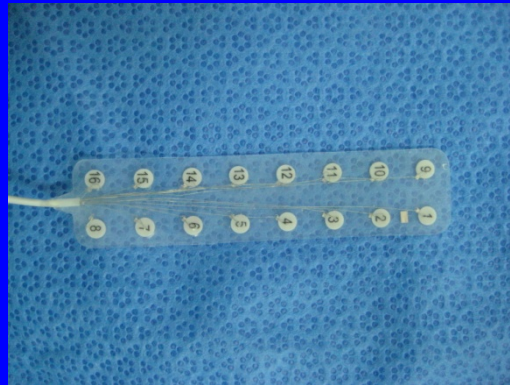
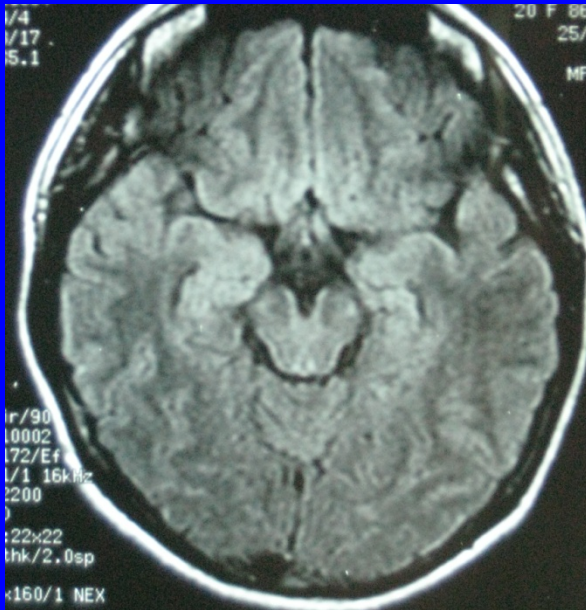
Invasive EEG (STRIP)



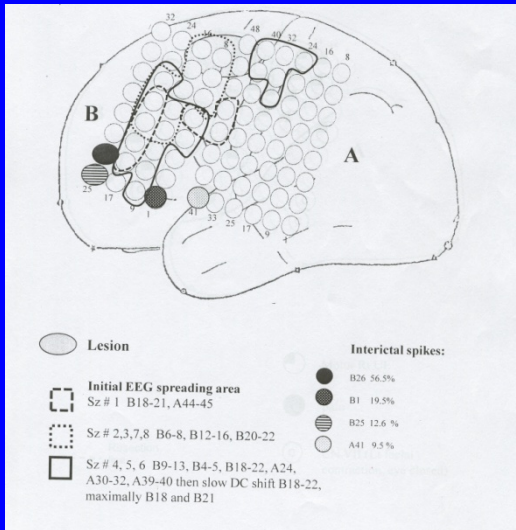
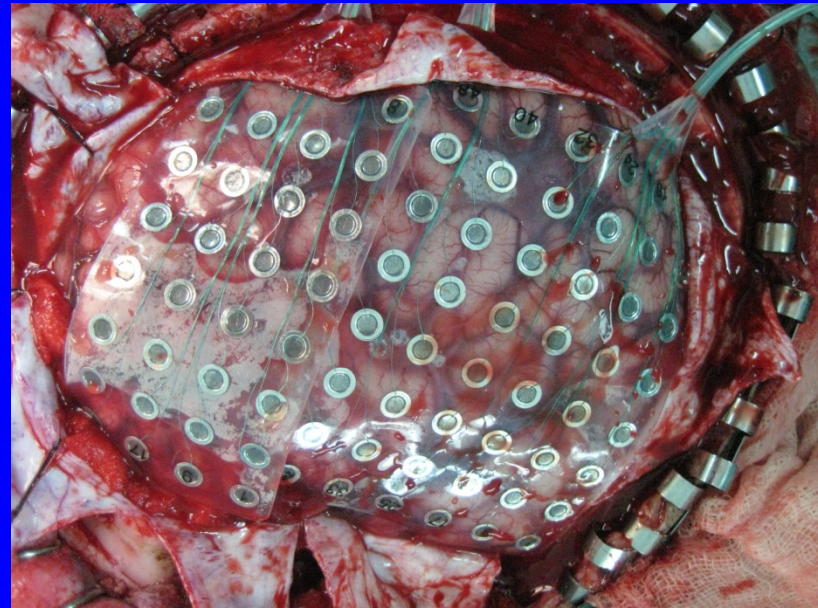
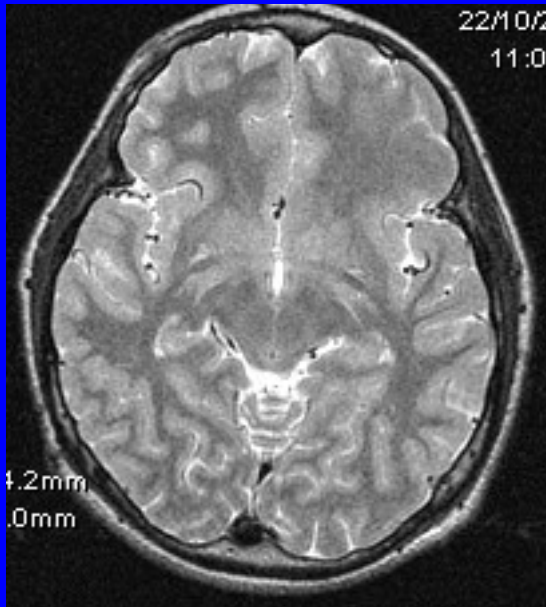
Invasive EEG (Depth)



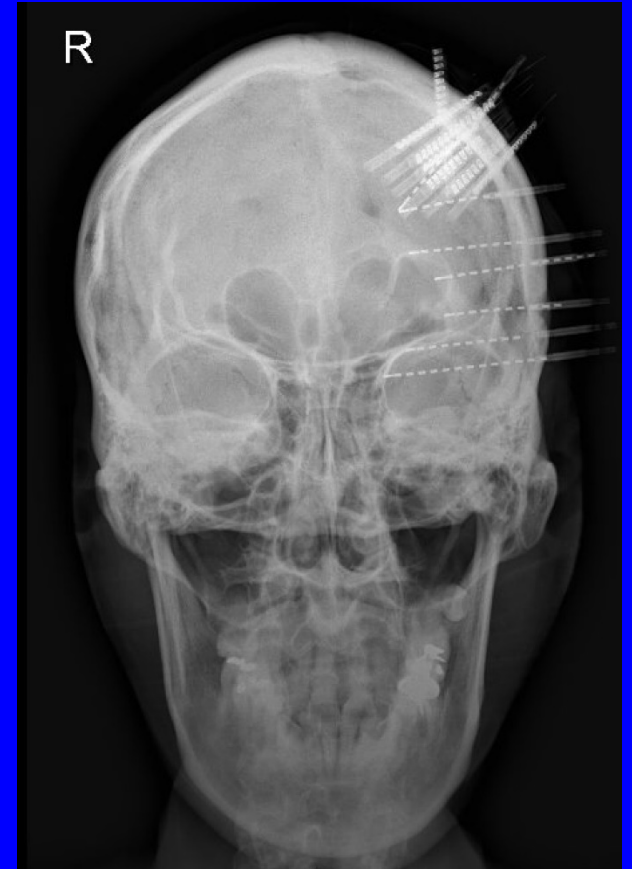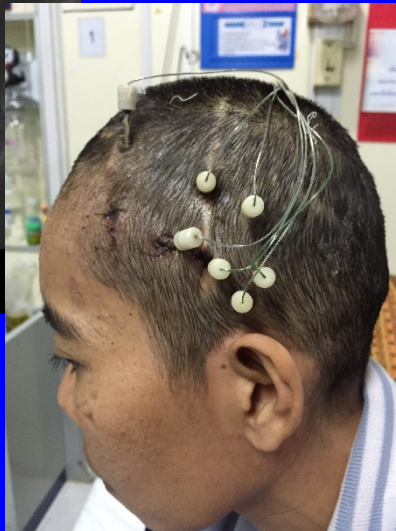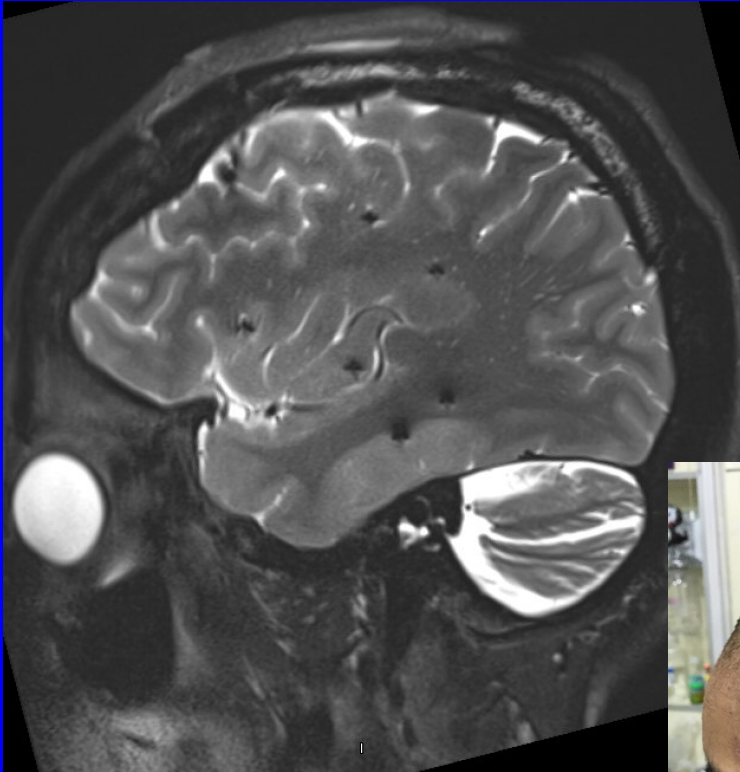
Invasive EEG (SDE)



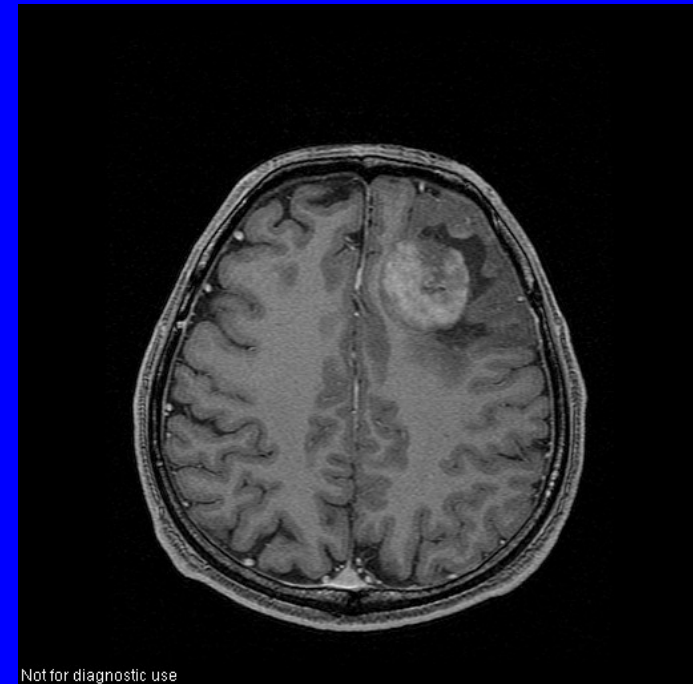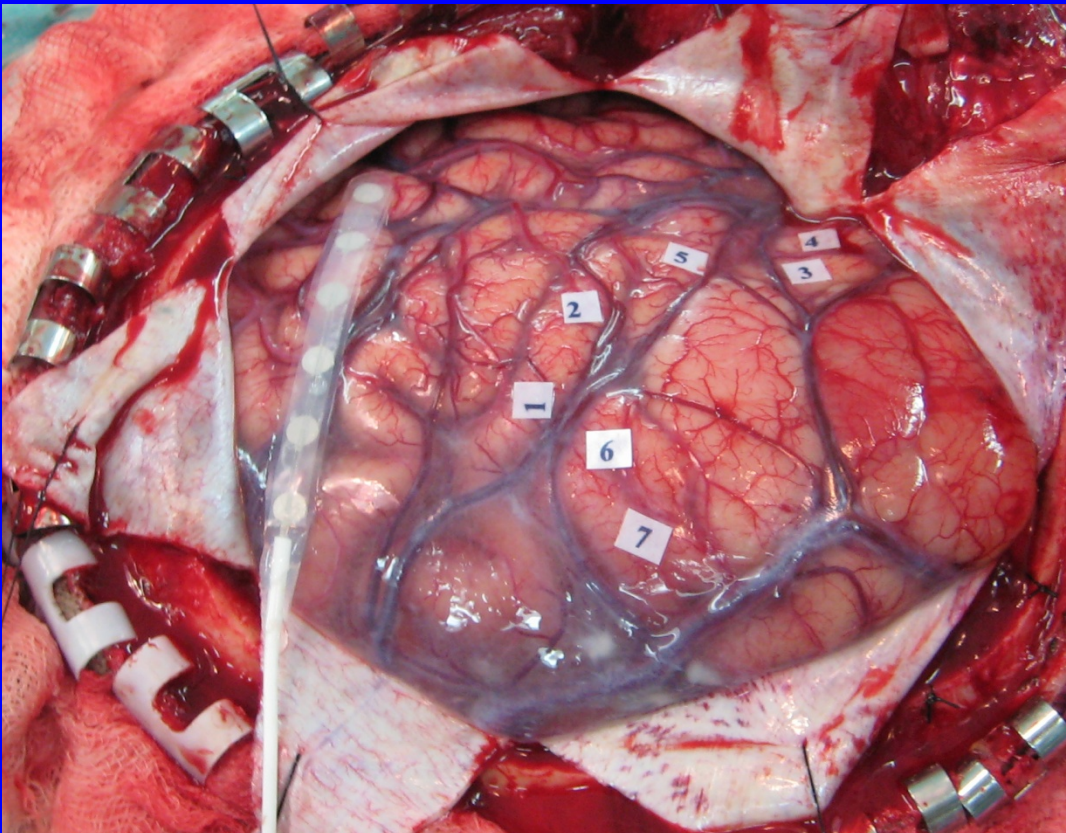
Frontal CD



SEEG



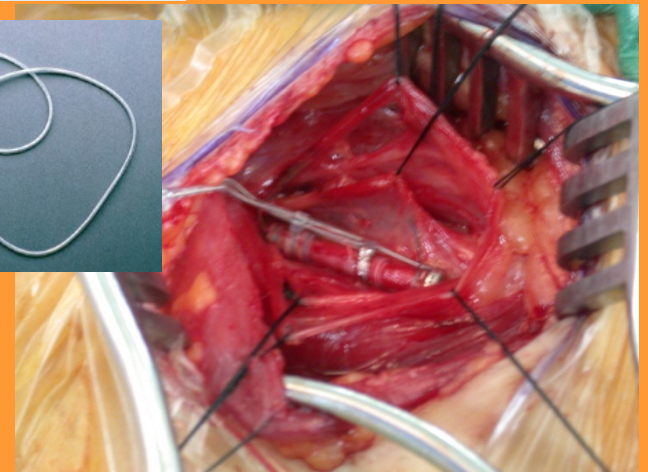
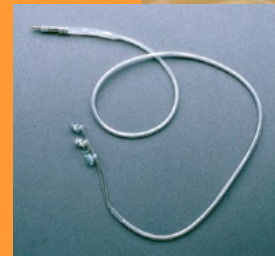Intraoperative ECoG



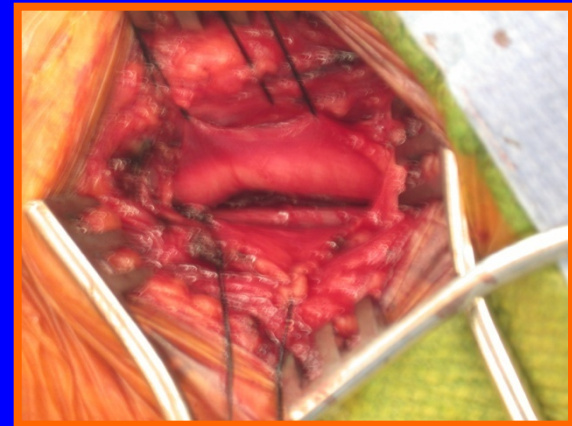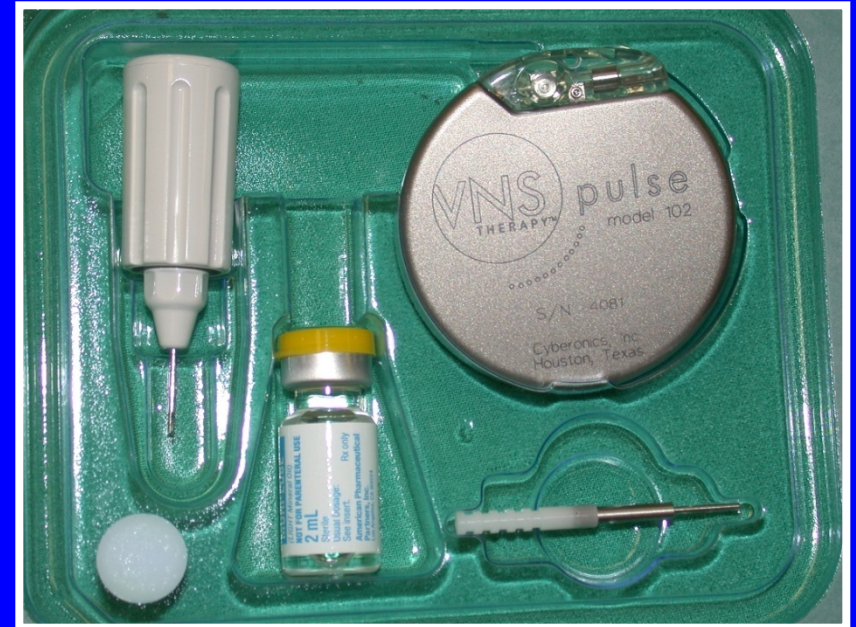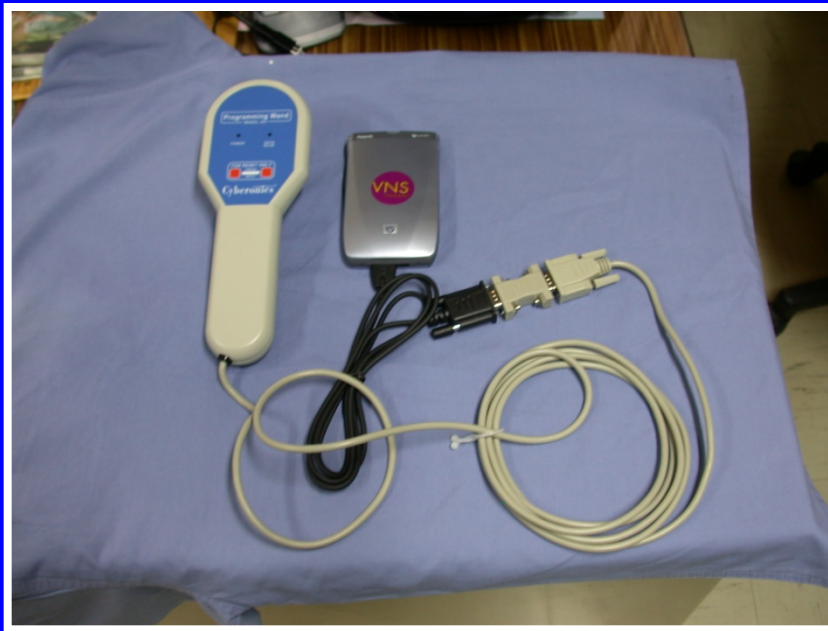Vagal nerve stimulation

Indication

- Lennox-Gastaut Syndrome
- Bitemporal lobe epilepsy
- Generalized epilepsy
- Failed epilepsy surgery



Vagal nerve stimulation



Surgery: long-term outcome

- Meta-analysis of 78 trials on resective epilepsy surgery. Median follow-up > 5 years
- Seizure-free (Engle I)
 - Temporal: n=3895 **66%**
 - Parietal: n=82 46%
 - Occipital: n=35 46%
 - Frontal: n=486 27%
 - Extratemporal: n=169 34%
 - Hemispherectomy: n=169 **61%**
 - Tumor related **76%**

Thank
you

