

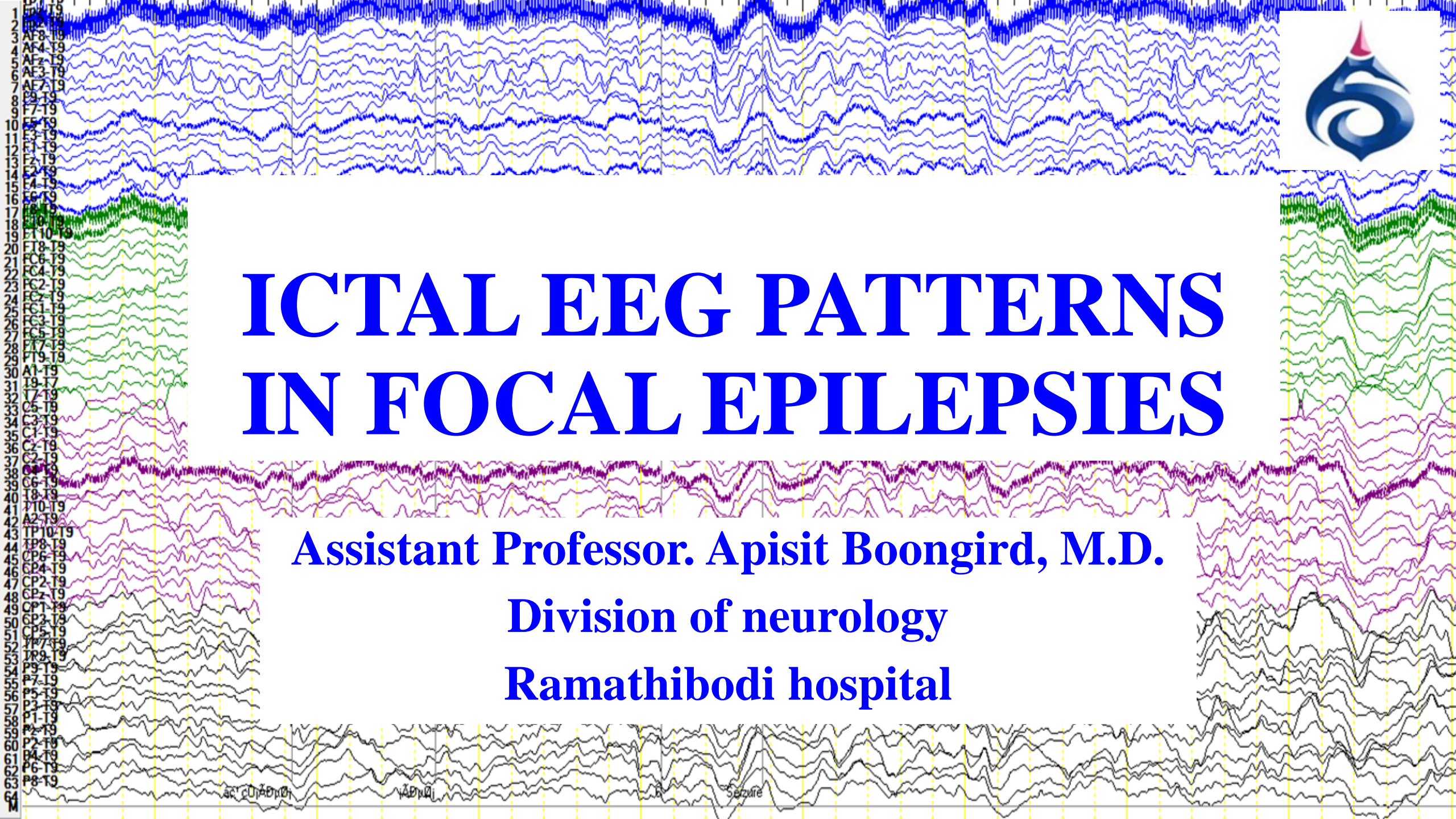


ICTAL EEG PATTERNS IN FOCAL EPILEPSIES

Assistant Professor. Apisit Boongird, M.D.

Division of neurology

Ramathibodi hospital



Outline

- Scalp-recorded ictal patterns in focal epilepsies
 - Part I: introduction to focal epilepsy
 - Part II: ictal EEG
 - Part III: workshop with EEG cases

Part I: Introduction to focal epilepsies

Definition of epileptic seizure

- a **transient** occurrence of signs and/or symptoms due to abnormal excessive or synchronous neuronal activity in the brain.

Focal seizure

- Focal epileptic seizures are conceptualized as originating within networks limited to one hemisphere. They may be discretely localized or more widely distributed. Focal seizures may originate in subcortical structures.

Operational (practical) clinical definition of epilepsy

- Epilepsy is a disease of the brain defined by any of the following conditions
 1. At least two unprovoked (or reflex) seizures occurring > 24 h apart
 2. One unprovoked (or reflex) seizure and a probability of further seizures similar to the general recurrence risk (at least 60%) after two unprovoked seizures, occurring over the next 10 years
 3. Diagnosis of an epilepsy syndrome


Clinical manifestations of adult focal epilepsies

- History taking from the patient and caregiver
 - subjective symptoms
 - objective symptoms
- Identify seizure type
 - focal vs generalized vs unclassified

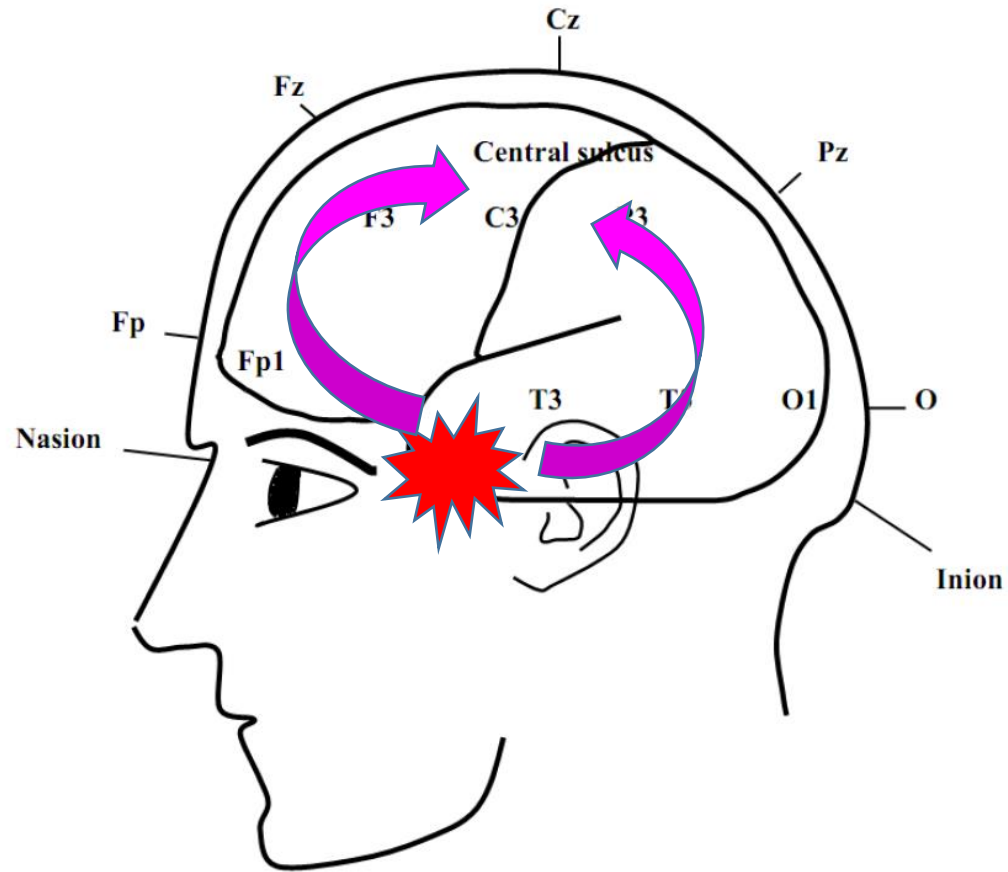
Epileptic seizures

- When did the seizure start?
- When and how did the seizure spread?
- When did the seizure stop?
- Correlation of ictal EEG and clinical findings

Clinical data



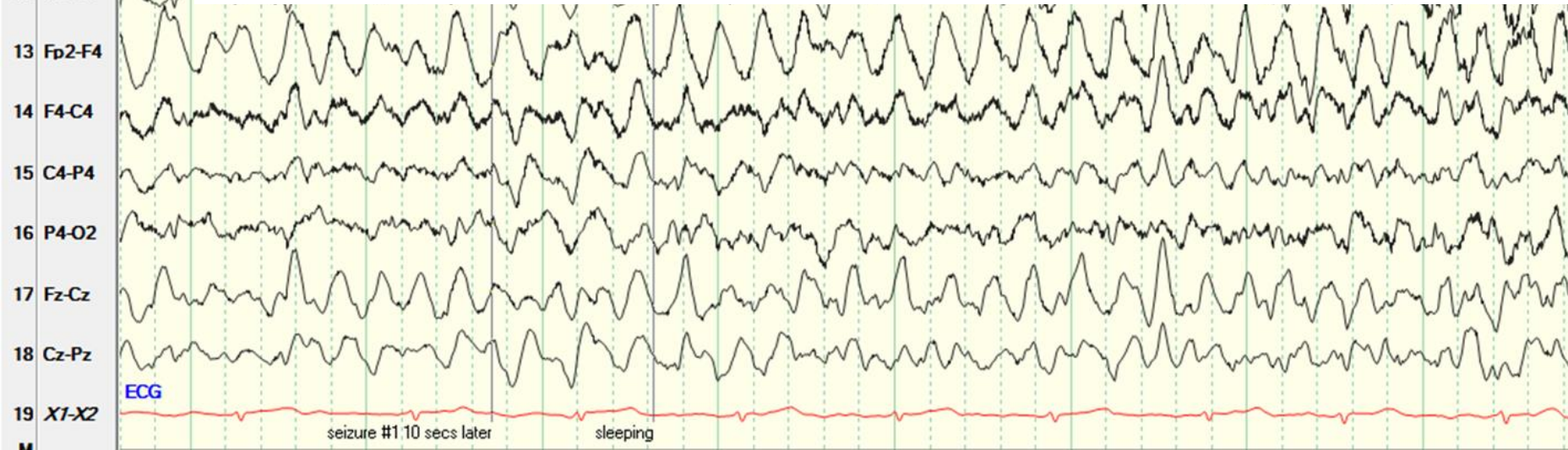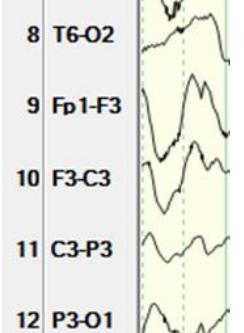
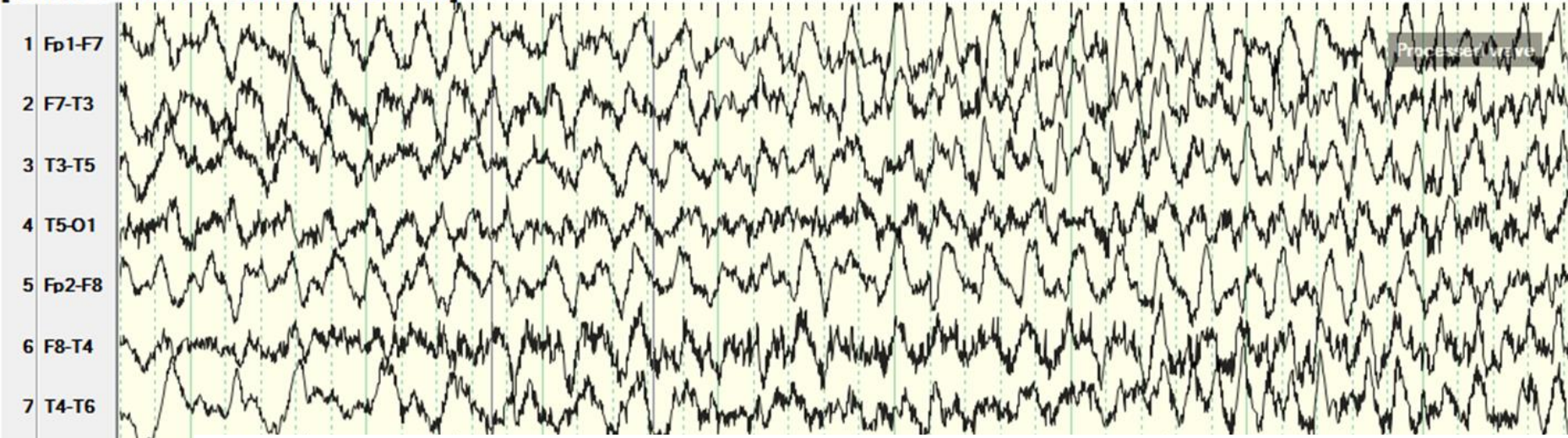
EEG data



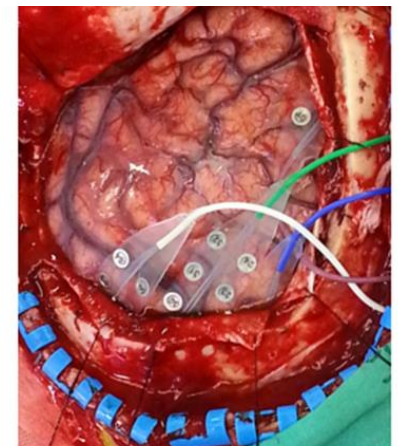
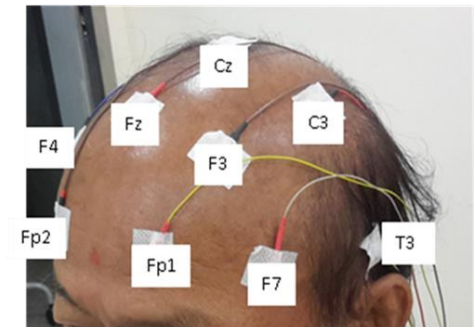
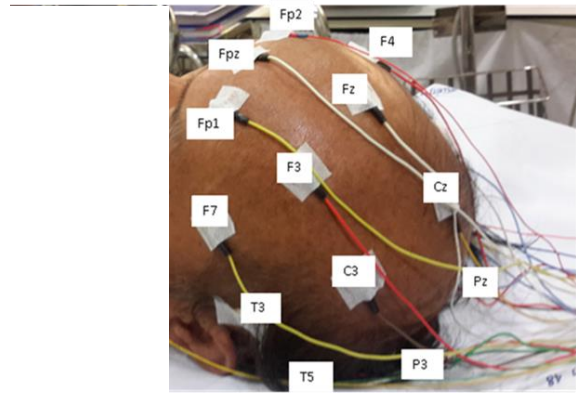
Clinical seizure

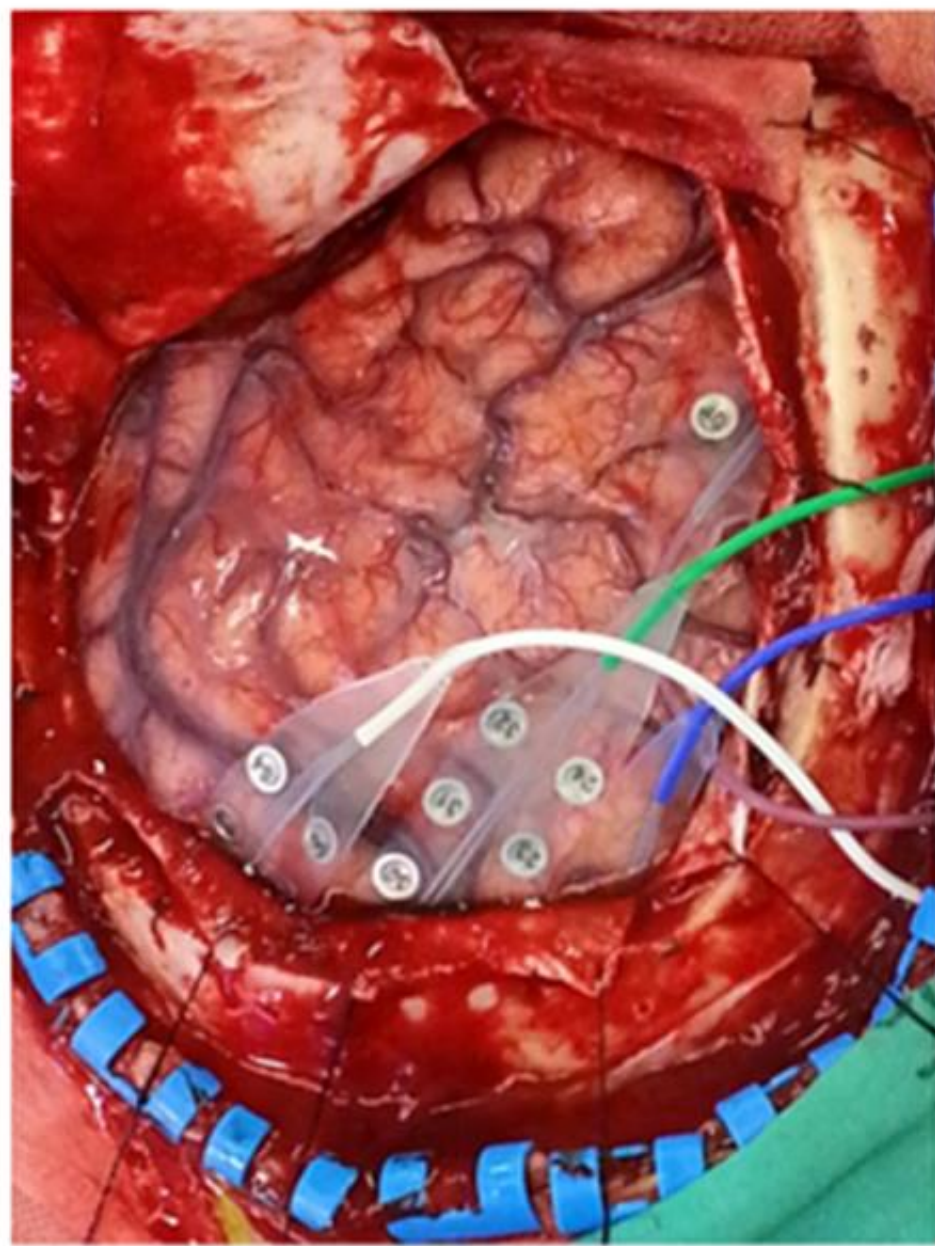
Symptom 1 → 2 → 3

[SENS 7 HF 70 LF 0.53 CAL 50]

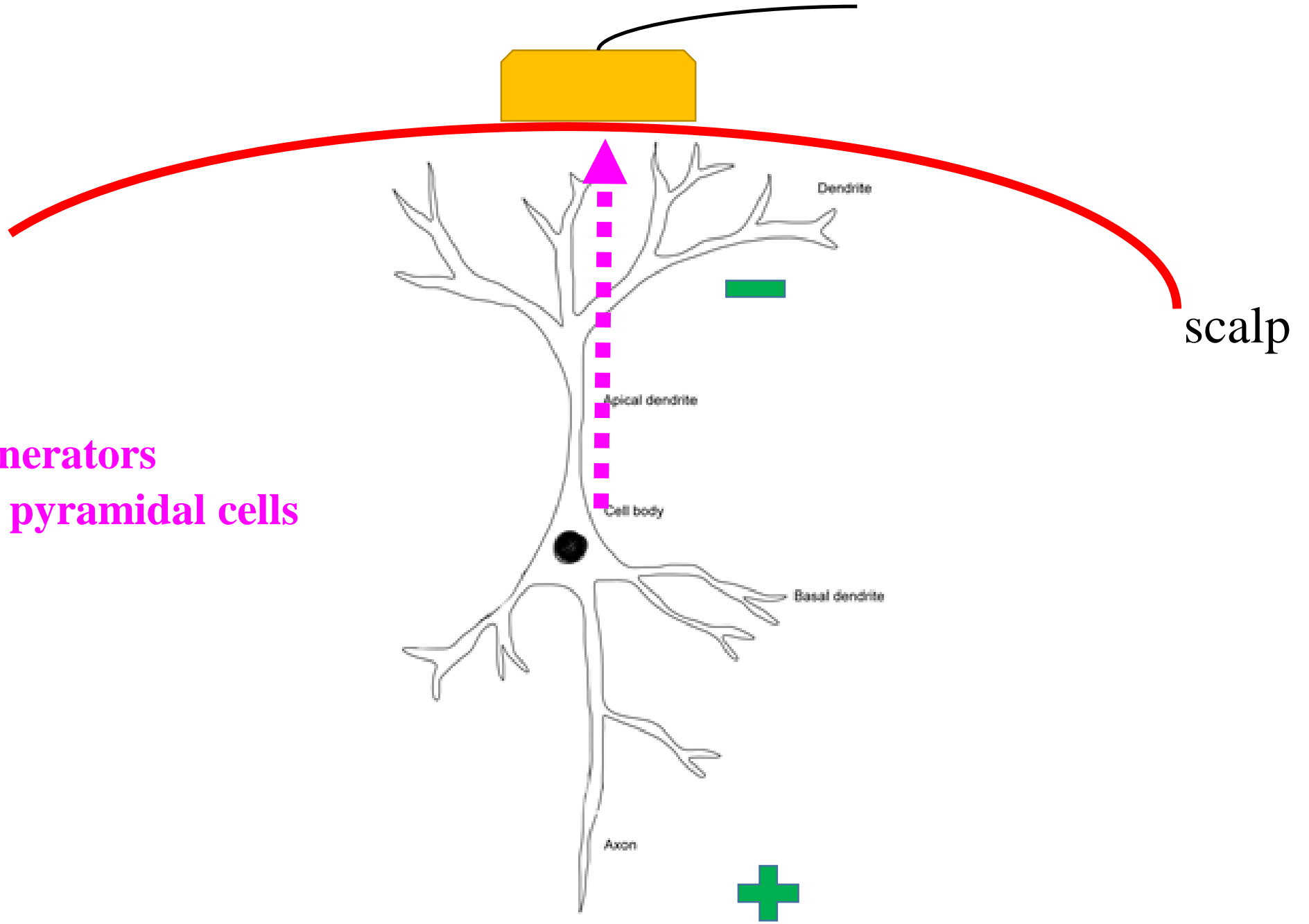


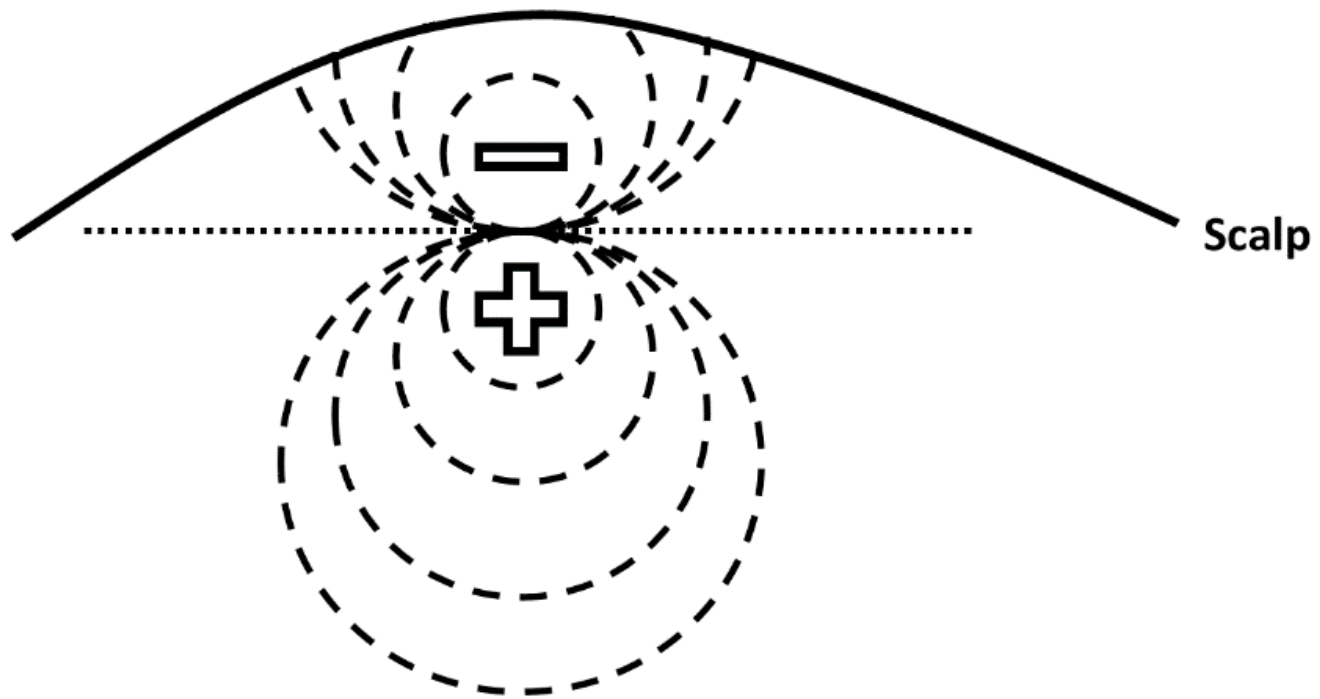
Part II: Ictal EEG



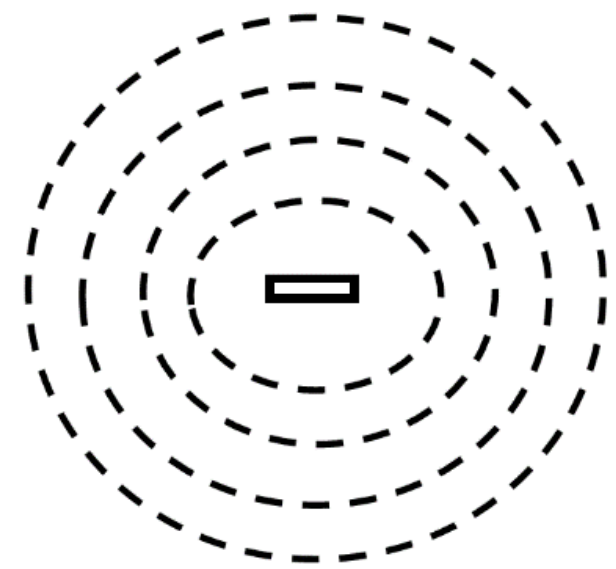


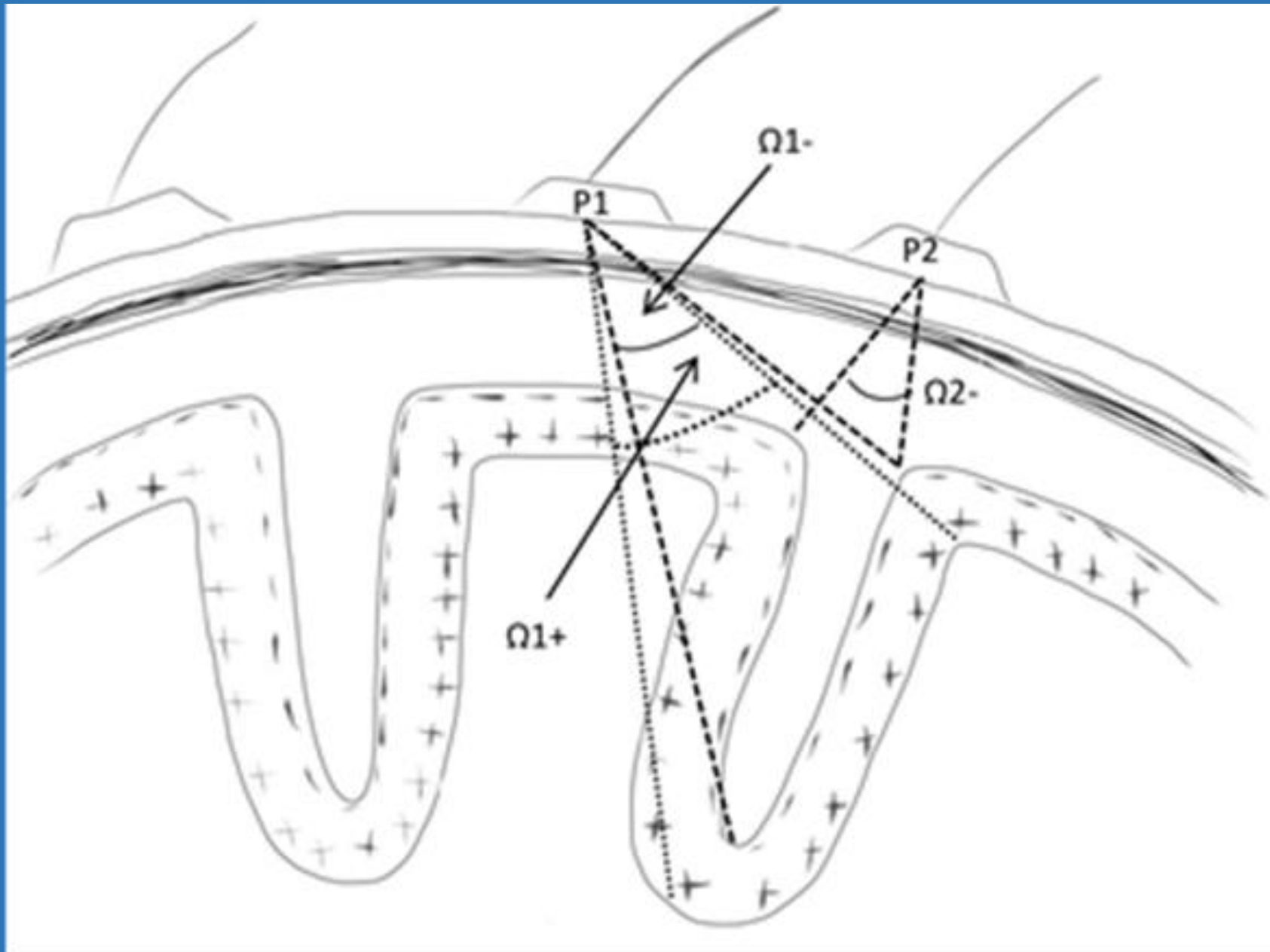
EEG generators
- pyramidal cells





View from surface



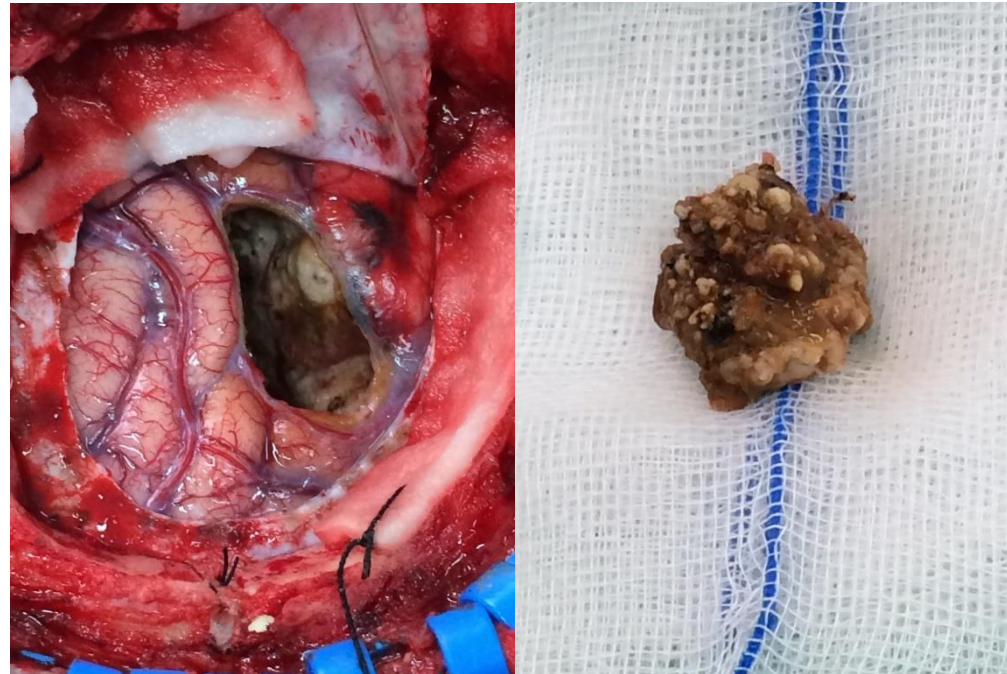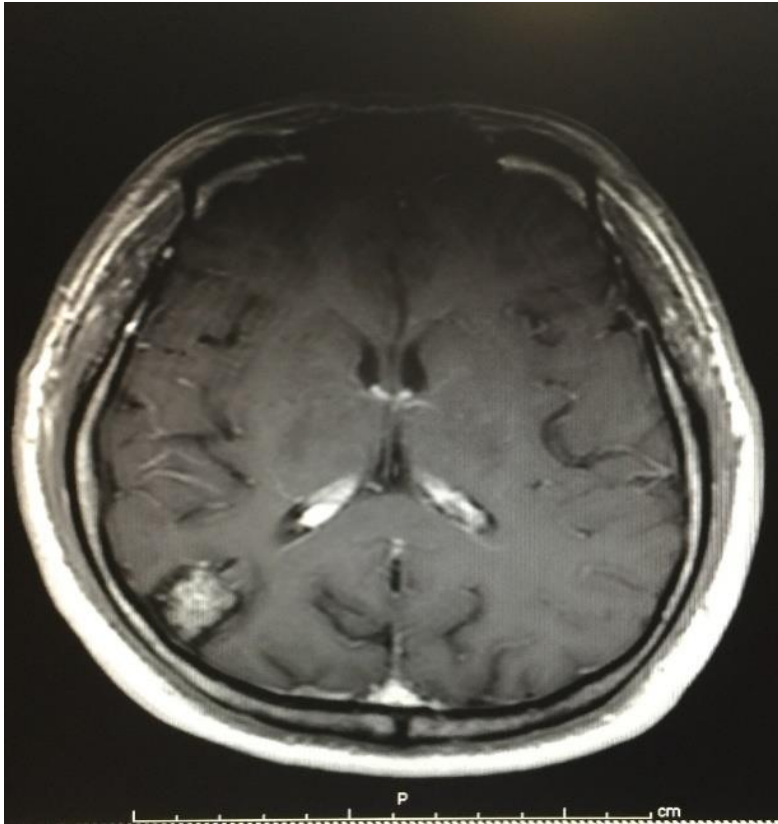


Physiological artifacts	Non-physiological artifacts
Eye <ul style="list-style-type: none">- Eye movements- Eye flutter	EEG instrument <ul style="list-style-type: none">- Power line- Magnetic field- Electronic components
Heart <ul style="list-style-type: none">- EKG- Pacemaker	Recording electrode <ul style="list-style-type: none">- Electrode placement- Electrode movement
Muscles <ul style="list-style-type: none">- Lateral rectus spikes- Swallowing- Chewing- EMG	Environment <ul style="list-style-type: none">- IV drip
Physiological movements <ul style="list-style-type: none">- Limb movements- Head tremors	

	Definition	Measures
Epileptogenic zone	The area of brain that is necessary and sufficient for initiating seizures and whose removal or disconnection is necessary for abolition of seizures	Theoretical concept
Irritative zone	Area of cortex that generates interictal EEG	EEG
Ictal onset zone	Area of cortex where seizures are generated	EEG
Epileptogenic lesion	Structural abnormality of the brain that is the direct cause of the epileptic seizures	Neuroimaging, tissue pathology
Symptomatogenic zone	Portion of the brain that produces the initial clinical symptomatology	Behavioral observation and patient report
Functional deficit zone	Cortical area of non-epileptic dysfunction	Neurologic exam, neuropsychological testing, EEG, PET, SPECT

A 40+yo with DRE who underwent for right parietal craniotomy with cavernoma excision and electrocorticography (ECoG)

ECoG showed few spikes at antero-inferior side of the lesion



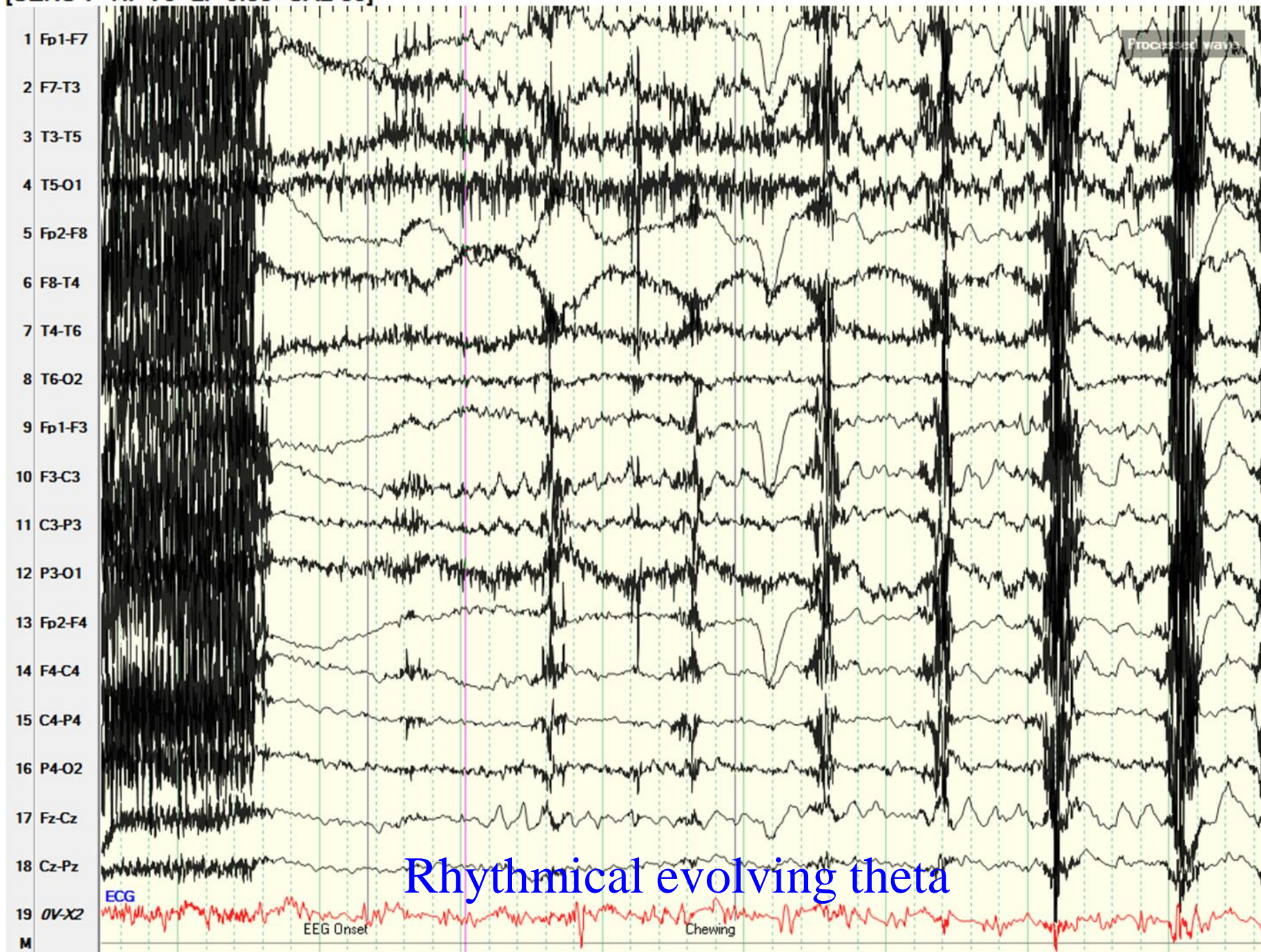
No seizure since surgery

Normal quality of life since then

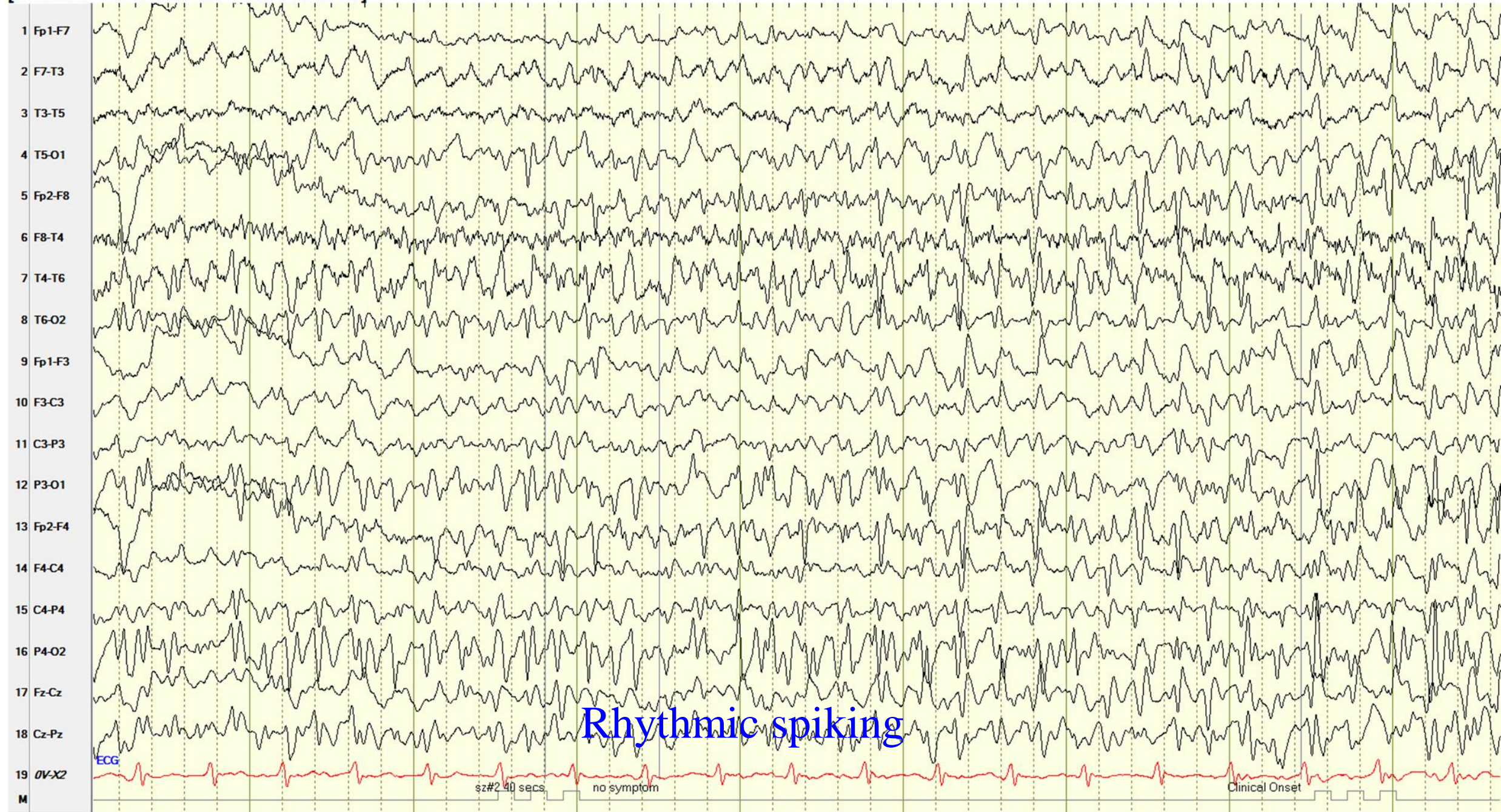
Common EEG patterns at the start of seizures in epileptic patients

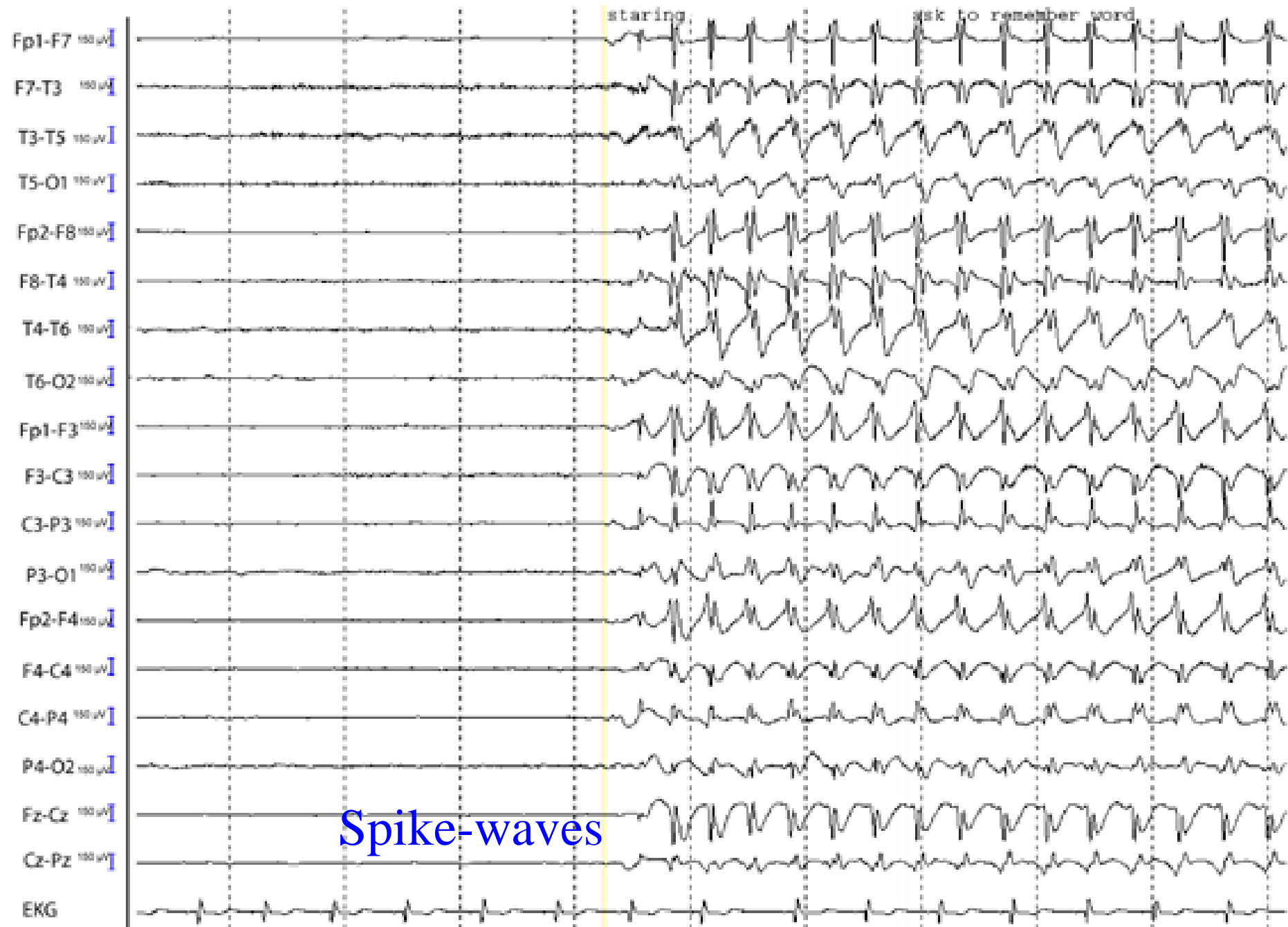
1. Rhythmical evolving theta, delta, alpha frequencies
2. Rhythmic spiking
3. Spike-waves
4. Electrodecremental
5. Clinical seizure with no significant EEG changes

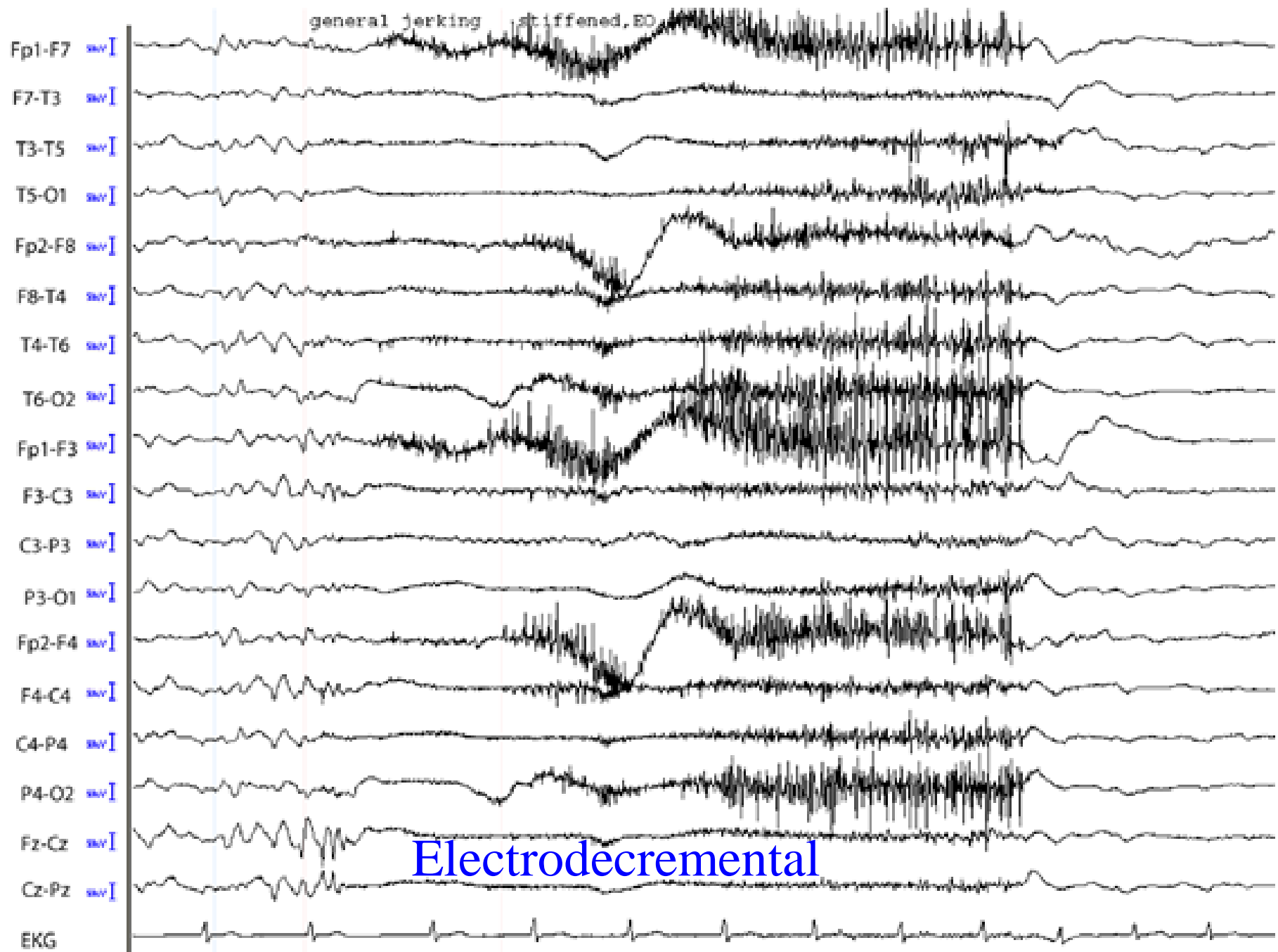
[SENS 7 HF 70 LF 0.53 CAL 50]



[SENS 7 HF 50RP LF 0.53 CAL 50]

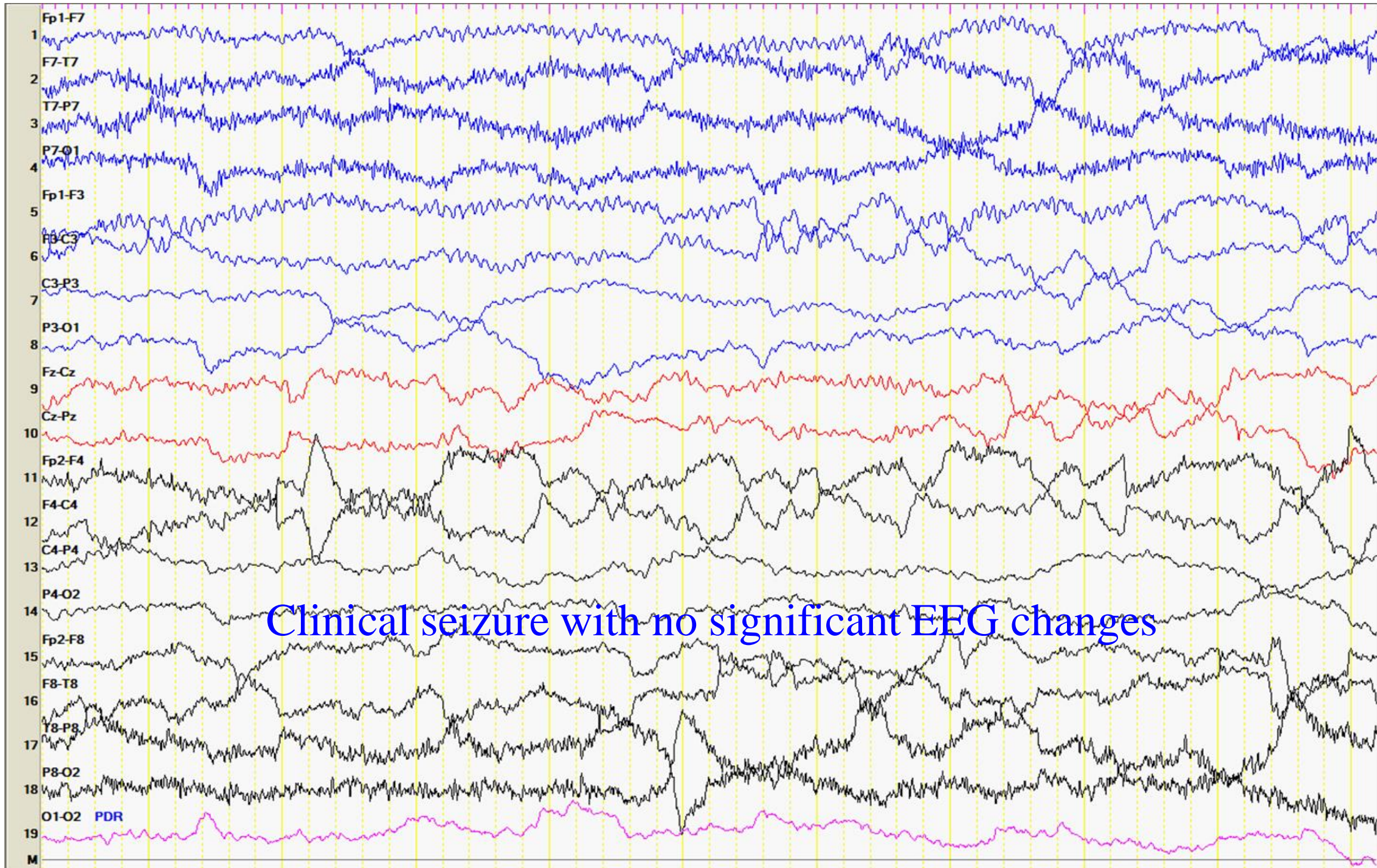






general jerking stiffened, ED

Electrodecremental



Interictal EEG findings in adult focal epilepsies

- Focal epilepsies typically have ictal patterns that are distinctly different from their interictal activity.
- Frequent interictal epileptiform discharges are usually not associated with clinical seizures and thus should be differentiated from electroencephalographic seizure patterns.

Ictal EEG findings in adult focal epilepsies

- Ictal onset pattern in focal epilepsies are variable.
- In scalp EEG recordings, focal seizures may not have a clear EEG correlate.

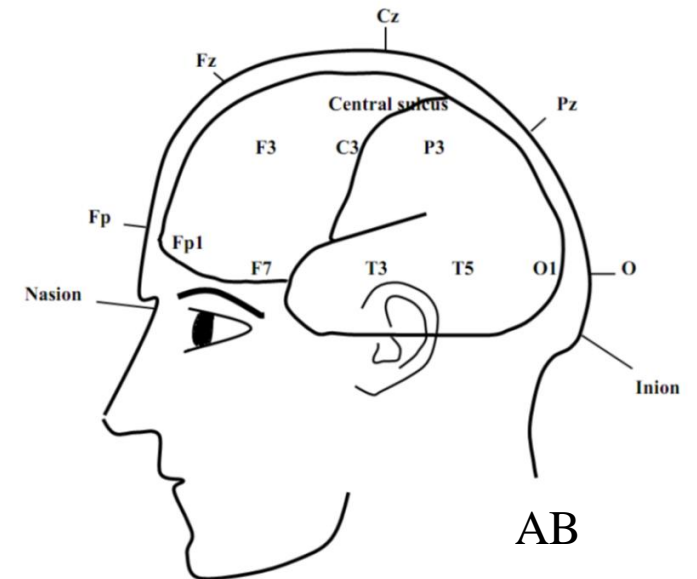
Limitation of EEG in focal epilepsy

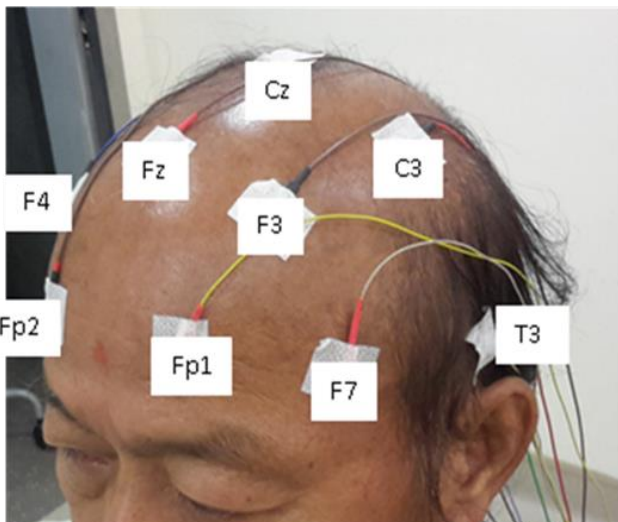
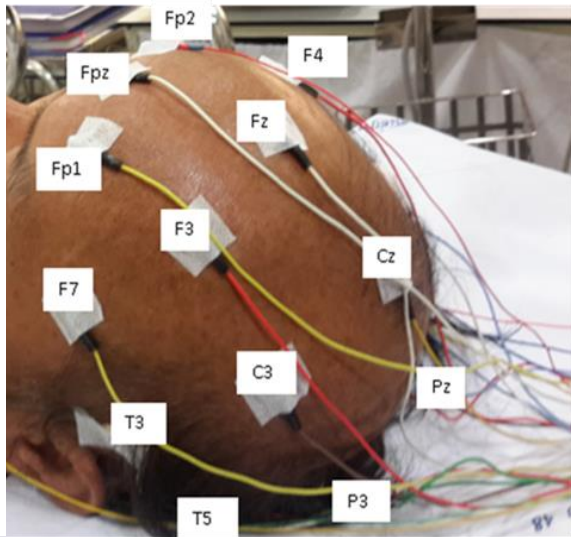
- The failure of scalp recordings to detect activity from a focal seizure may be explained by the seizure's distant location, limited extent, or disadvantageous orientation with respect to scalp electrodes.

- orbitofrontal cortex

- mesial frontal area

- basal temporal area

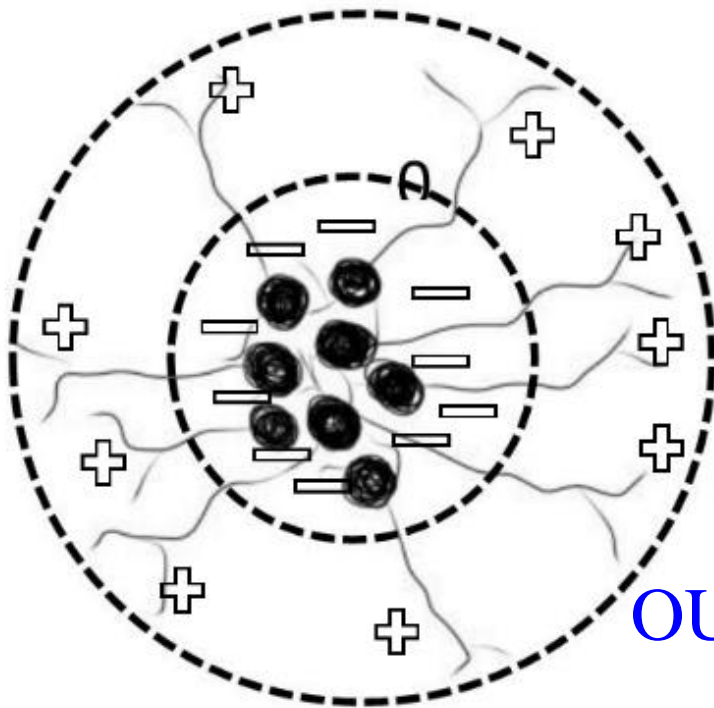




Closed field

vs

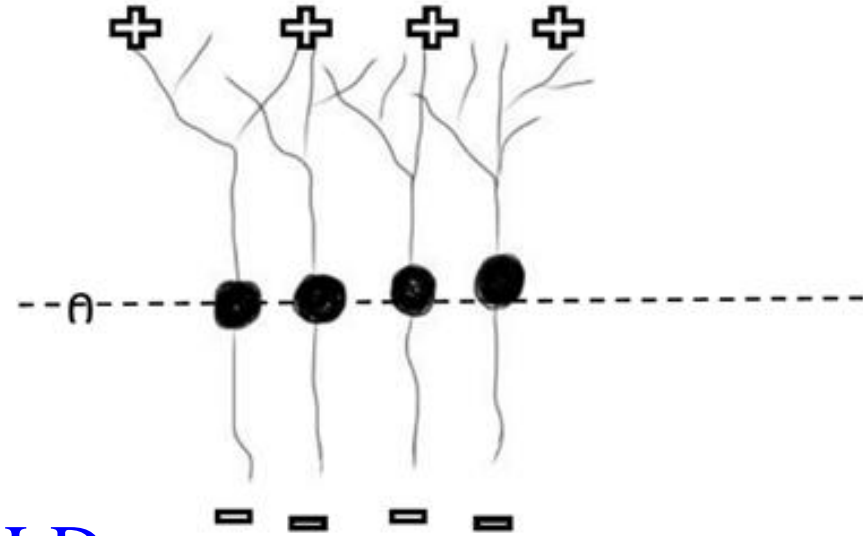
Open field



Observer

OUTSIDE THE FIELD

AB



Observer

AB

Is there any standard criteria
for EEG seizure onset?

Focal-onset seizure

- Localized ictal EEG
- Lateralized ictal EEG

Focal-onset seizure with spreading patterns

- Lateralization of ictal EEG
- Diffuse ictal pattern without lateralization
- Asynchronous and independent rhythms on both cerebral hemispheres
- Switch of lateralization” from the hemisphere of origin to the contralateral side

Secondary generalization

- Synonym: secondary bilateral synchrony
- Spreading of an initially focal (regional) epileptiform discharge to become generalized. Secondary generalization frequently occurs from midline frontal generators.

Postictal period in focal epilepsies

- Postictal symptoms
 - observation for any lateralizing signs
- Postictal EEG changes
 - may help in identifying the seizure focus

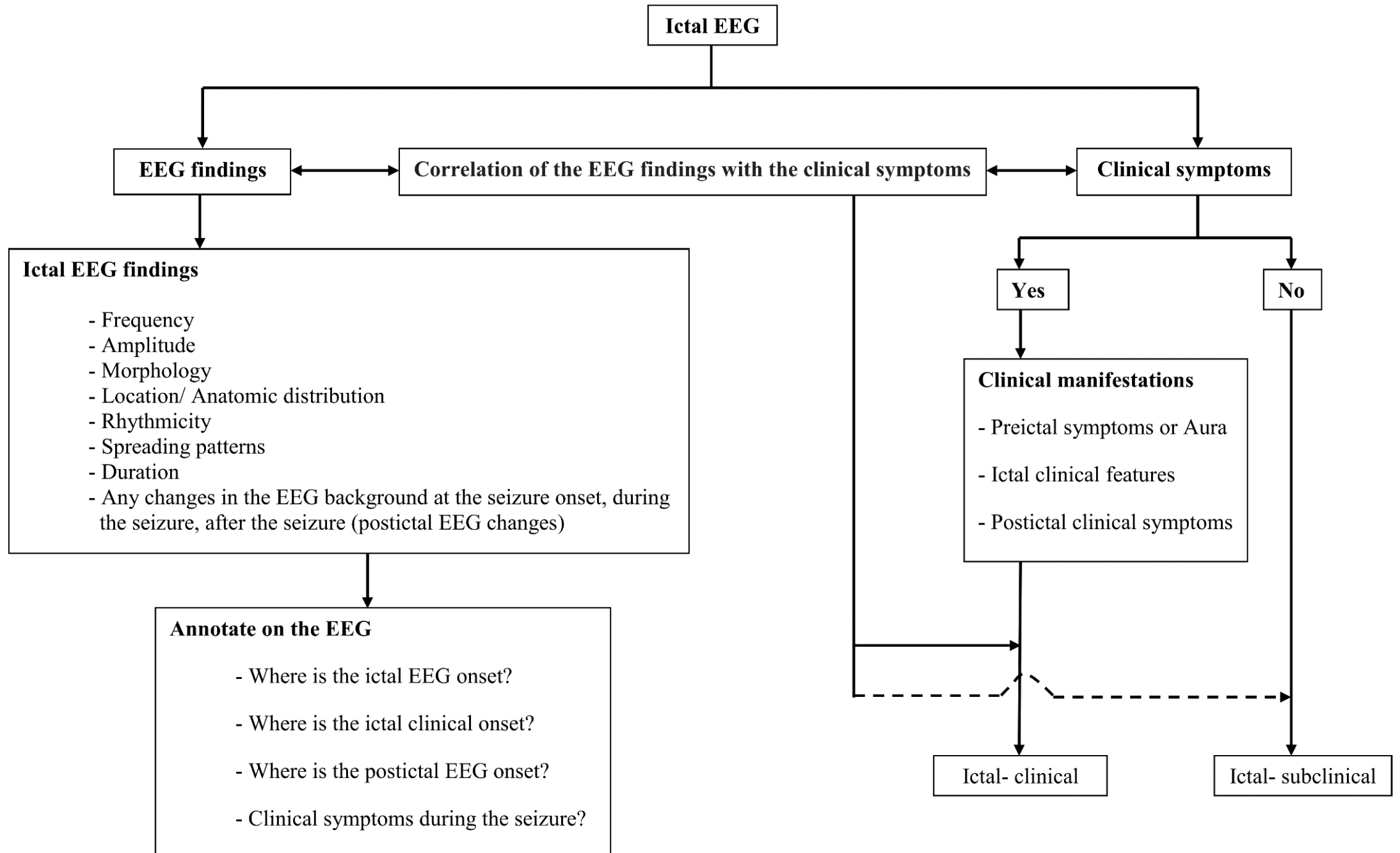
EEG interpretation

Reading the adult EEG

- Check the patient name, age, and hospital number
- Reasons for EEG study
- Open the EEG file (date of EEG study)
- Choose the EEG montage
- Check the EEG setting
 - factors affecting vertical display: sensitivity(7 microvolts/mm)
low frequency filter(1Hz)
high frequency filter (70Hz)
 - factors affecting horizontal display: time base (30 mm/second)

EEG analysis

- Preceding EEG background
 - awake and sleep EEG
- Ictal EEG
 - identifiable change from the interictal EEG background at seizure onset
 - evolution in amplitude and frequency of EEG background.
- Postictal EEG
 - termination of ictal EEG

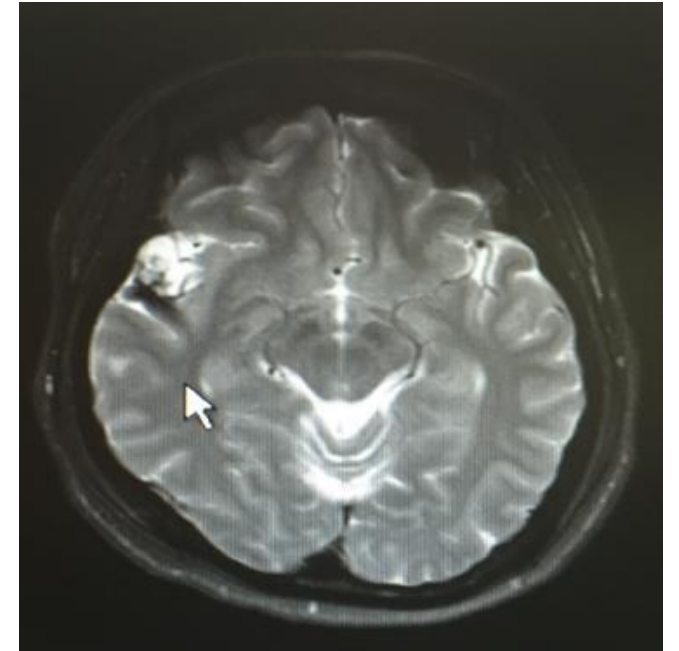


Example

- A 34 yo female with drug-resistant temporal lobe epilepsy who is here for seizure evaluation.

Seizure type1: left versive → GTC

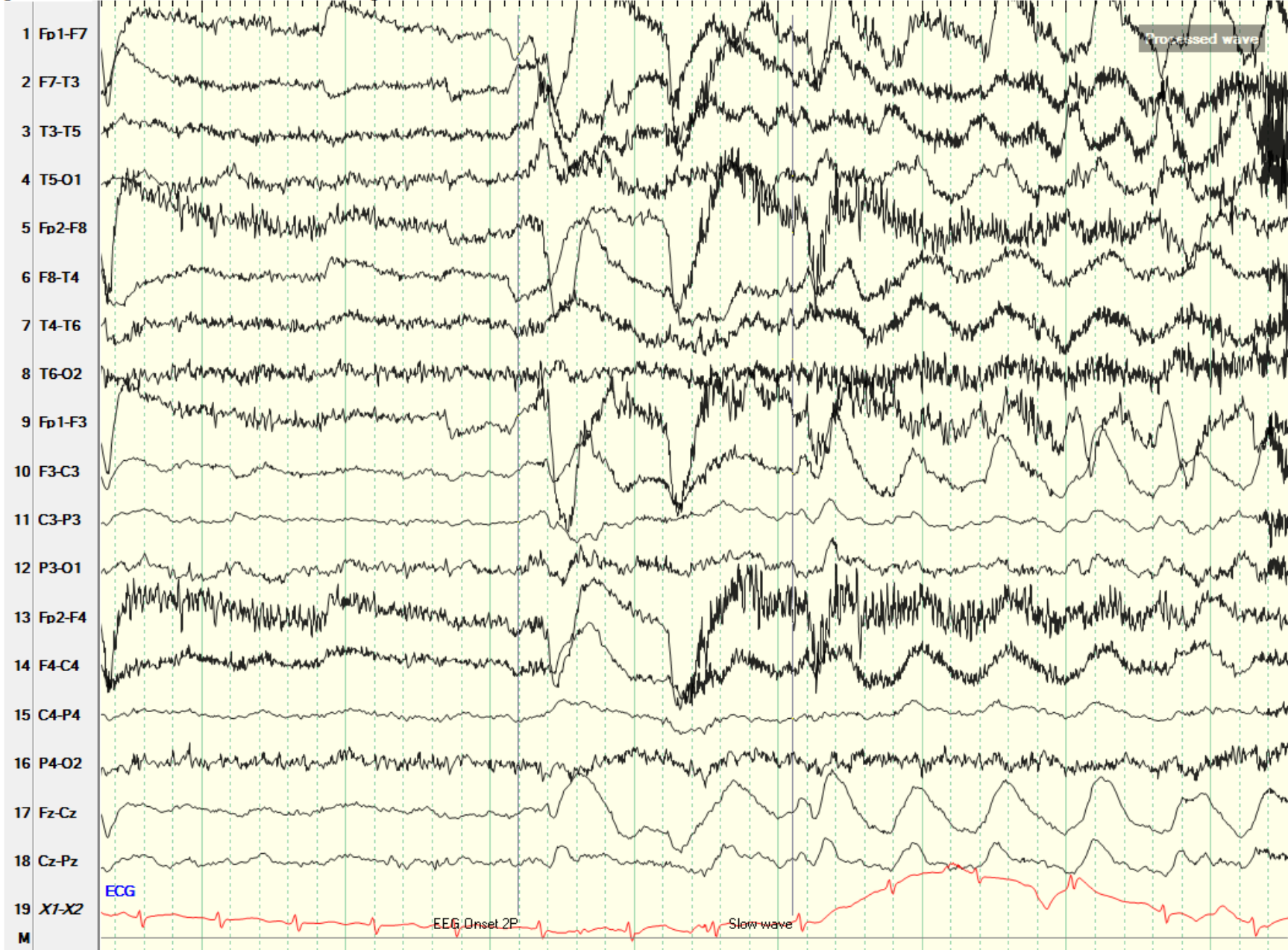
- Interictal EEG: bilateral independent interictal epileptiform discharges



MRI shows cystic encephalomalacic changes at right anterior temporal lobe

Ictal EEG

[SENS 7 HF 70 LF 0.53 CAL 50]

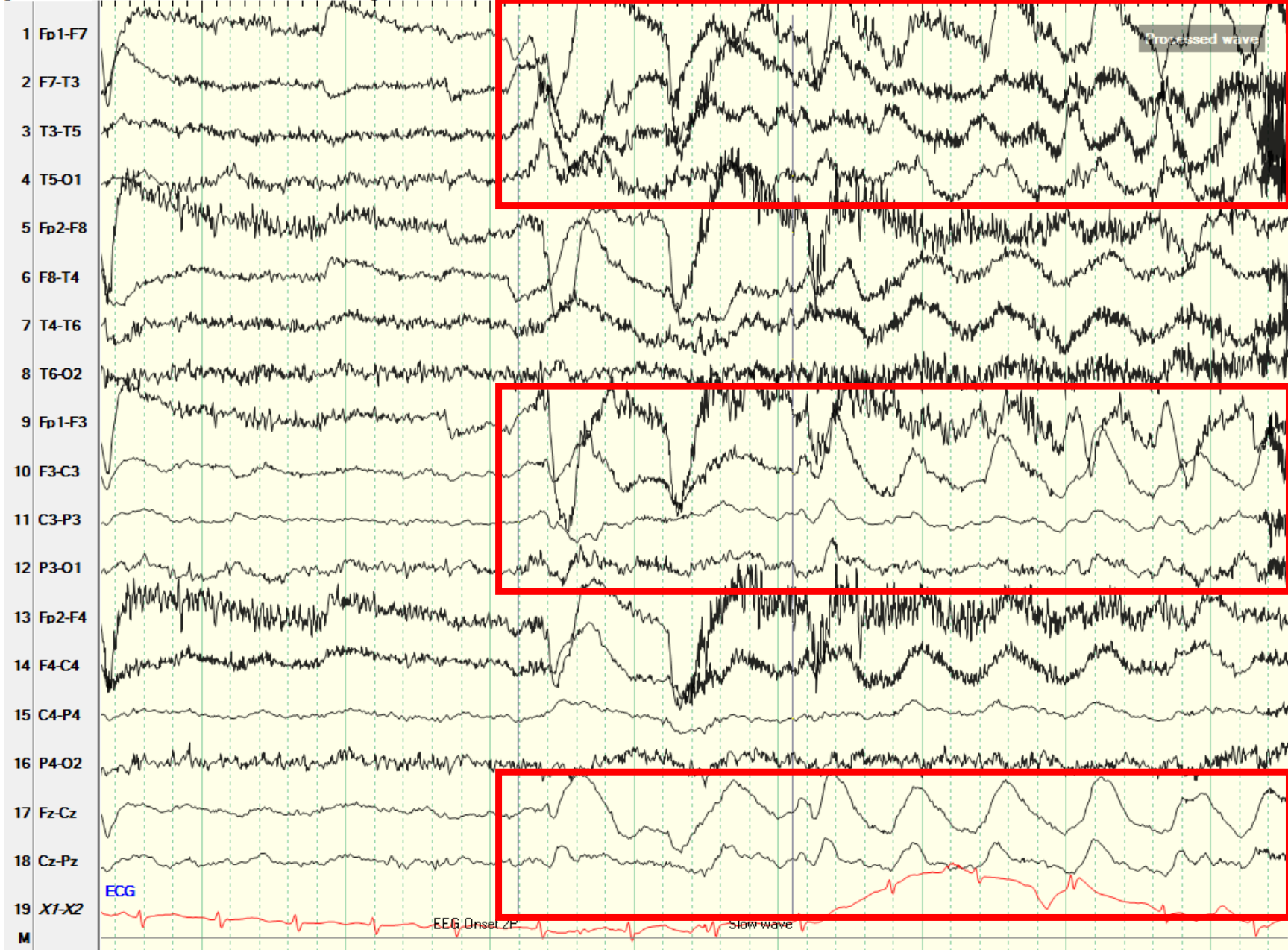


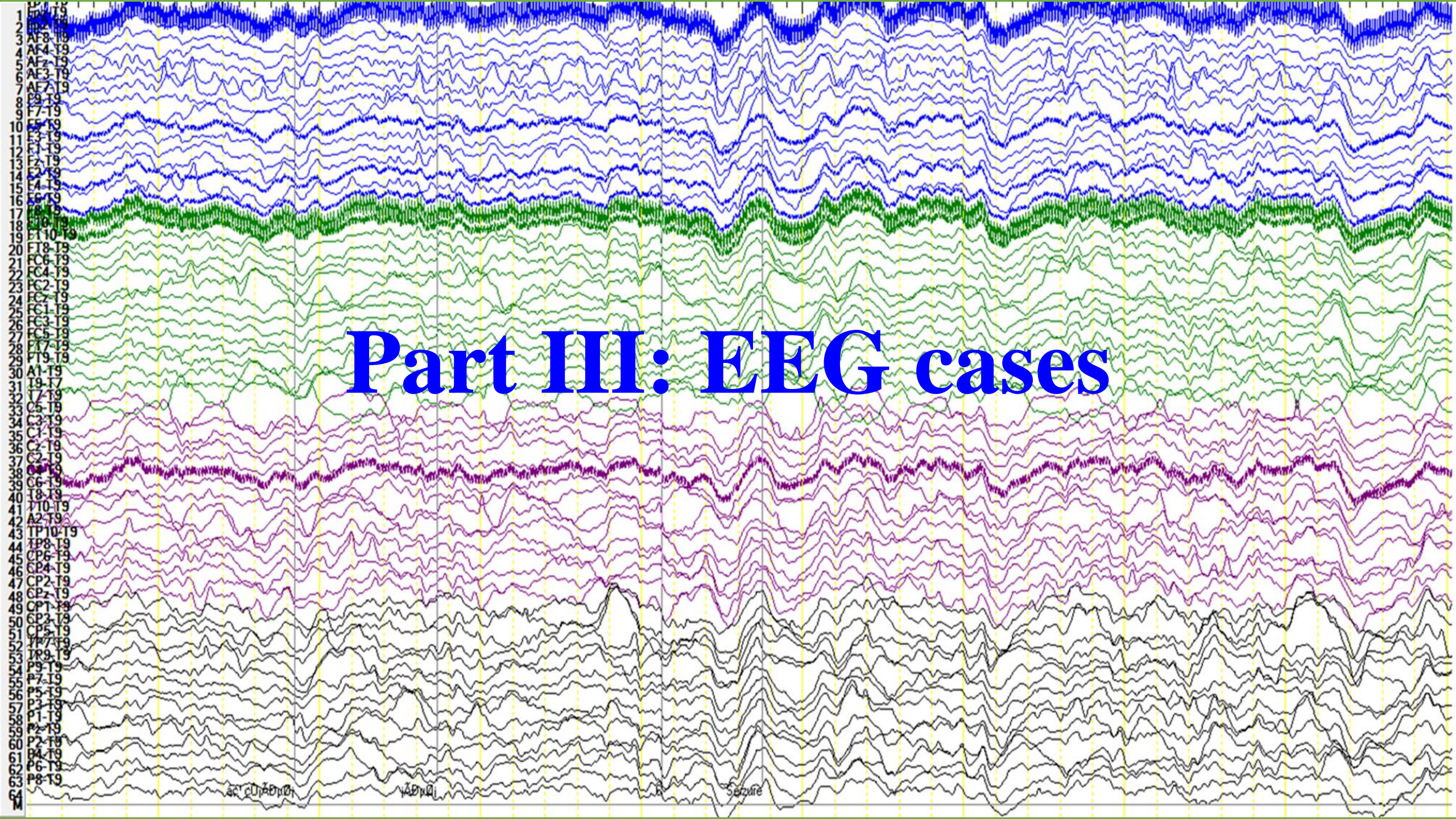
Electrographic evolution of a focal-onset seizure

- The electrographic evolution of a focal-onset seizure commonly includes one or more of the following features:
 - frequency
 - amplitude
 - distribution
 - waveform morphology

Ictal EEG

[SENS 7 HF 70 LF 0.53 CAL 50]





Part III: EEG cases

1 TP2-T9
2 AF8-T9
3 AF4-T9
4 AF2-T9
5 AF3-T9
6 AF7-T9
7 F9-T9
8 F7-T9
9 F5-T9
10 F3-T9
11 F1-T9
12 F2-T9
13 F4-T9
14 FC6-T9
15 FC4-T9
16 FC2-T9
17 FC1-T9
18 FC3-T9
19 FC5-T9
20 FT7-T9
21 FT9-T9
22 A1-T9
23 T9-T9
24 T7-T9
25 C5-T9
26 C3-T9
27 C1-T9
28 C2-T9
29 C4-T9
30 C6-T9
31 T8-T9
32 TP10-T9
33 TP8-T9
34 CP6-T9
35 CP4-T9
36 CP2-T9
37 CP1-T9
38 CP3-T9
39 TP7-T9
40 TP9-T9
41 P9-T9
42 P7-T9
43 P5-T9
44 P3-T9
45 P1-T9
46 P2-T9
47 P4-T9
48 P6-T9
49 P8-T9
50
51
52
53
54
55
56
57
58
59
60
61
62
63
64

Seizure M

Part III: EEG workshop

- Temporal lobe epilepsy
- Frontal lobe epilepsy
- Parietal lobe epilepsy
- Occipital lobe epilepsy

Ictal EEG in temporal lobe epilepsy (TLE)

- The features of temporal lobe epilepsy can be divided into two broad categories.
 1. mesial onset (MTLE)
 2. lateral (neocortical) onset (NTLE)

	MTLE	NTLE
Suggestive clinical history	viscerosensory aura psychic aura oral and hand automatisms	auditory phenomena psychic aura visual aura aphasia
Ictal EEG	focal unilateral anterior temporal regular and rhythmic temporal theta or alpha activity (typically 5-9 Hz) *	irregular, polymorphic delta slow waves with lateralization **
Secondary generalization	slower	faster

* Neurology. 1997 Sep;49(3):757-63

**Epilepsia. 1996 Apr;37(4):386-99.

MTLE

- Scalp ictal EEG
 - focal unilateral anterior temporal regular and rhythmic temporal theta or alpha activity (typically 5-9Hz) is the hallmark of MTLE.

Case#1 mesial temporal sclerosis

- A 20+yo right-handed female with past medical history of epilepsy and febrile seizure who was referred from an OSH. The history of seizure began at the age of 12.

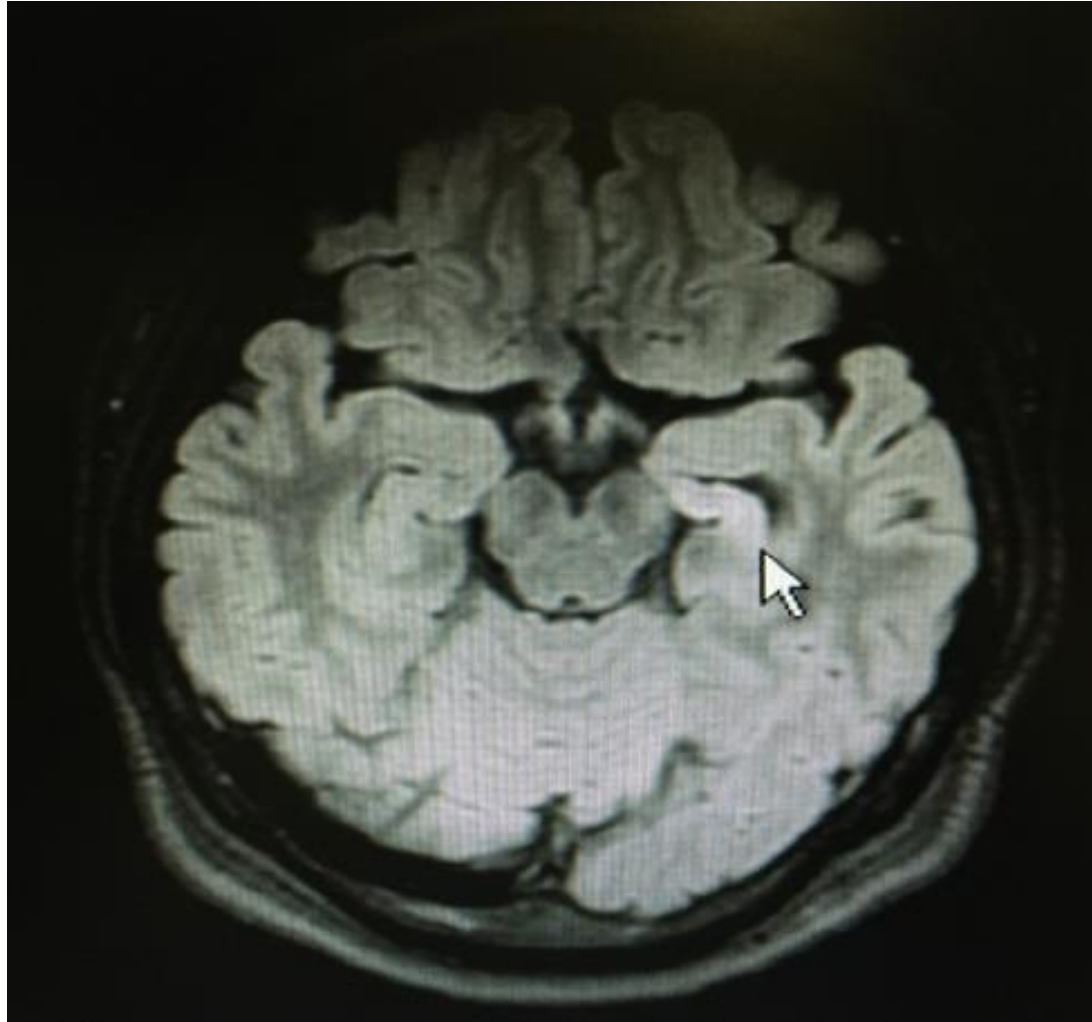
Seizure type1: psychic aura → loss of awareness

Seizure frequency: 1-2 times per day

Seizure duration: 1-2 minutes

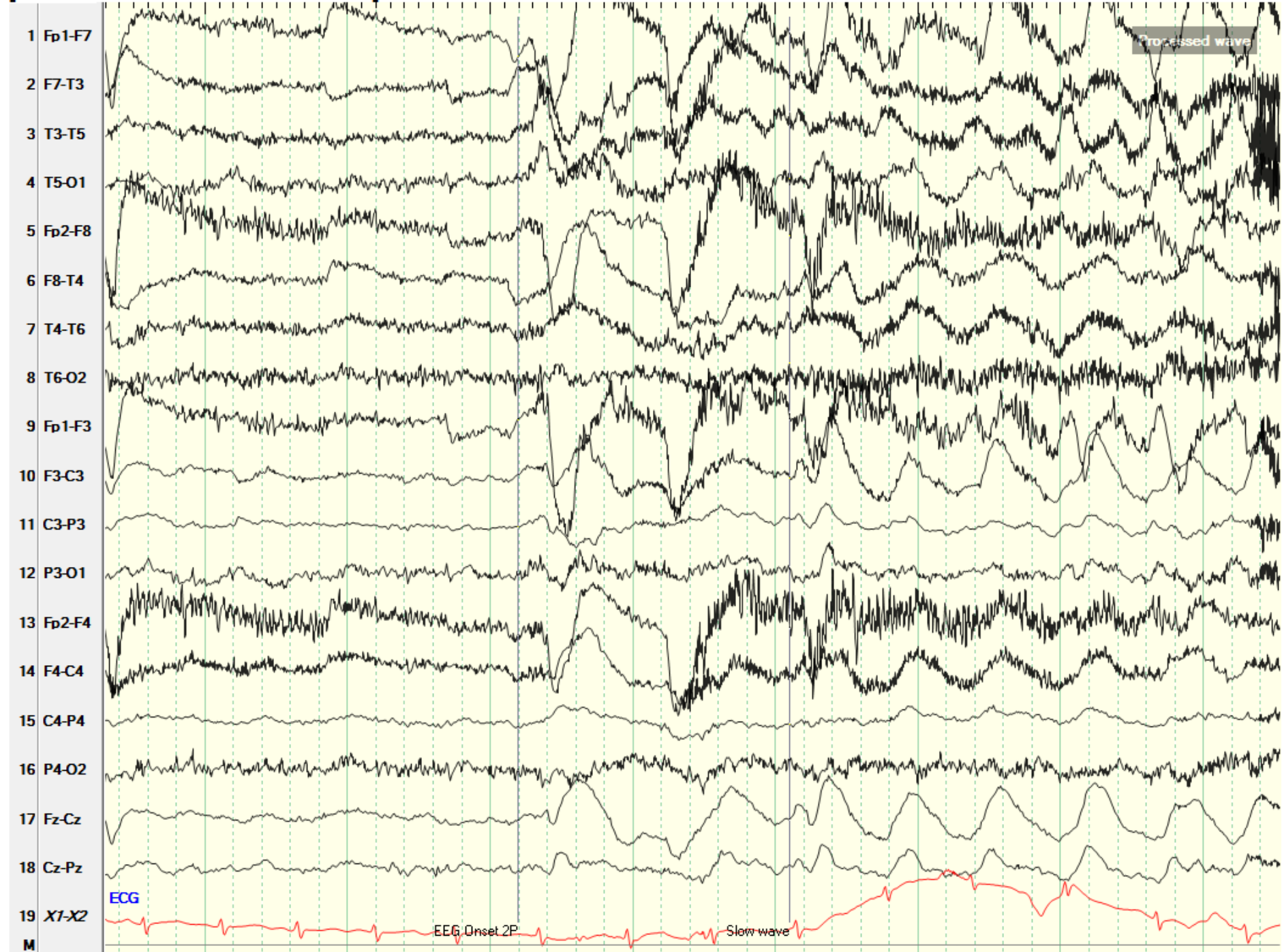
Current AEDs: LTG, LEV

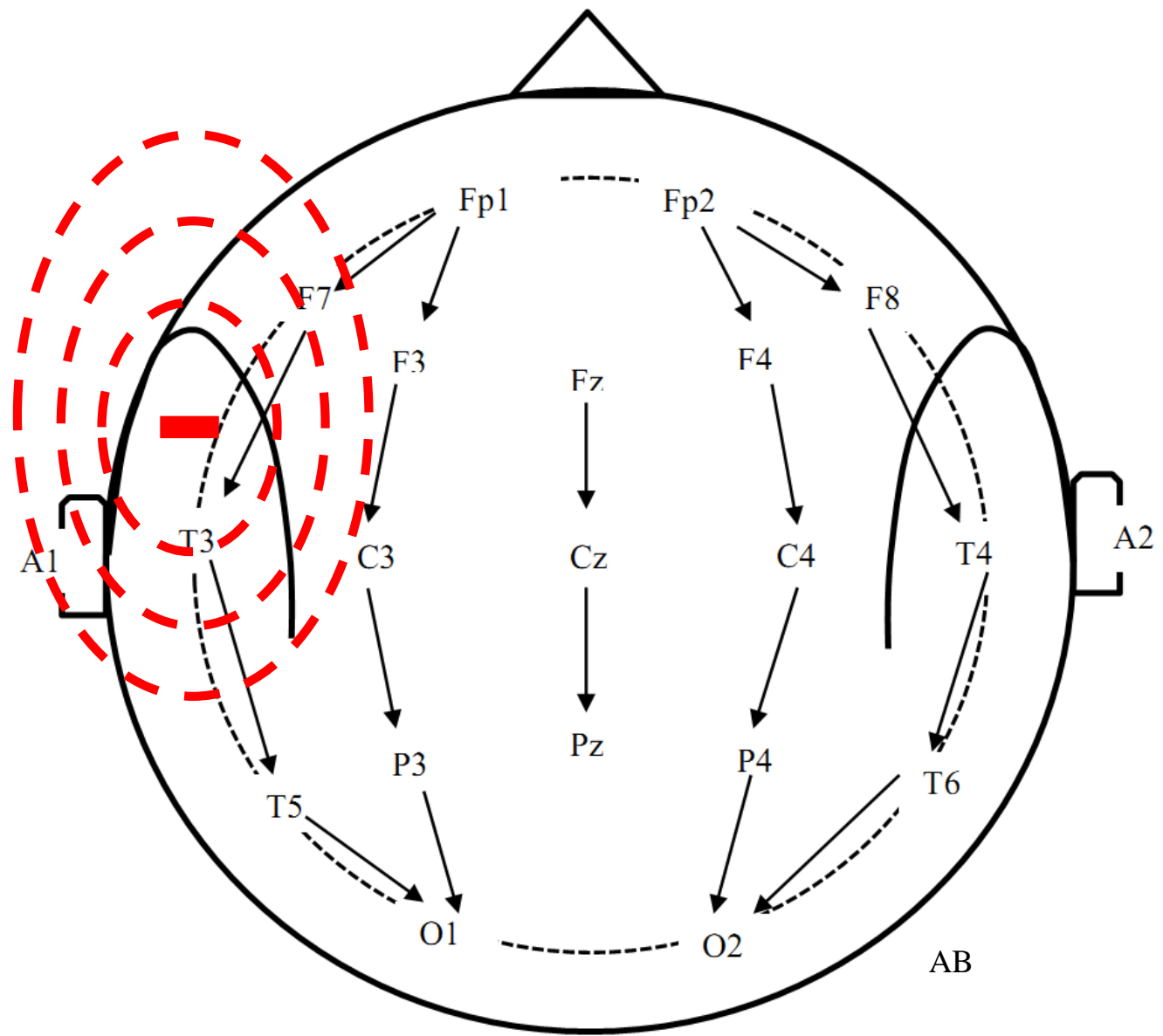
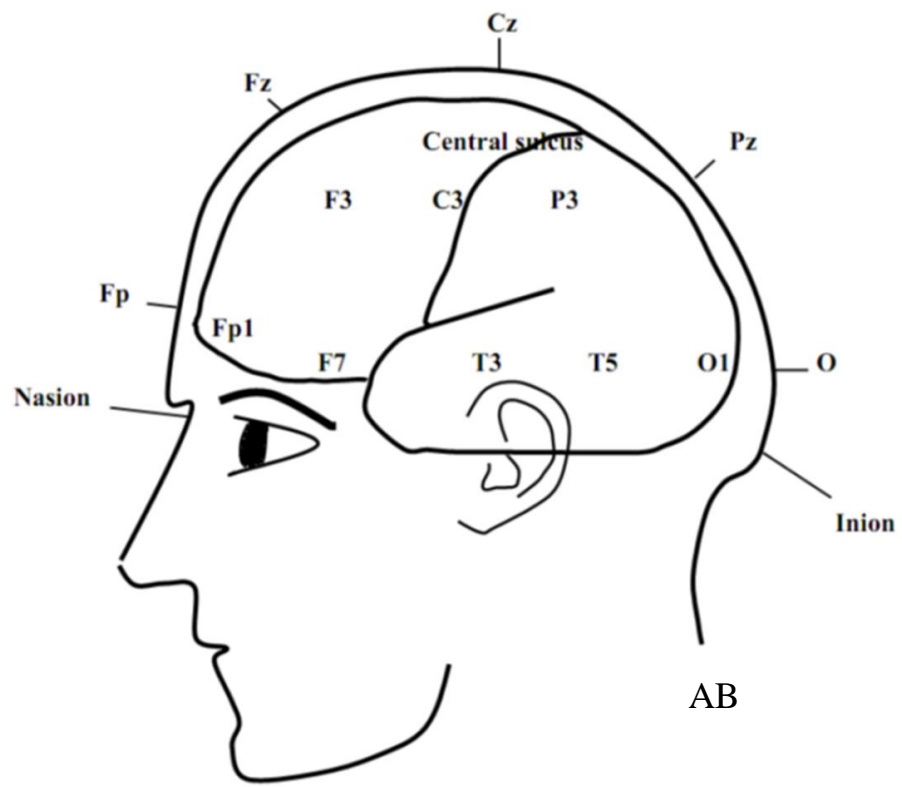
Past AEDs: PHT, CBZ, VPA, acetazolamide, ZNS, LCS



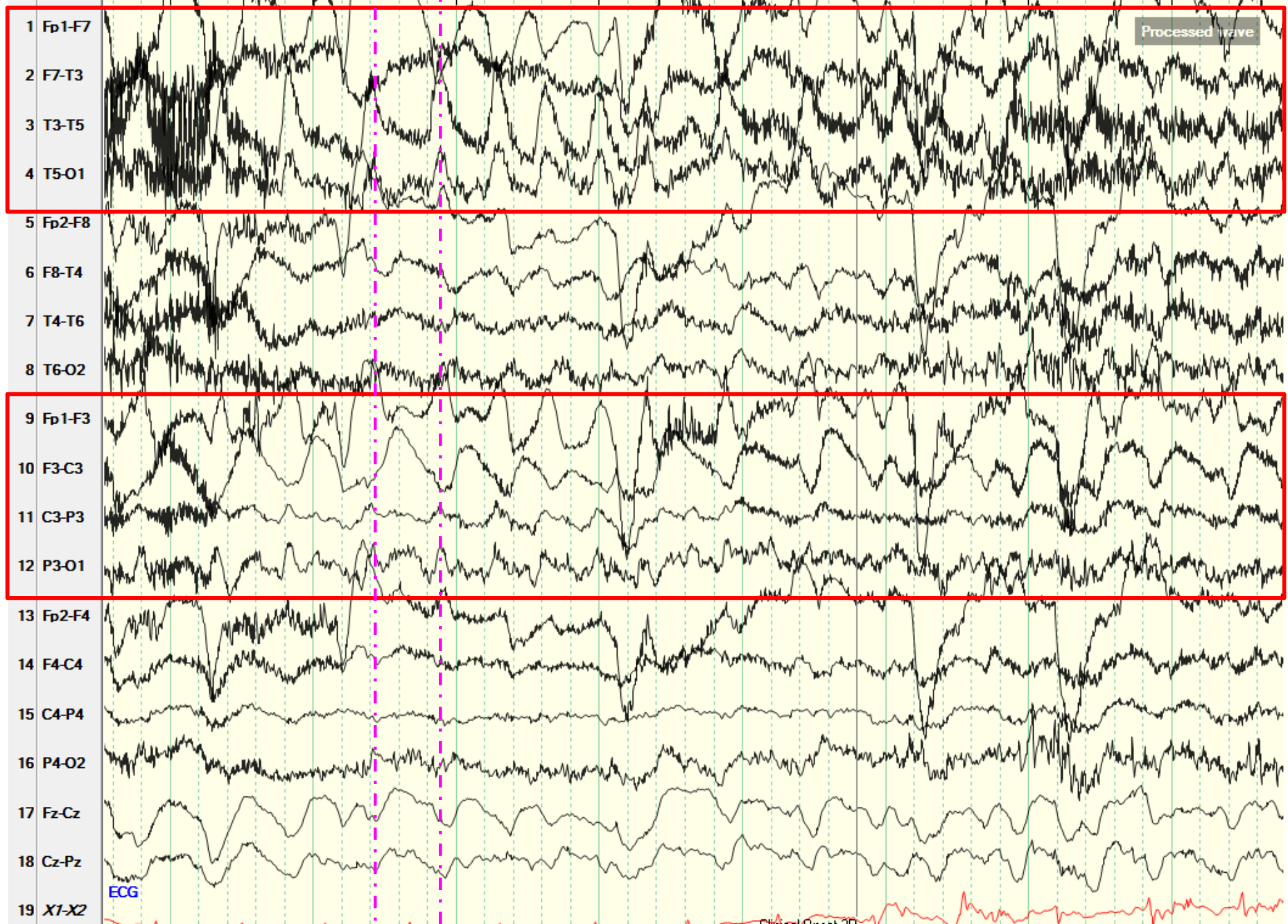


MRI brain: left mesial temporal sclerosis

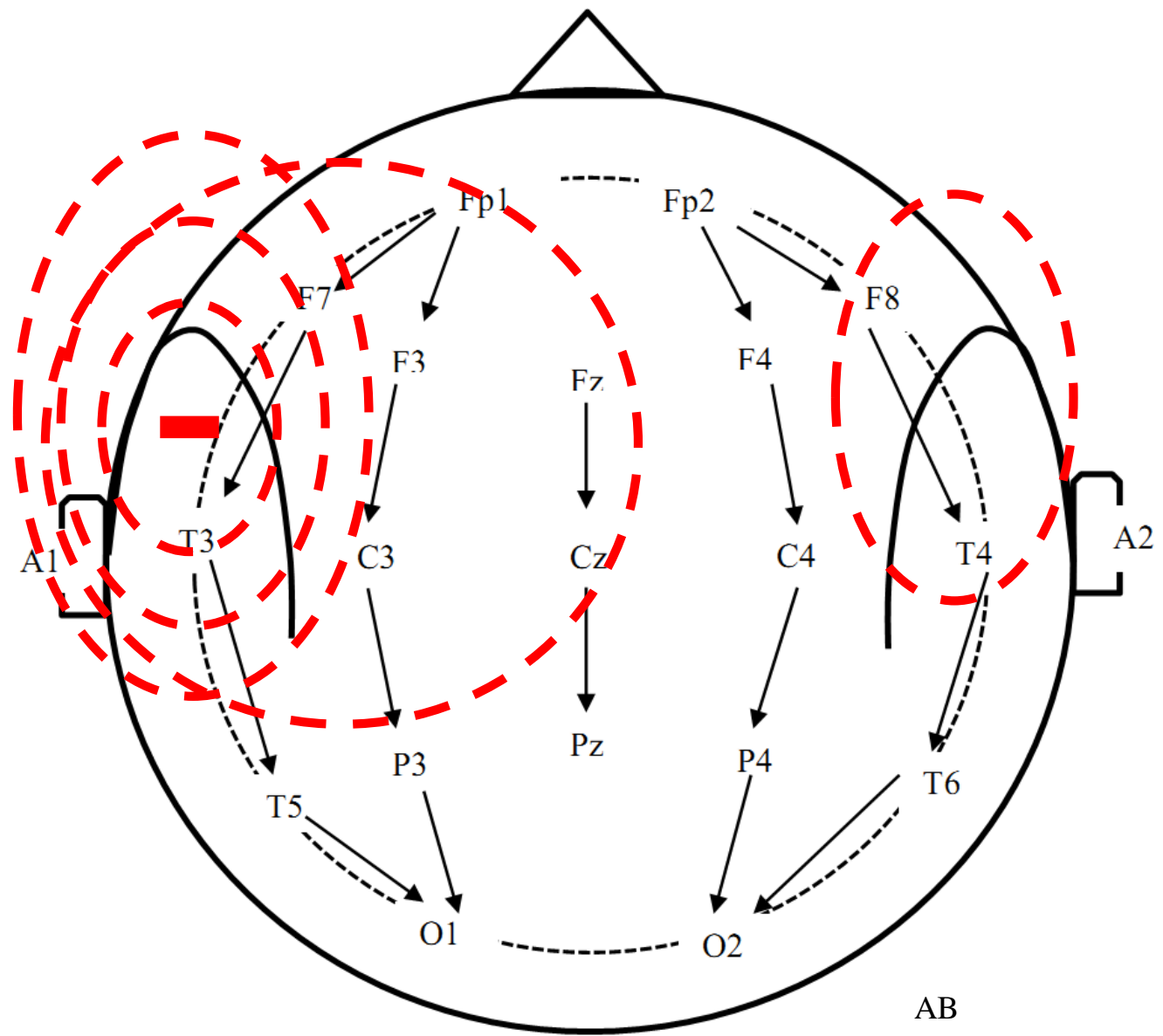
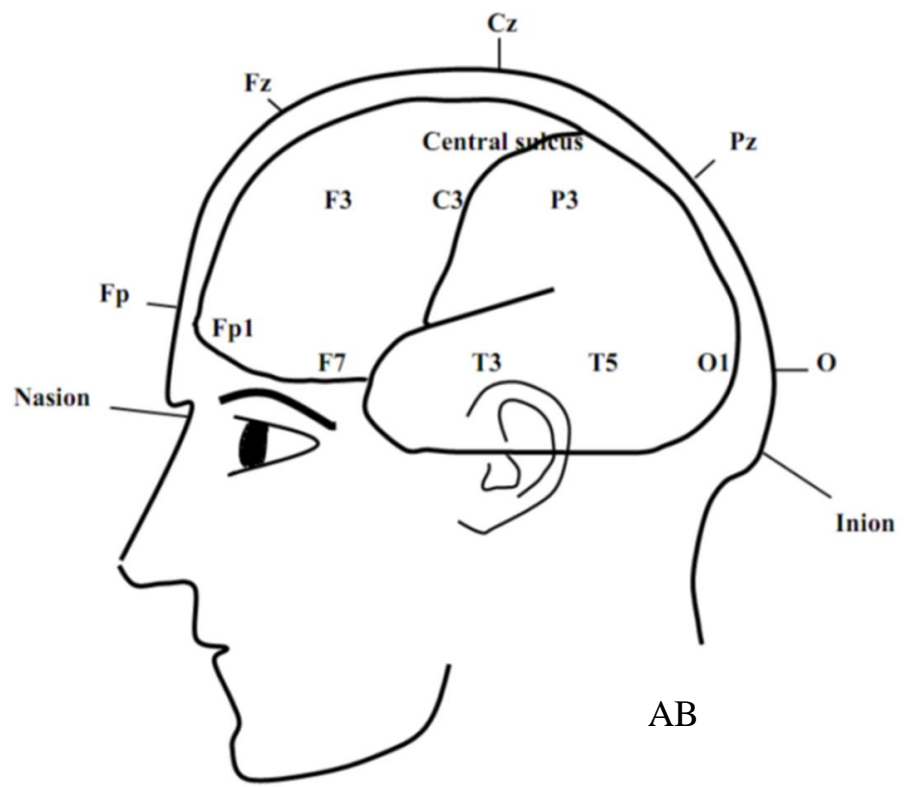
[SENS 7 HF 70 LF 0.53 CAL 50]



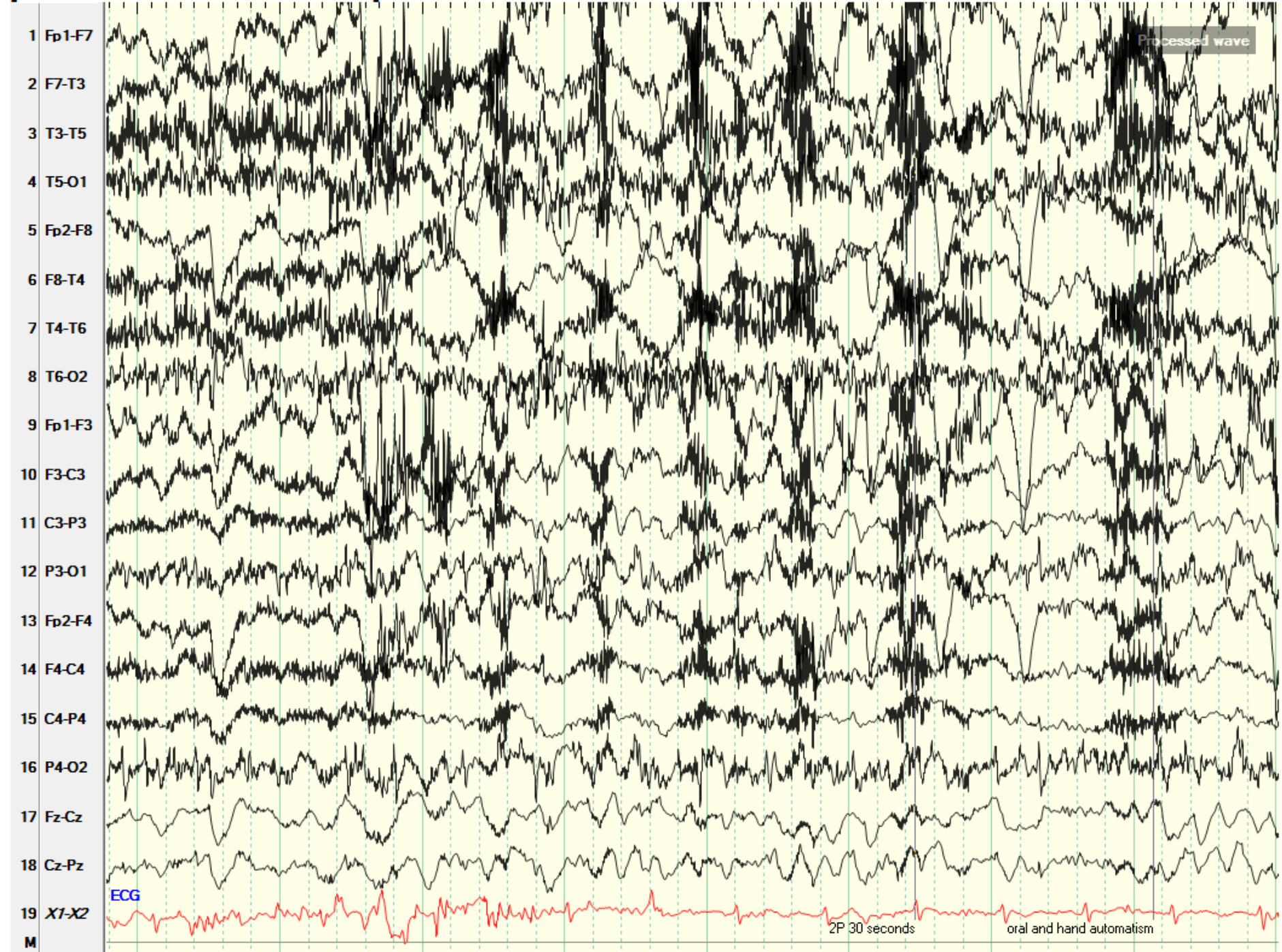


[SENS 7 HF 70 LF 0.53 CAL 50]





[SENS 7 HF 70 LF 0.53 CAL 50]



Processed wave

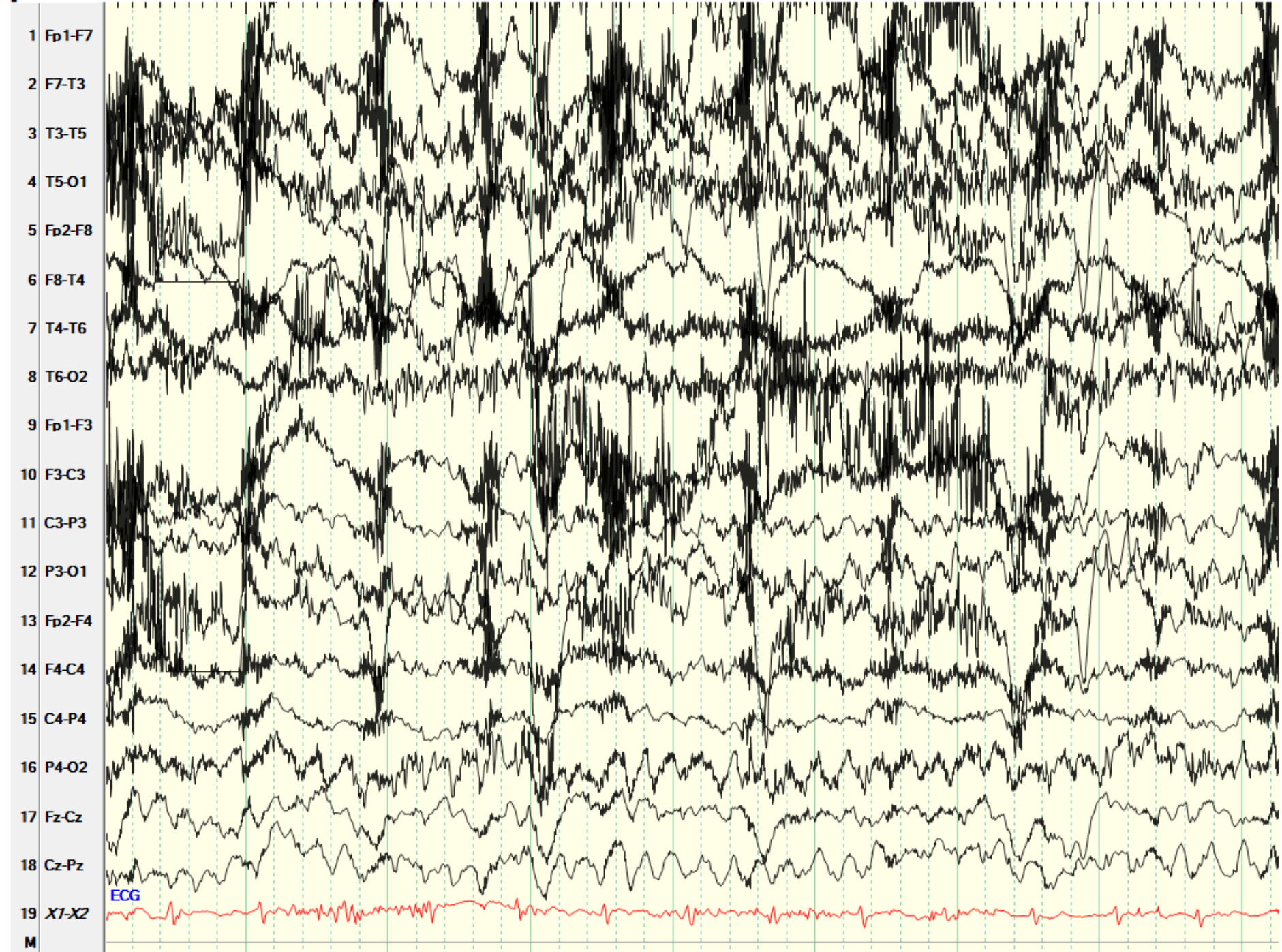
ECG

2P 30 seconds

oral and hand automatism

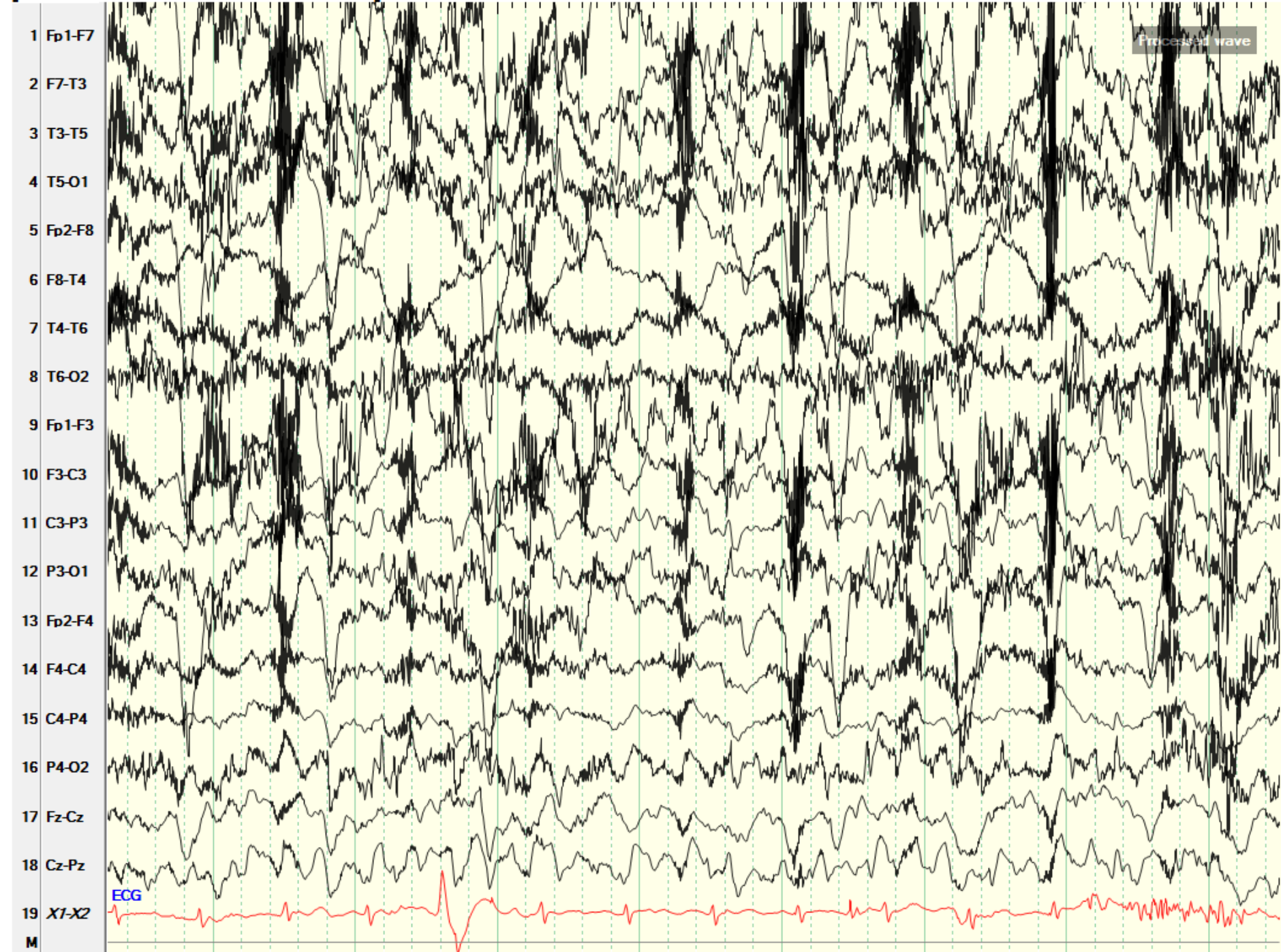M

[SENS 7 HF 70 LF 0.53 CAL 50]

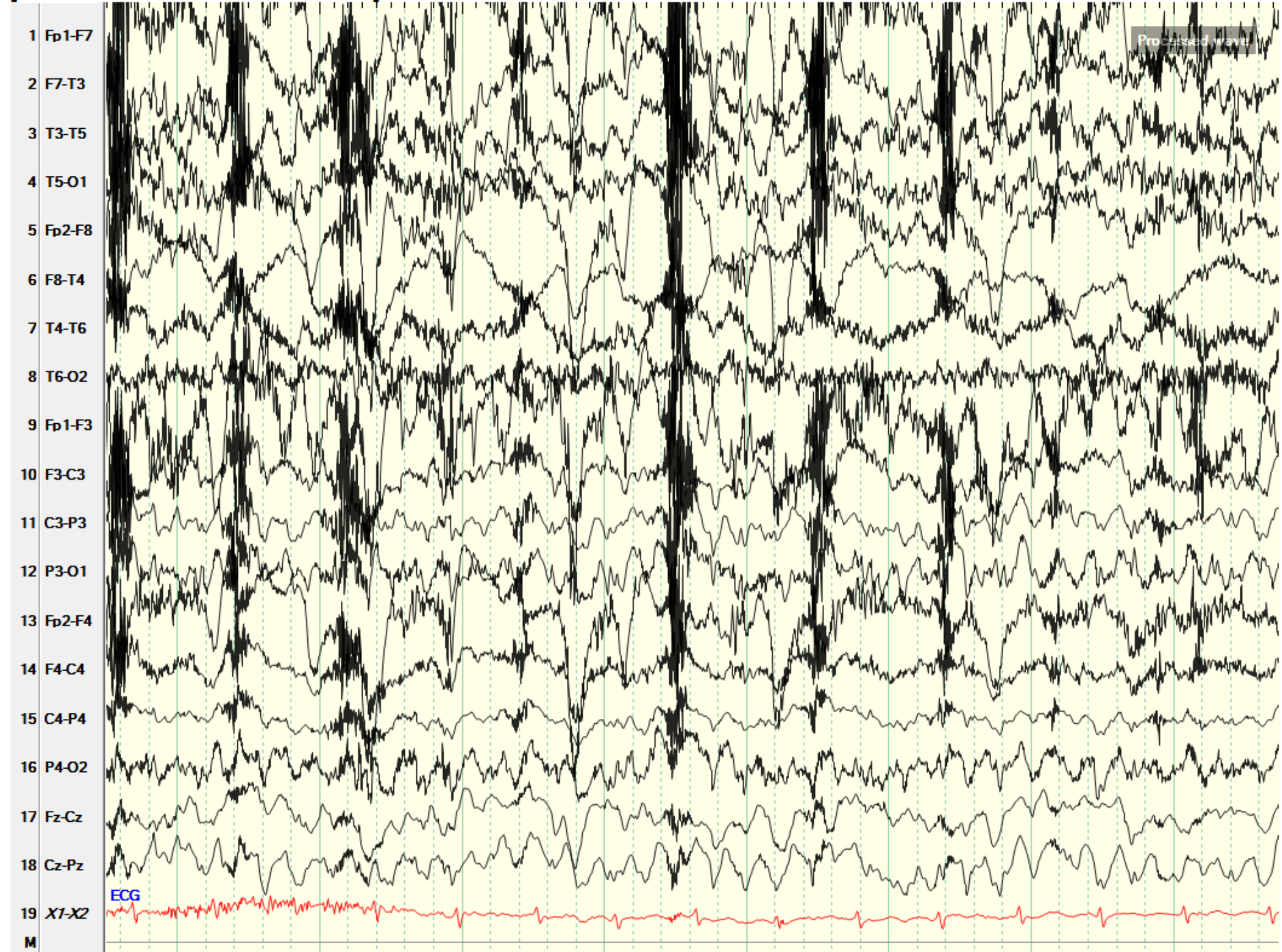

M

[SENS 7 HF 70 LF 0.53 CAL 50]

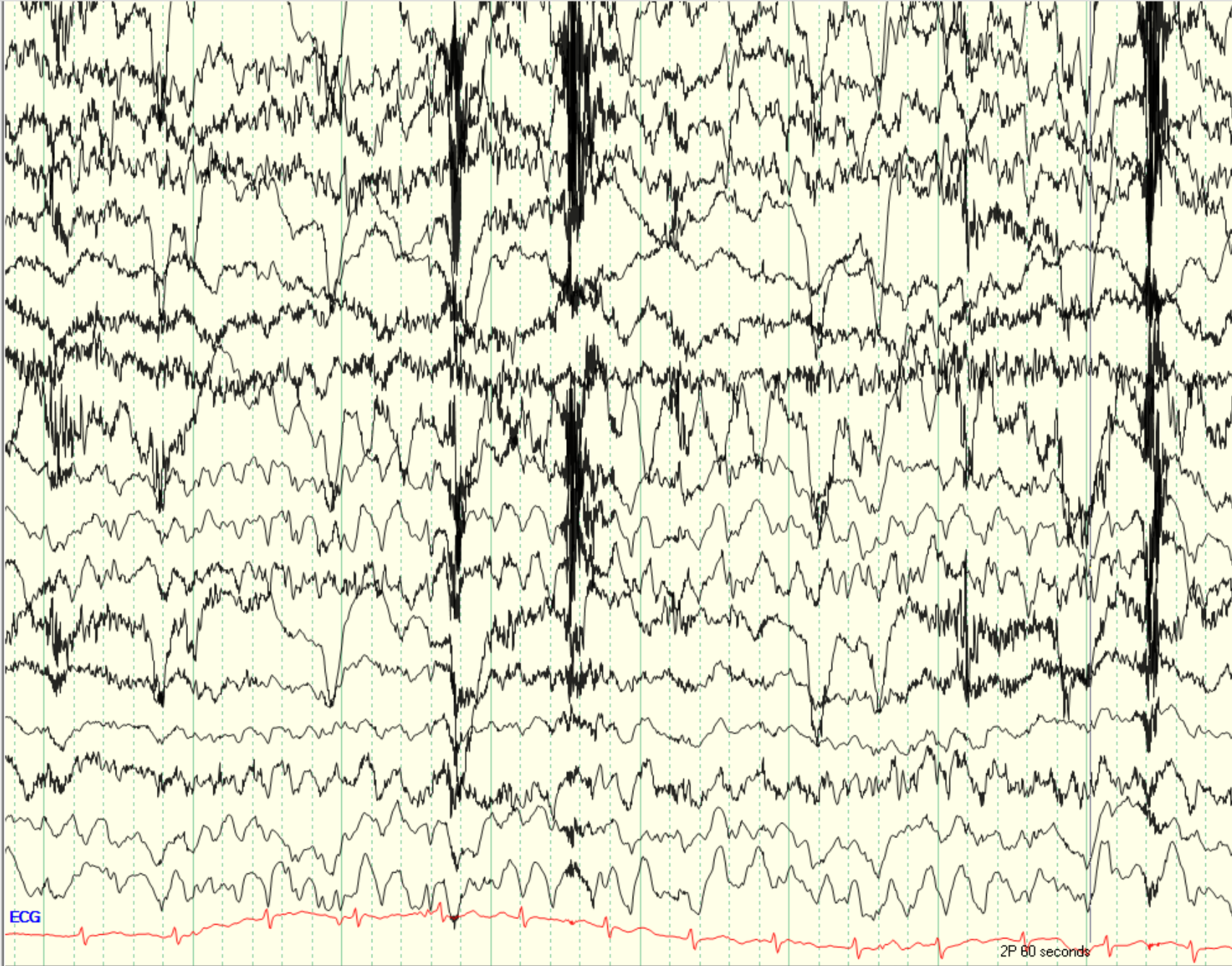

[SENS 7 HF 70 LF 0.53 CAL 50]

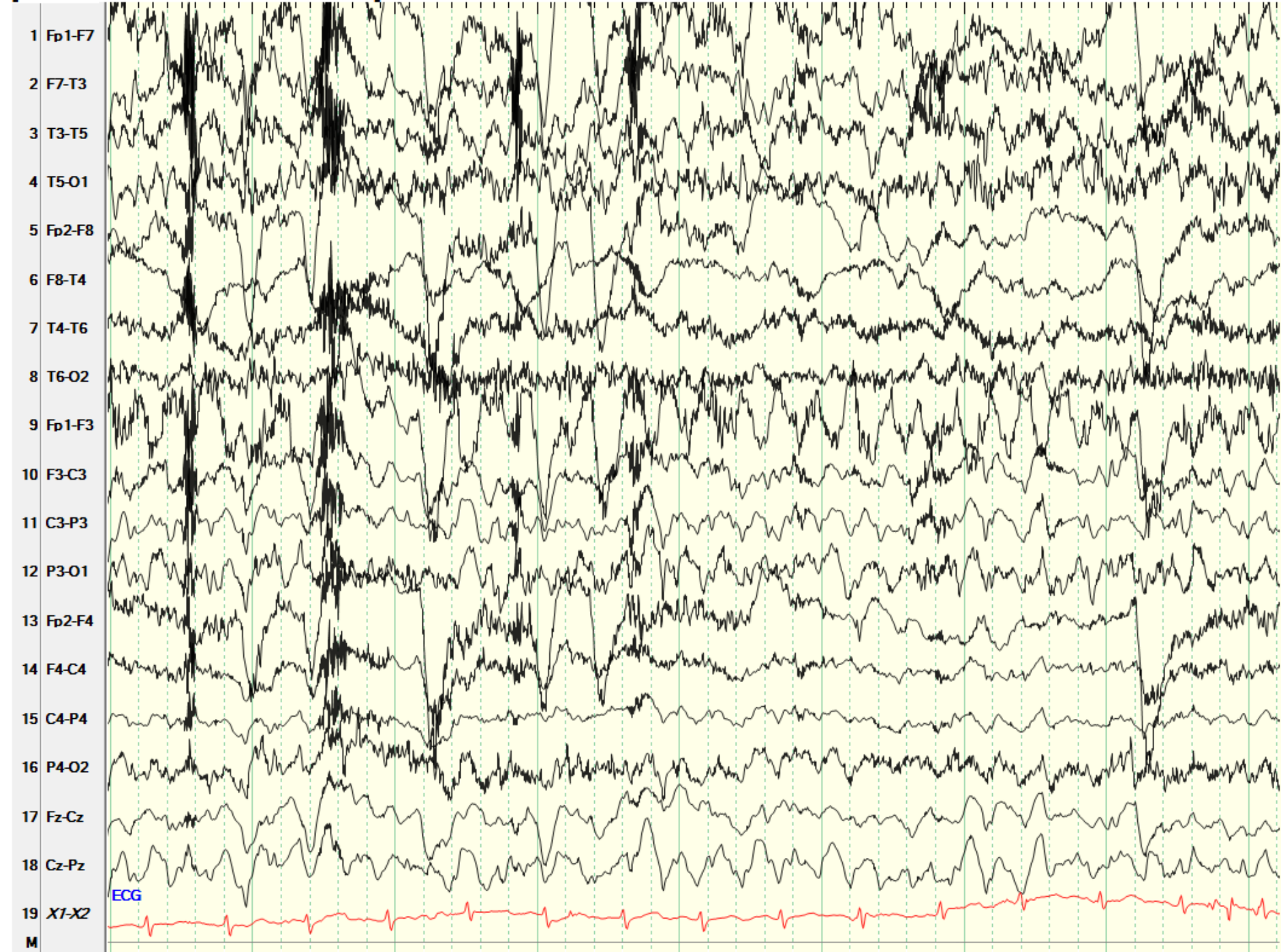


M

- 1 Fp1-F7
- 2 F7-T3
- 3 T3-T5
- 4 T5-O1
- 5 Fp2-F8
- 6 F8-T4
- 7 T4-T6
- 8 T6-O2
- 9 Fp1-F3
- 10 F3-C3
- 11 C3-P3
- 12 P3-O1
- 13 Fp2-F4
- 14 F4-C4
- 15 C4-P4
- 16 P4-O2
- 17 Fz-Cz
- 18 Cz-Pz
- 19 X1-X2

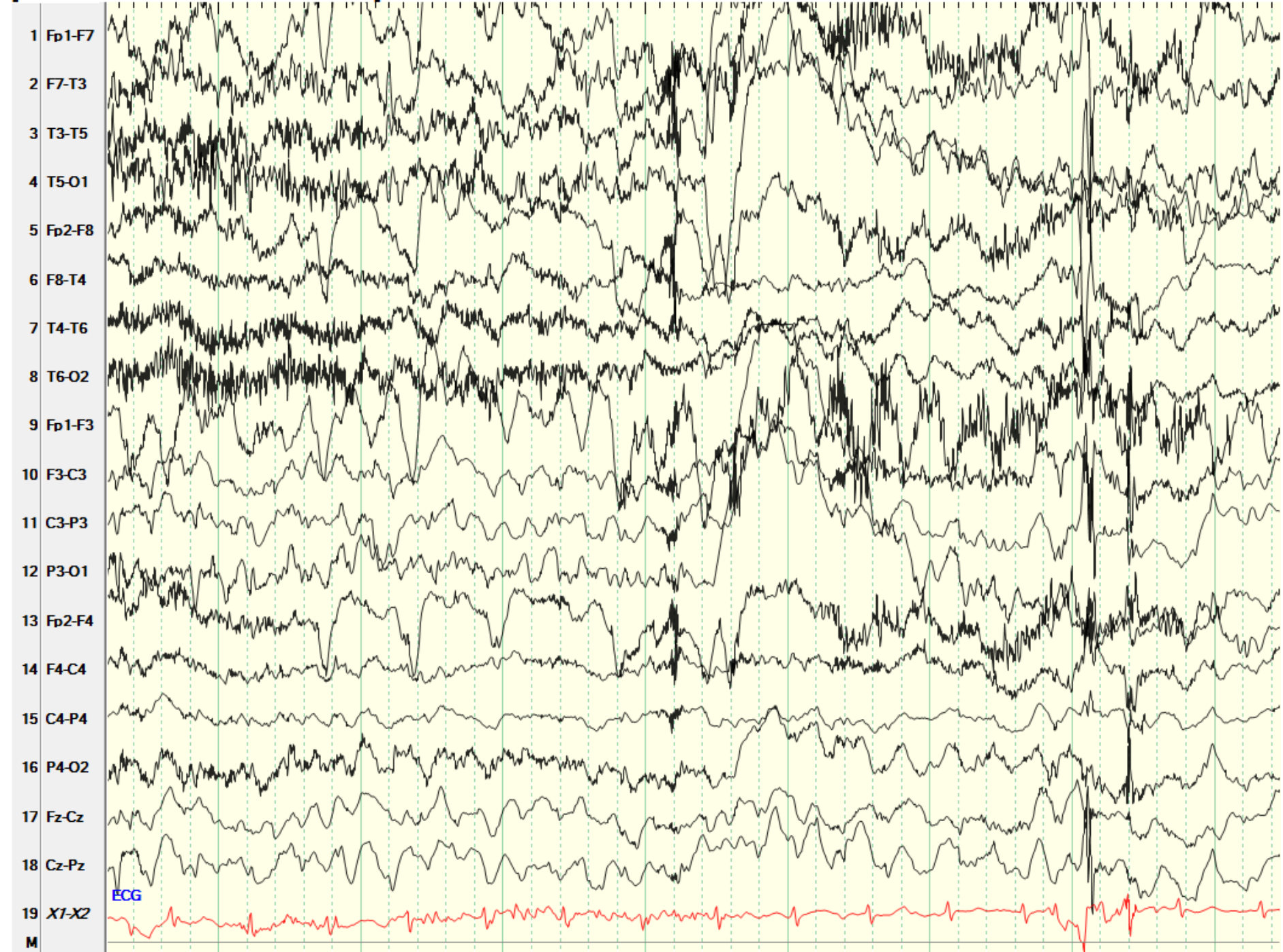


[SENS 7 HF 70 LF 0.53 CAL 50]

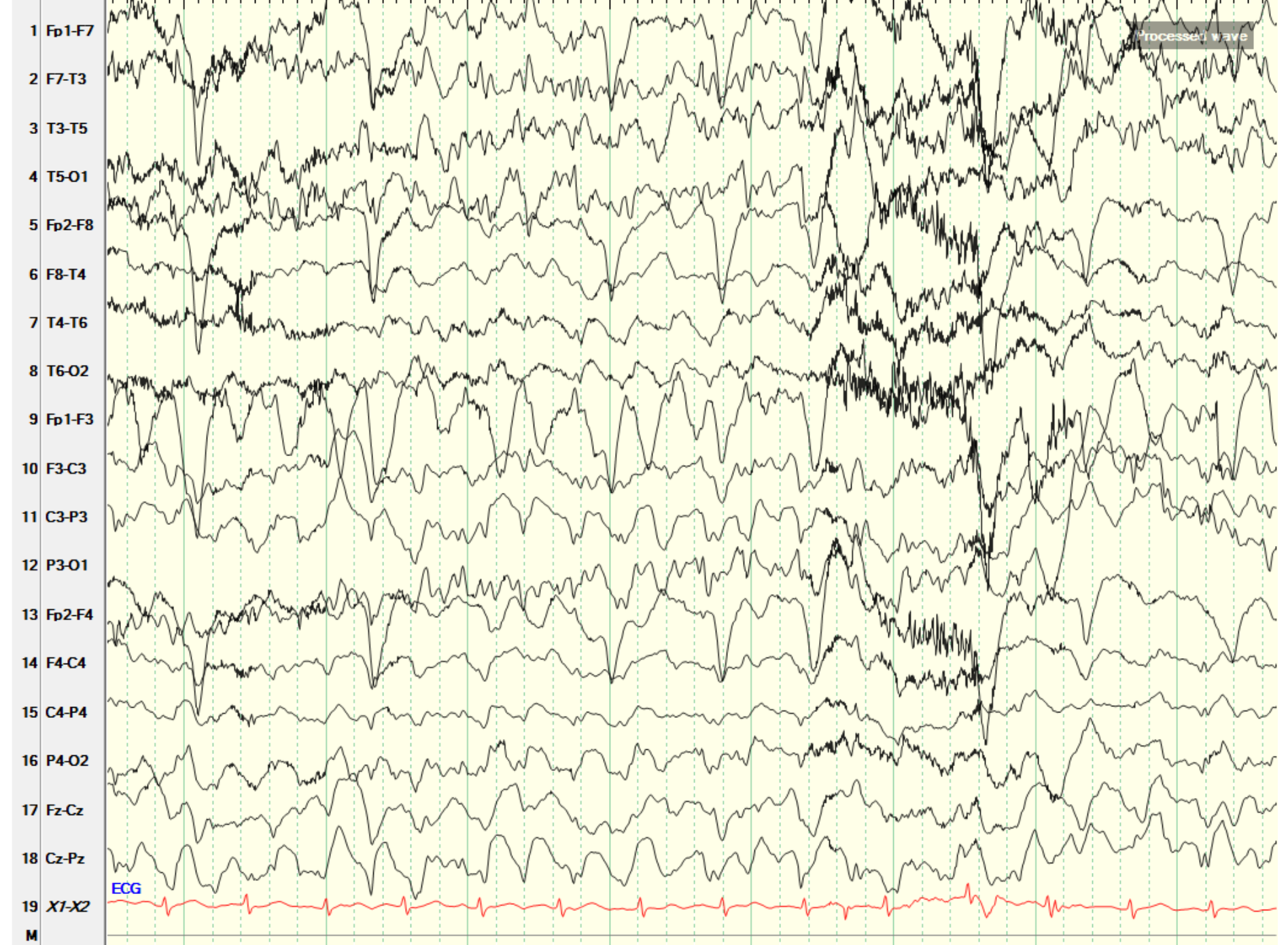

M

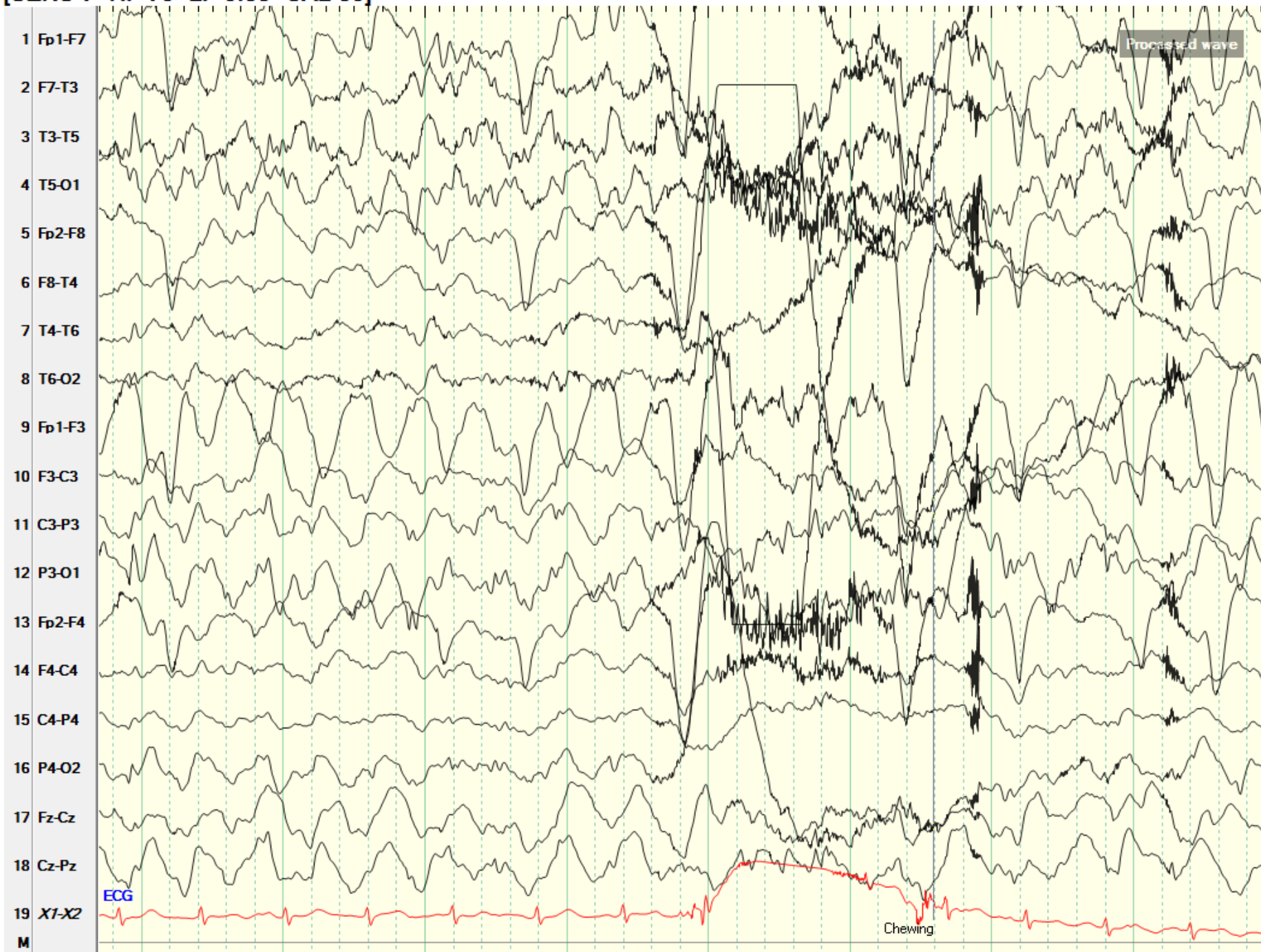
[SENS 7 HF 70 LF 0.53 CAL 50]



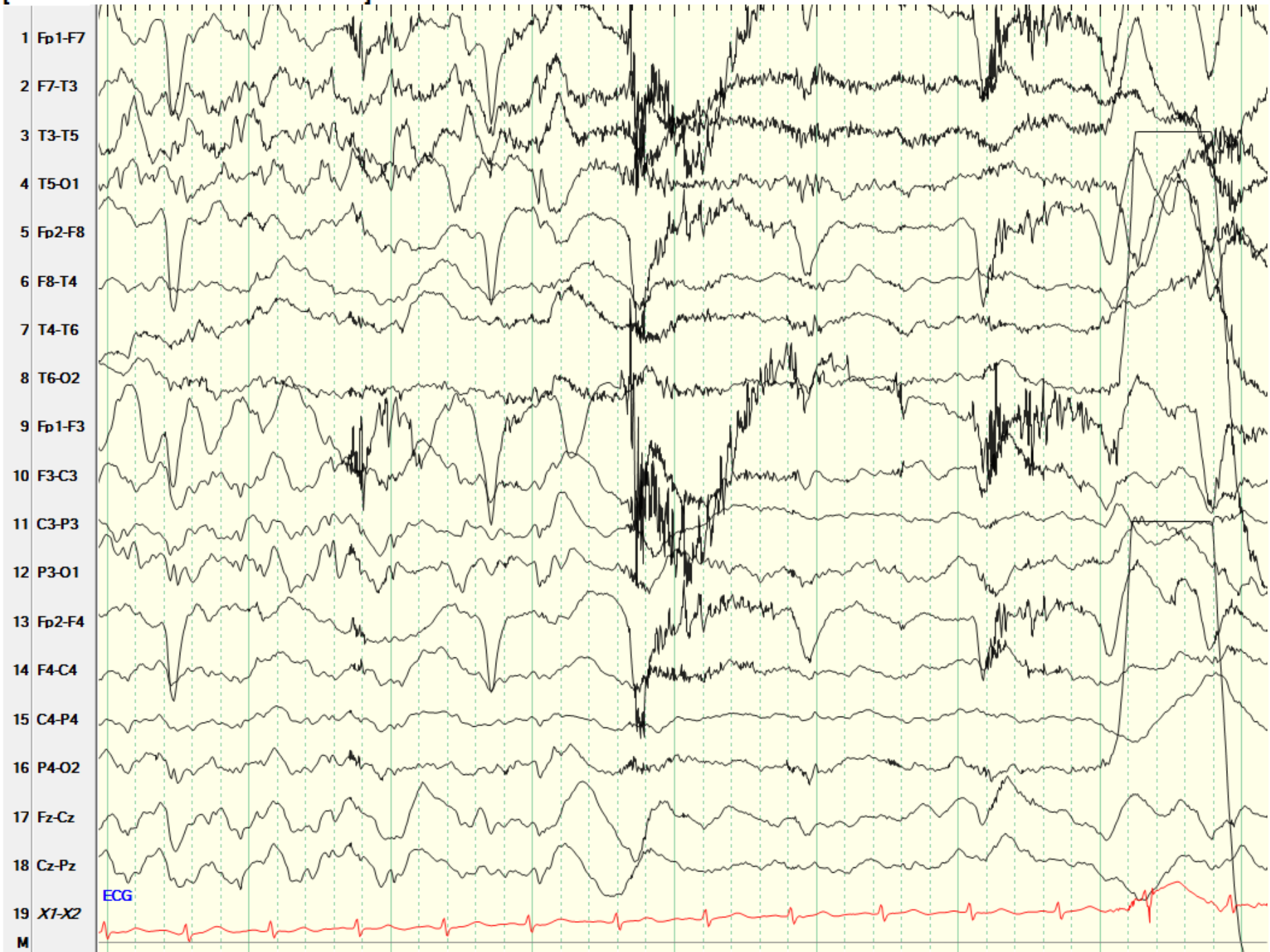
[SENS 7 HF 70 LF 0.53 CAL 50]



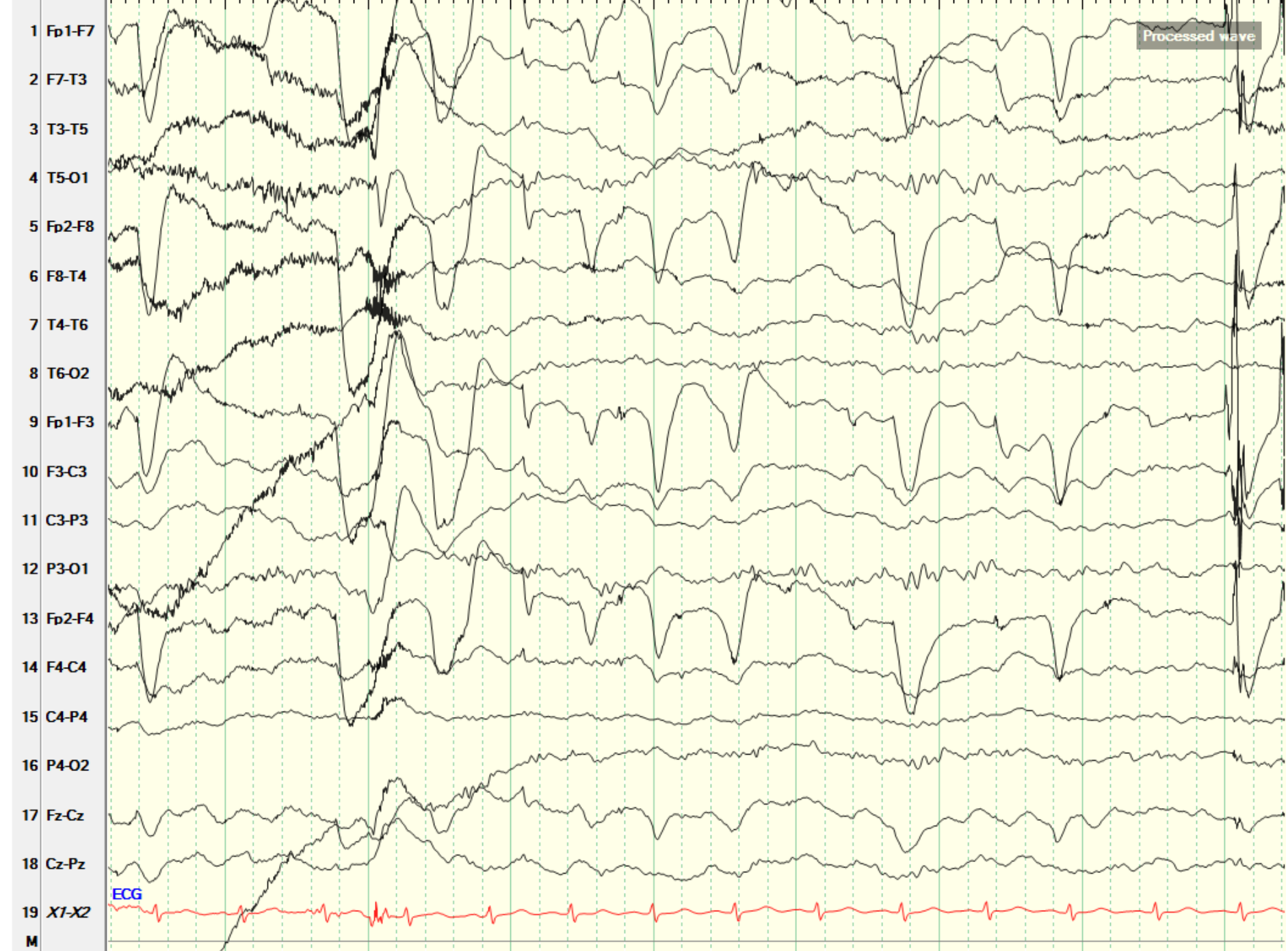
[SENS 7 HF 70 LF 0.53 CAL 50]



[SENS 7 HF 70 LF 0.53 CAL 50]



[SENS 7 HF 70 LF 0.53 CAL 50]



Case#2: mesial temporal sclerosis

- A 40+ yo right-handed male with past medical history of left mesial temporal sclerosis who is referred here for presurgical evaluation. Seizure began at the age of 15.

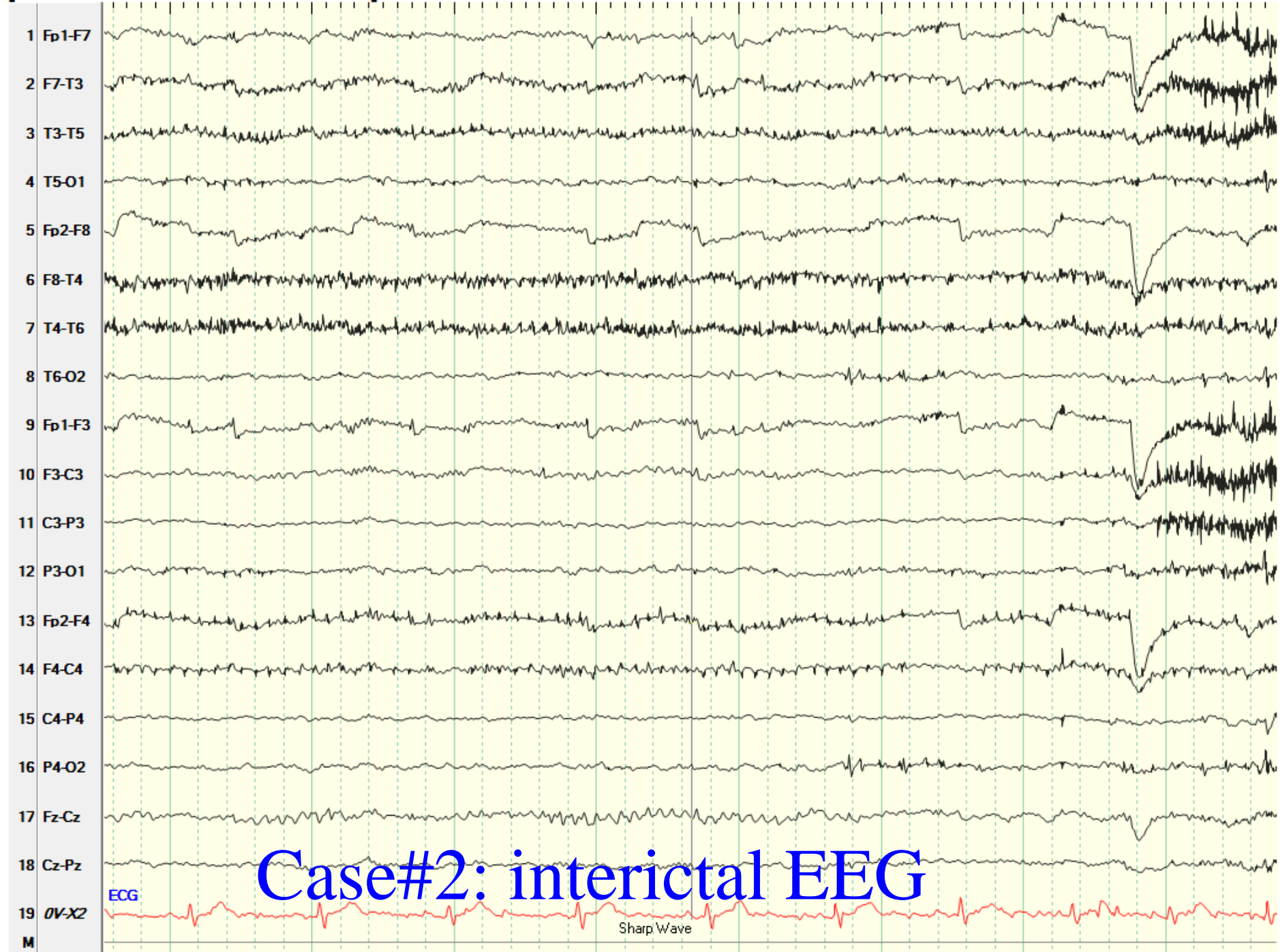
Seizure type 1: eye staring and loss of awareness

Seizure frequency: 10 per months

Seizure type 2: GTCs

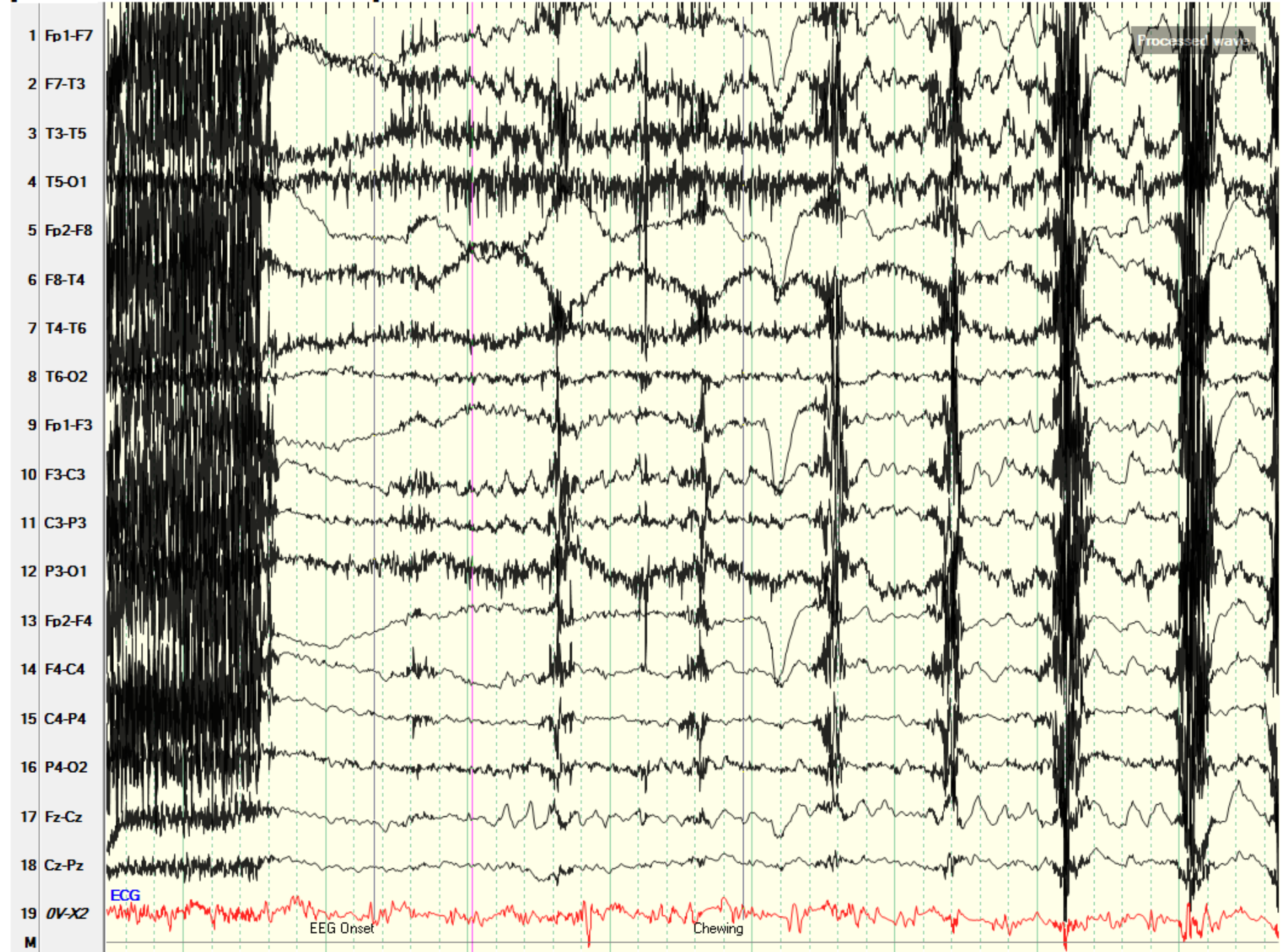
Seizure frequency: 5 per months

Current meds: depakine, lamotrigine, lacosamide, clonazepam

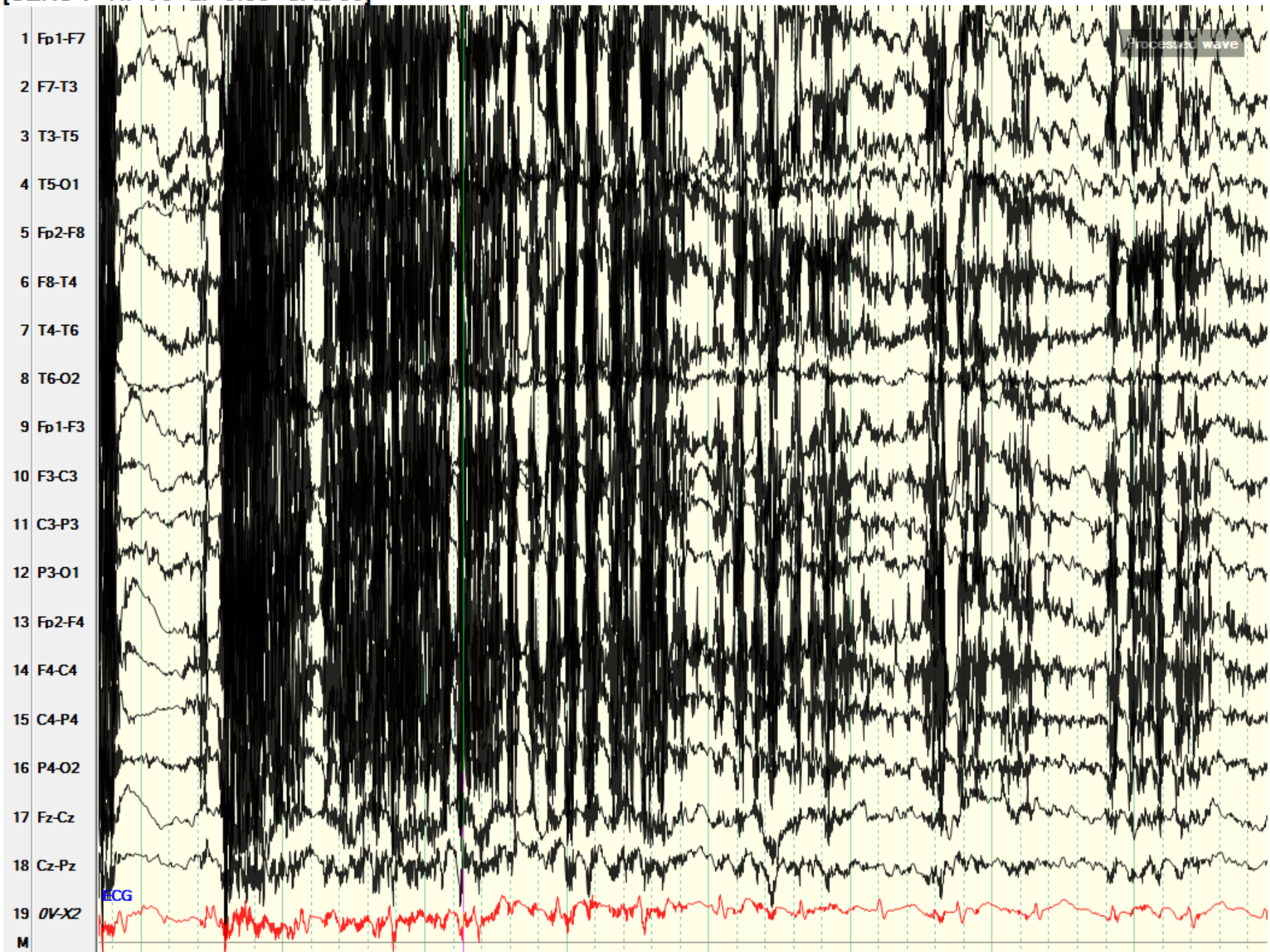


Case#2: interictal EEG

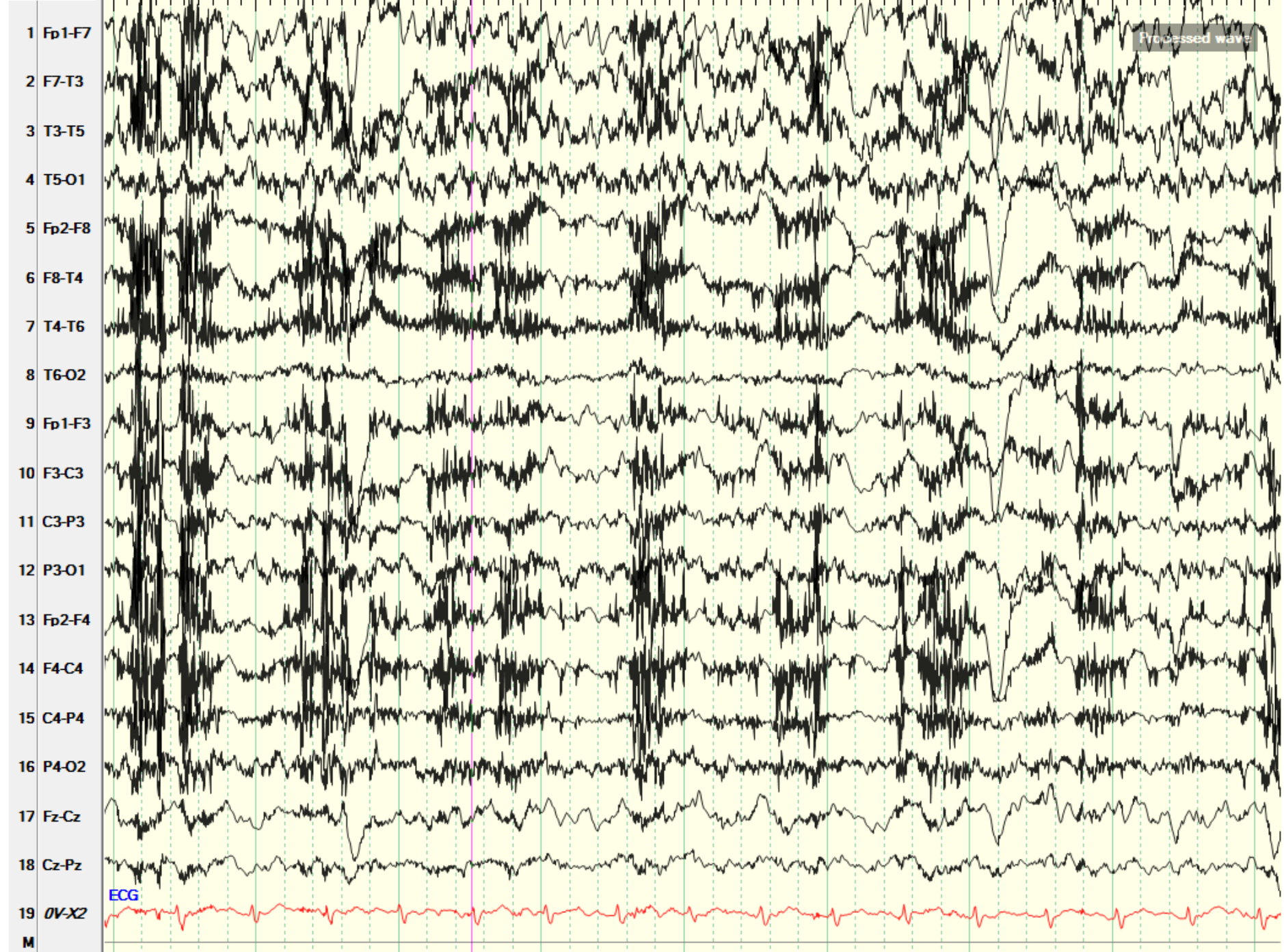
[SENS 7 HF 70 LF 0.53 CAL 50]



[SENS 7 HF 70 LF 0.53 CAL 50]

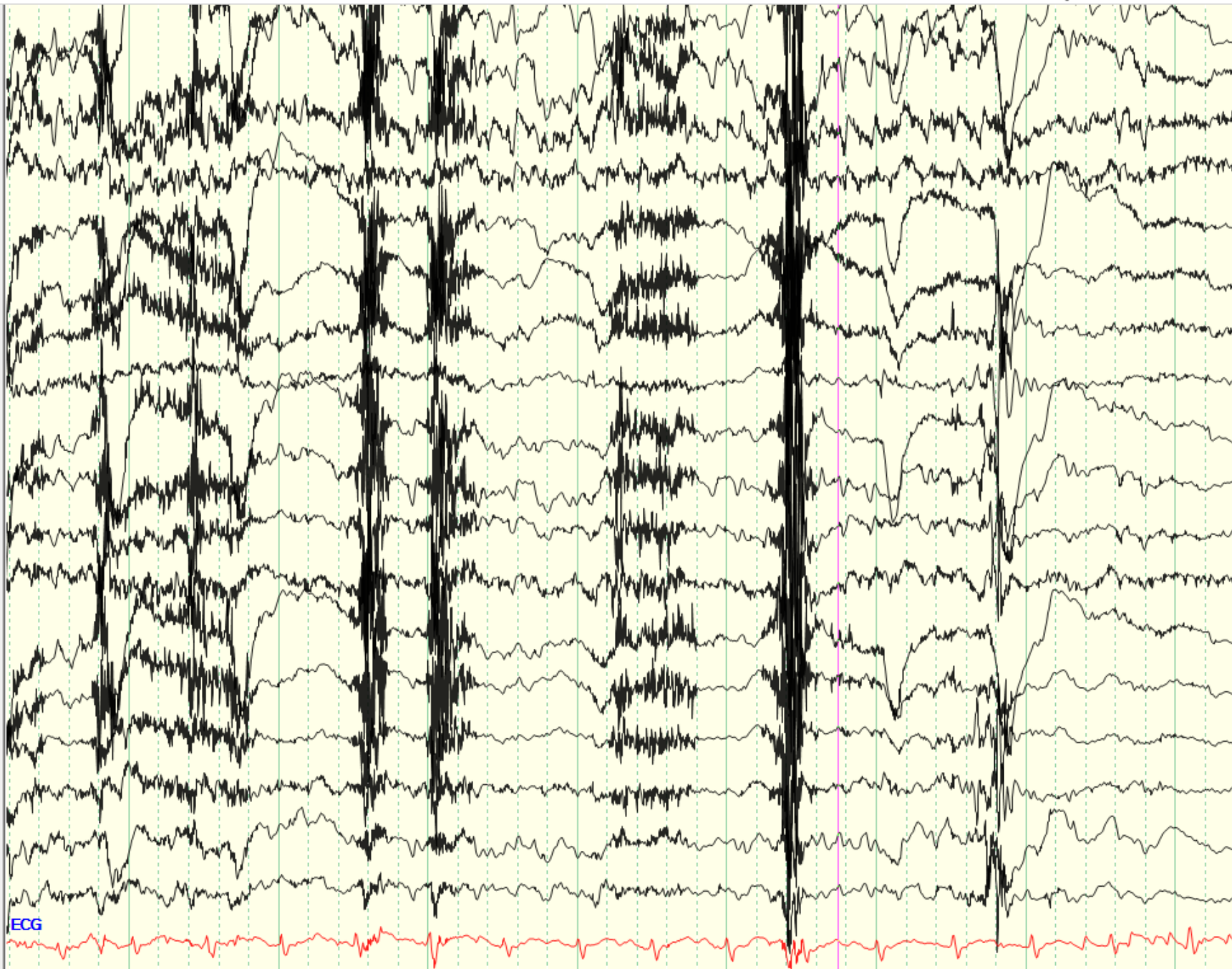


[SENS 7 HF 70 LF 0.53 CAL 50]

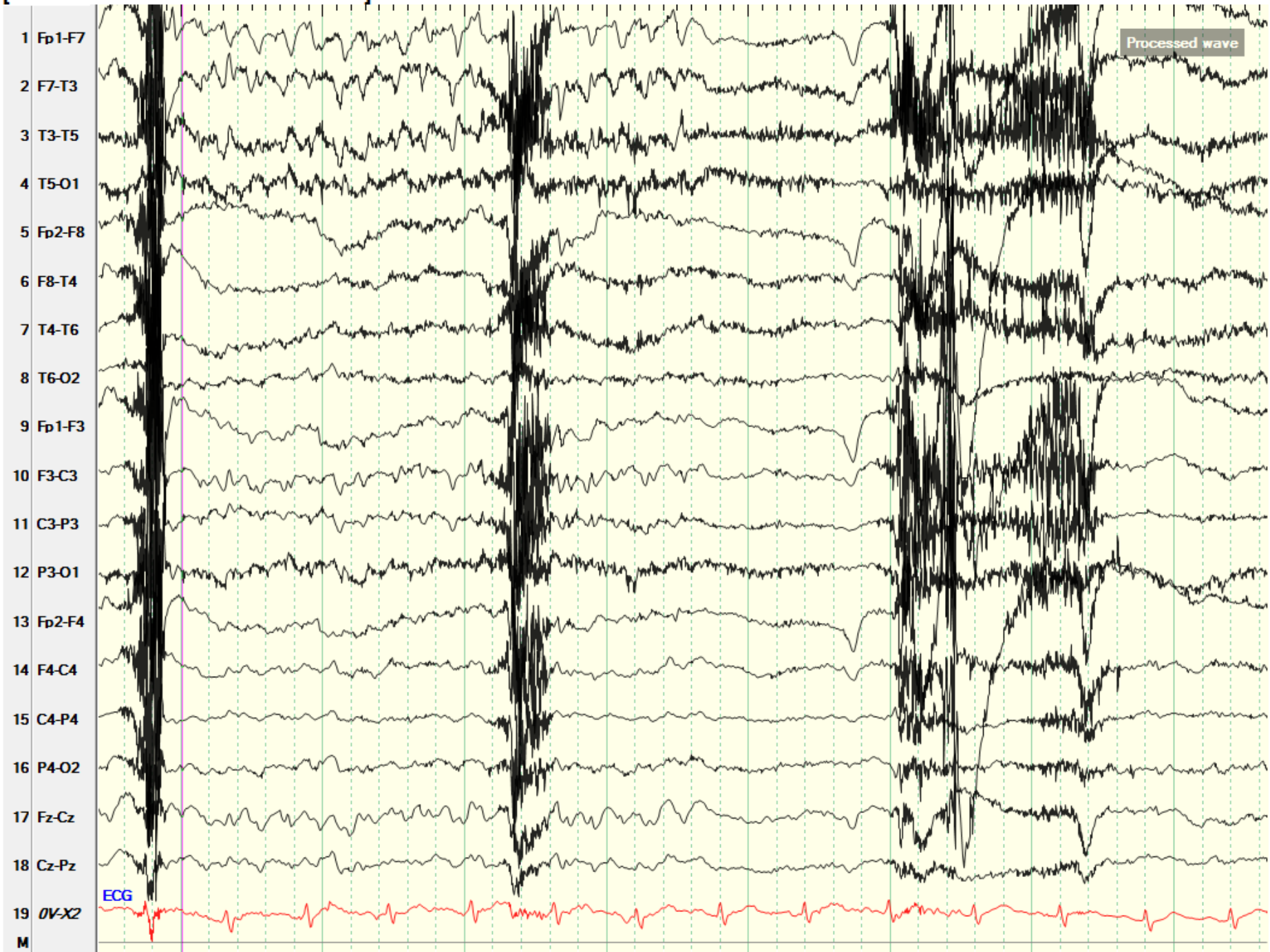


M

- 1 Fp1-F7
- 2 F7-T3
- 3 T3-T5
- 4 T5-O1
- 5 Fp2-F8
- 6 F8-T4
- 7 T4-T6
- 8 T6-O2
- 9 Fp1-F3
- 10 F3-C3
- 11 C3-P3
- 12 P3-O1
- 13 Fp2-F4
- 14 F4-C4
- 15 C4-P4
- 16 P4-O2
- 17 Fz-Cz
- 18 Cz-Pz
- 19 **ECG** 0V-X2
- M



[SENS 7 HF 70 LF 0.53 CAL 50]

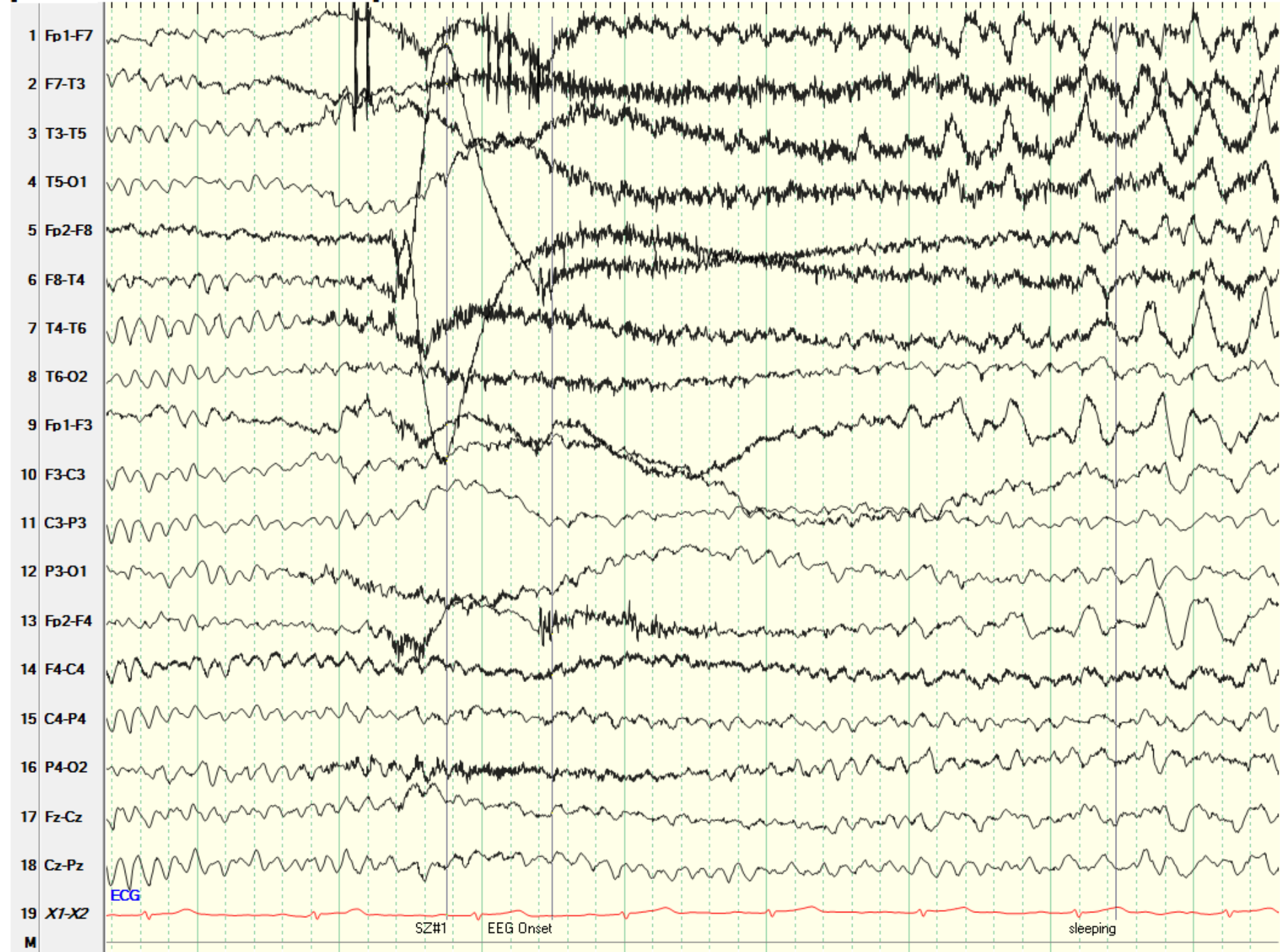


Case#3: neocortical temporal lobe epilepsy

- A 60+ yo right-handed male with drug-resistant epilepsy

Seizure type 1: auditory aura → left versive body turning

[SENS 7 HF 70 LF 0.53 CAL 50]



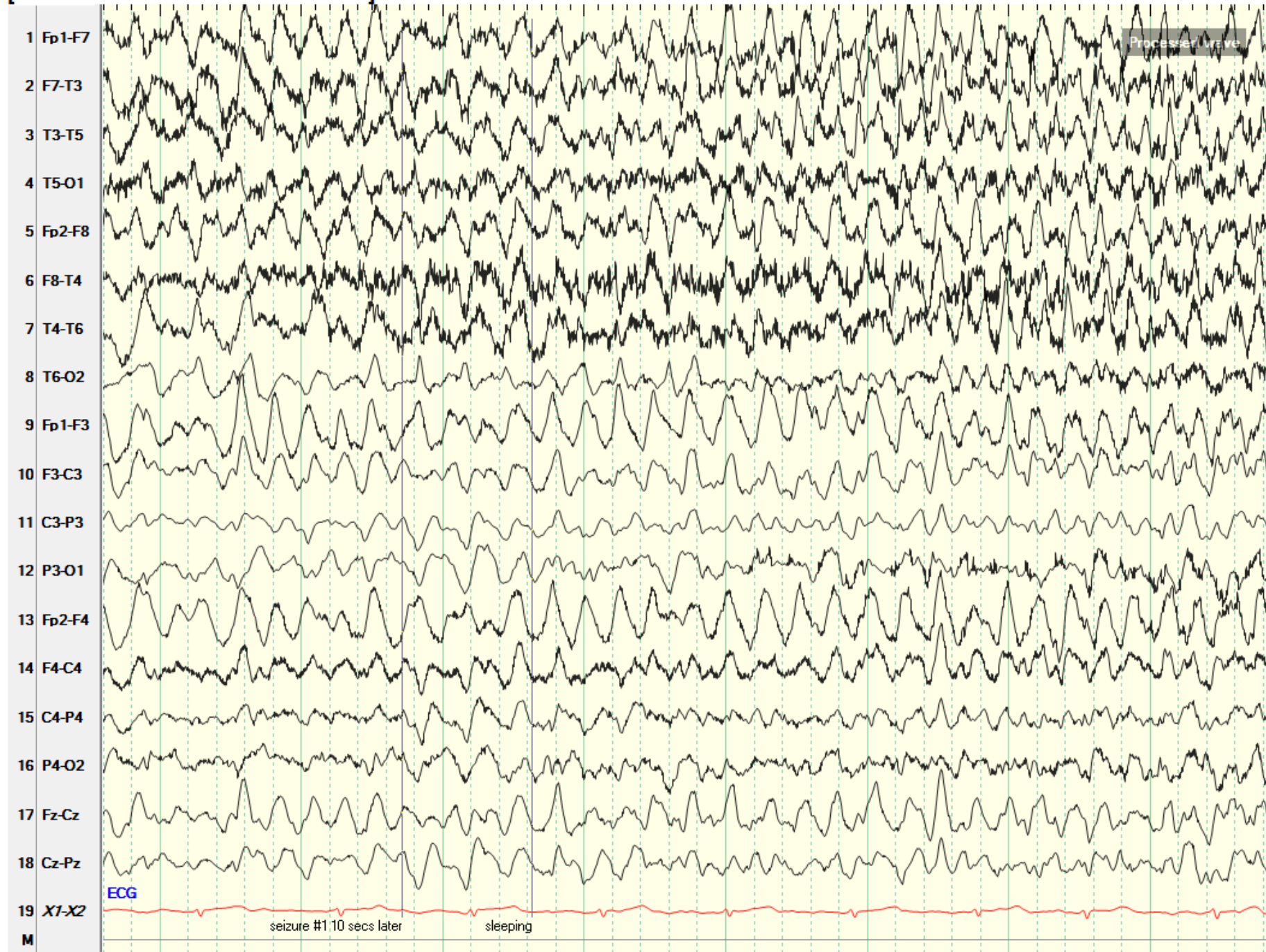
SZ#1

EEG Onset

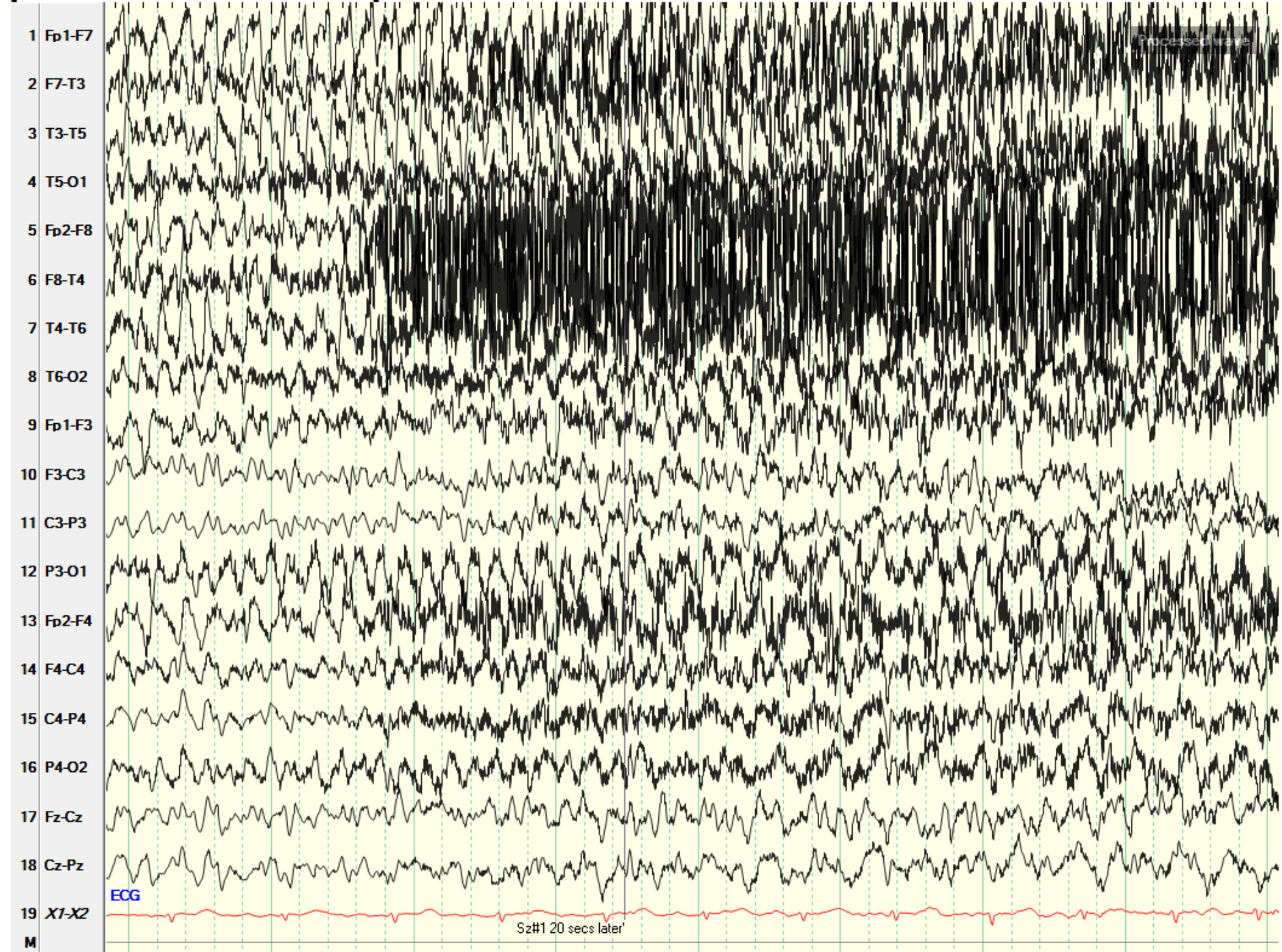
sleeping

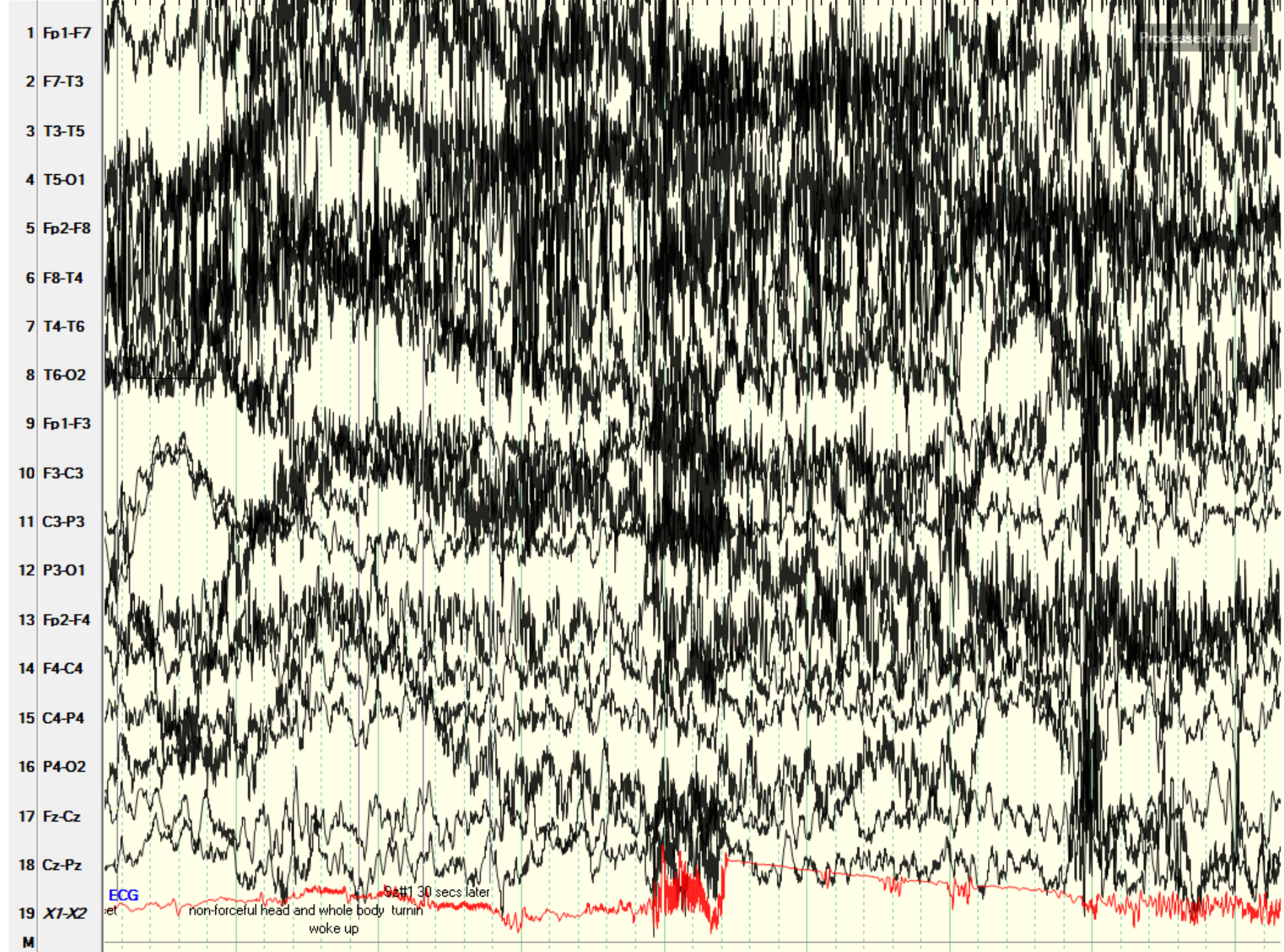
M

[SENS 7 HF 70 LF 0.53 CAL 50]

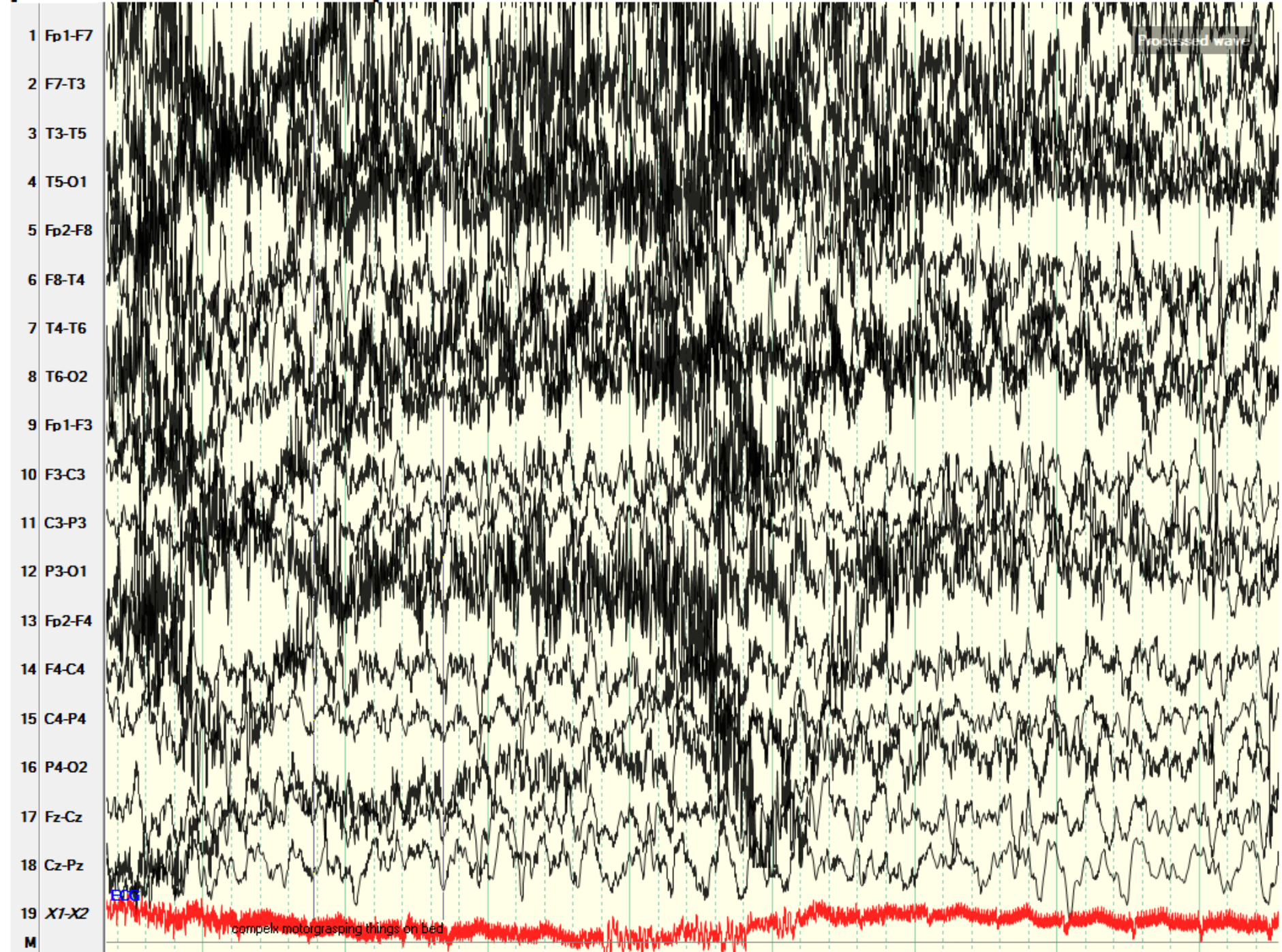


[SENS 7 HF 70 LF 0.53 CAL 50]

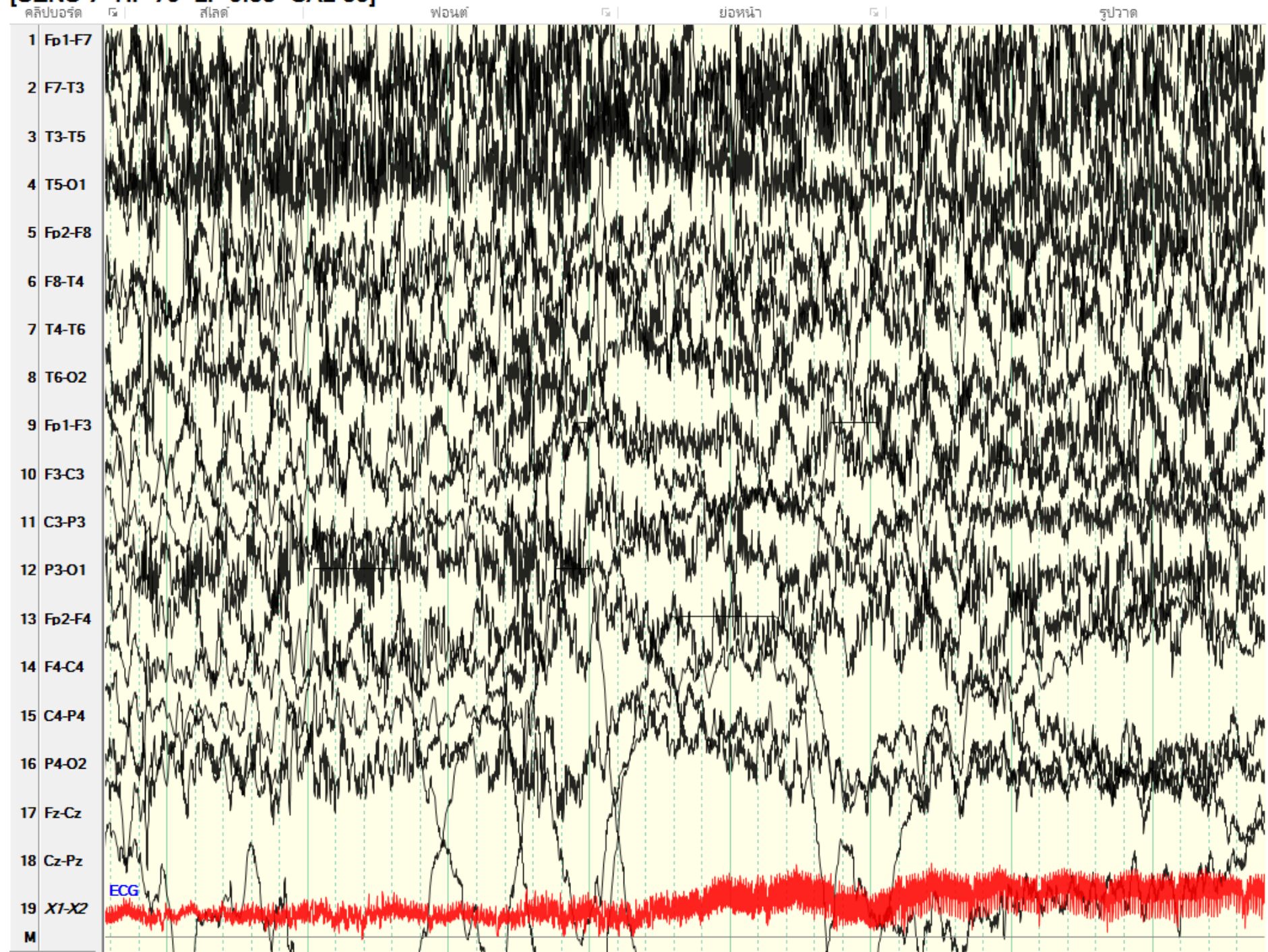




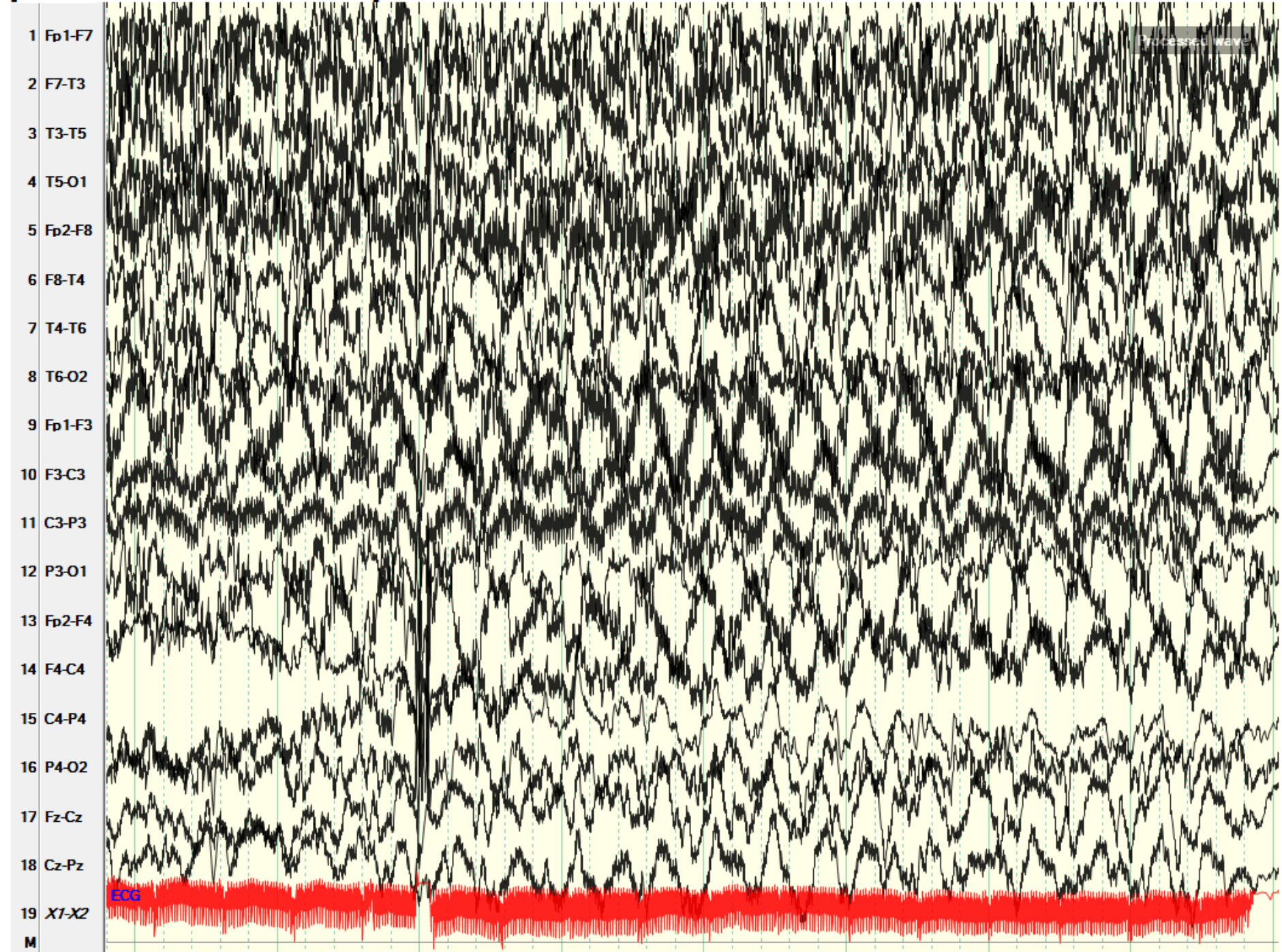
[SENS 7 HF 70 LF 0.53 CAL 50]



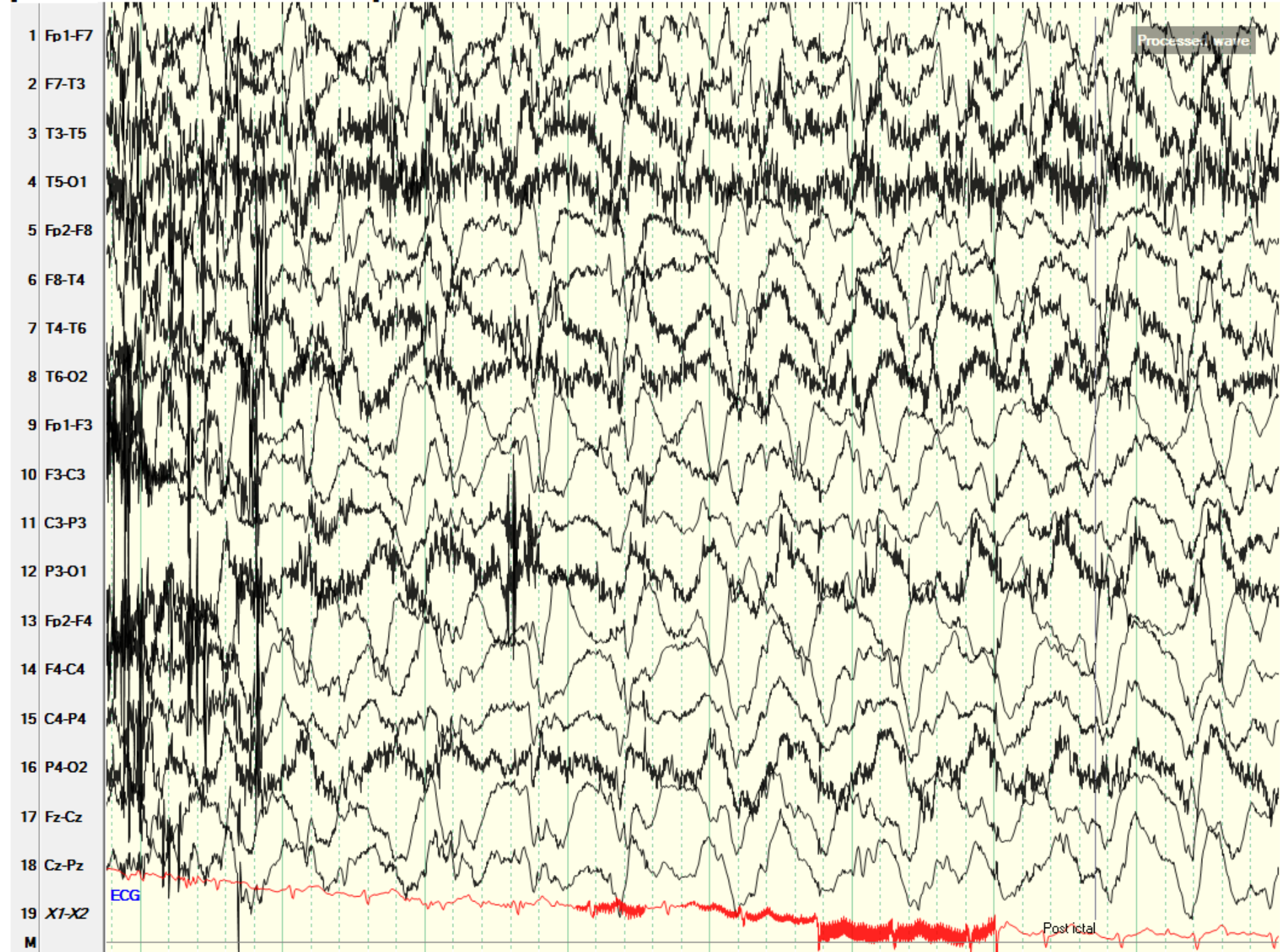
[SENS 7 HF 70 LF 0.53 CAL 50]



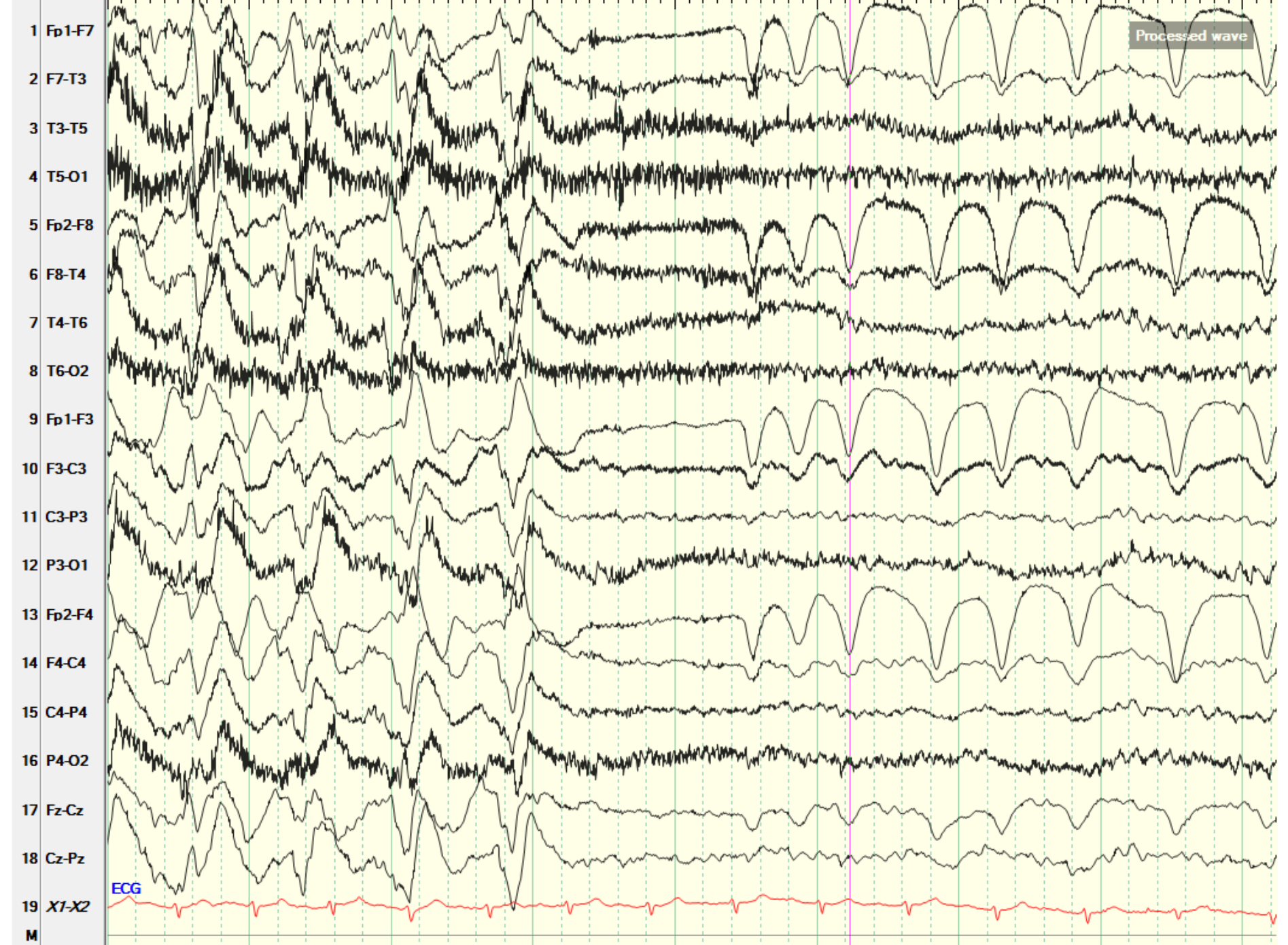[SENS 7 HF 70 LF 0.53 CAL 50]



[SENS 7 HF 70 LF 0.53 CAL 50]



[SENS 7 HF 70 LF 0.53 CAL 50]



Frontal lobe epilepsy(FLE)

- FLE are typically brief and associated with various motor symptoms.
- The seizure symptomatology associated with FLE varies depending on the location of the seizure onset zone within the frontal lobe.
- The postictal period is often characterized by a quick return to normal cognition.

Ictal EEG in frontal lobe epilepsy

- Lateral frontal epilepsies
- Mesial frontal epilepsies
- Orbitofrontal epilepsies

Case#4

- A 28 yo female with frequent seizures during the night

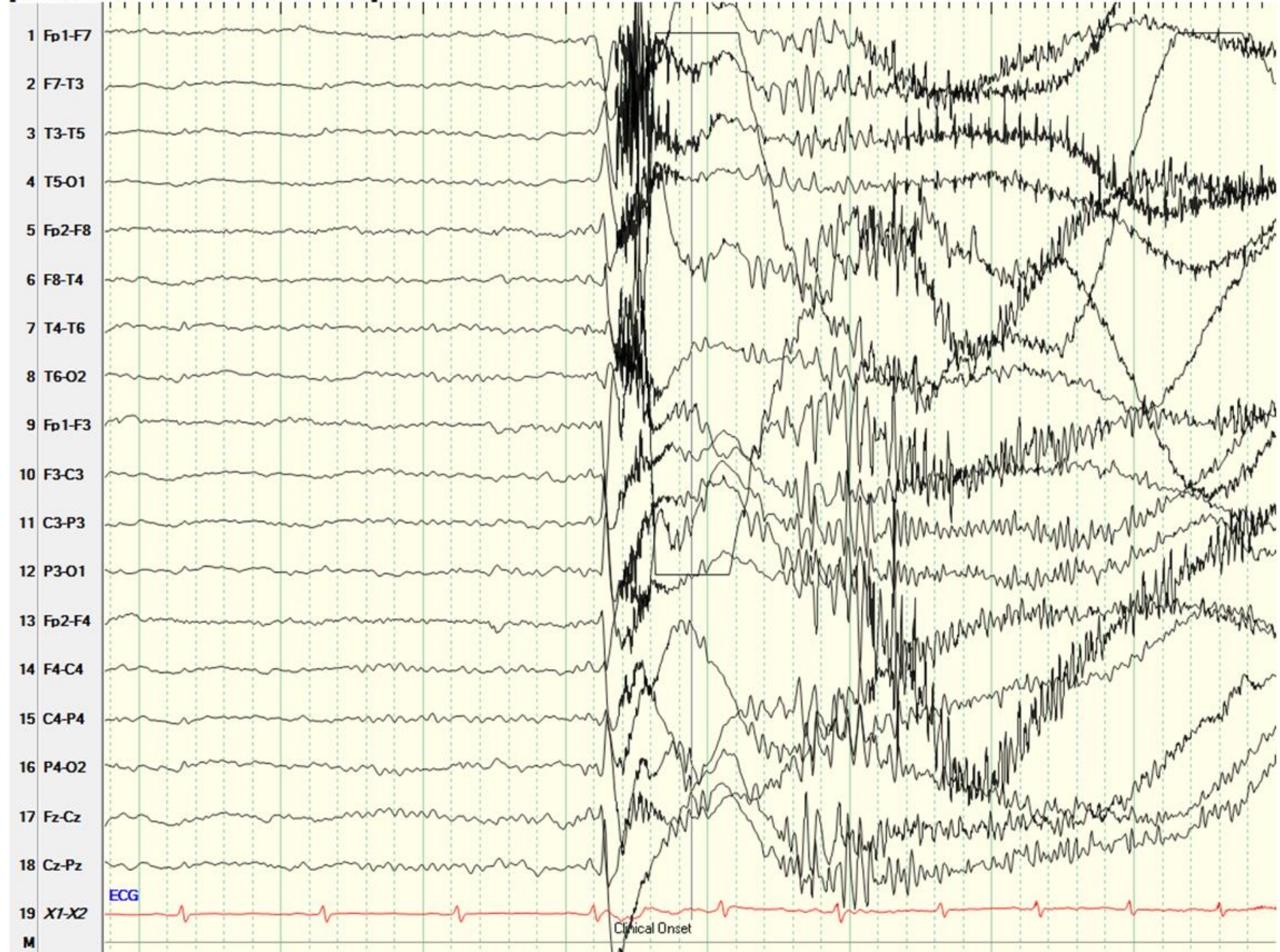
Seizure type1: complex motor movement of all limbs → loss of awareness

Seizure frequency: 1-2 times per night

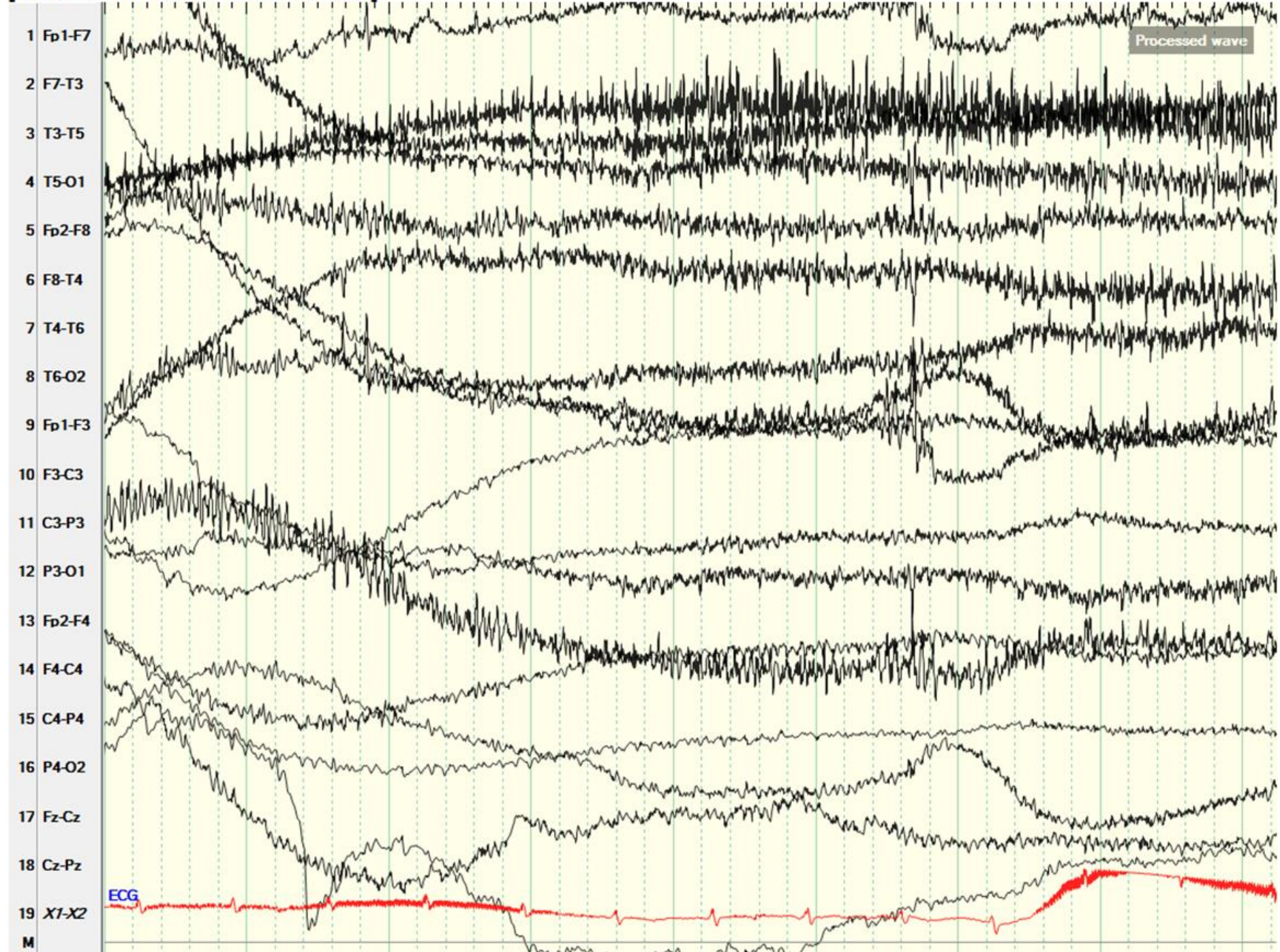
Seizure duration 3-5 seconds

- Past AEDs: PHT, CBZ, VPA, LEV, TPM, LTG
- Presurgical evaluation: Right frontopolar ictal EEG onset → lesionectomy → cortical dysplasia

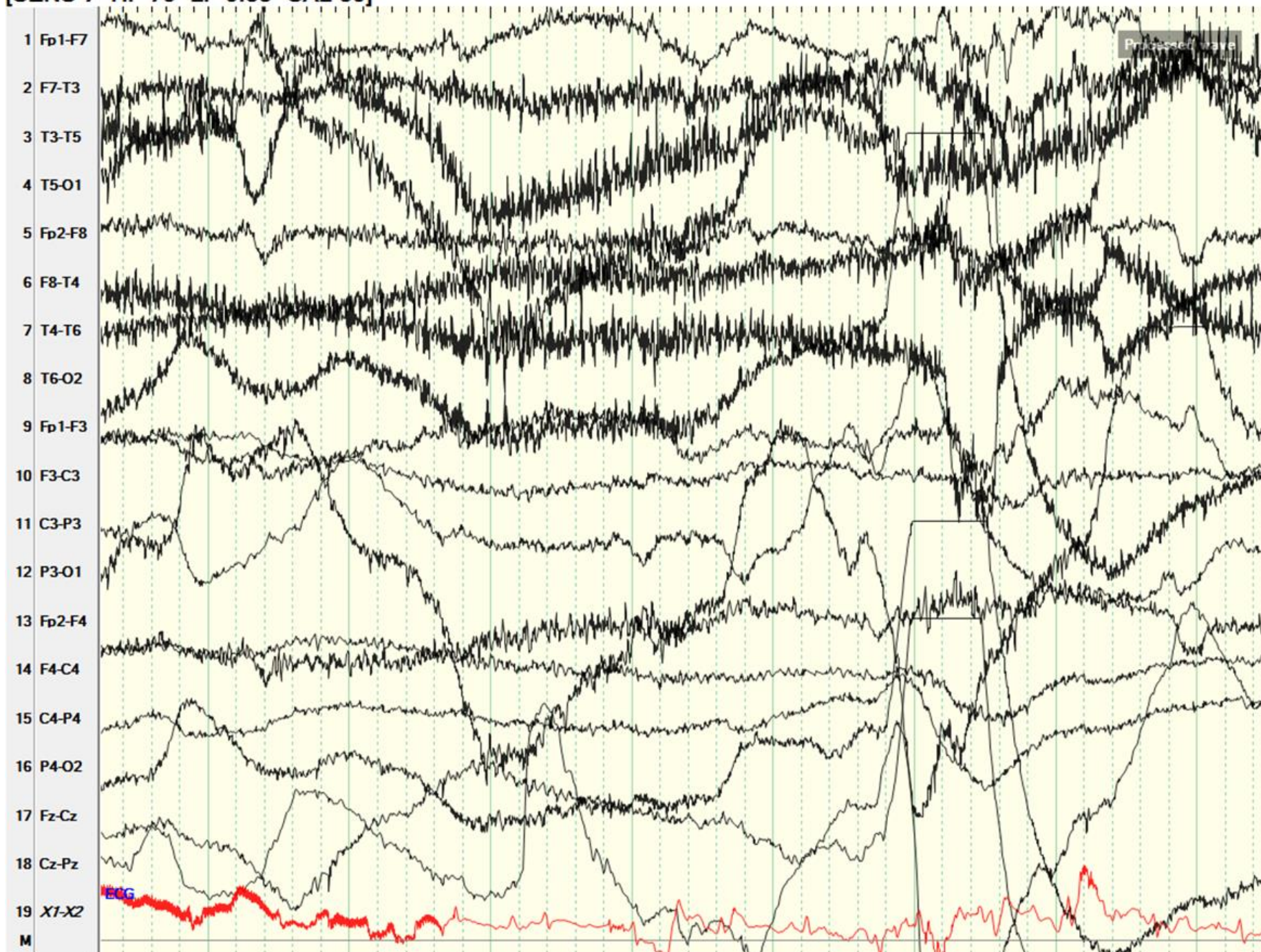
[SENS 7 HF 70 LF 0.53 CAL 50]



[SENS 7 HF 70 LF 0.53 CAL 50]



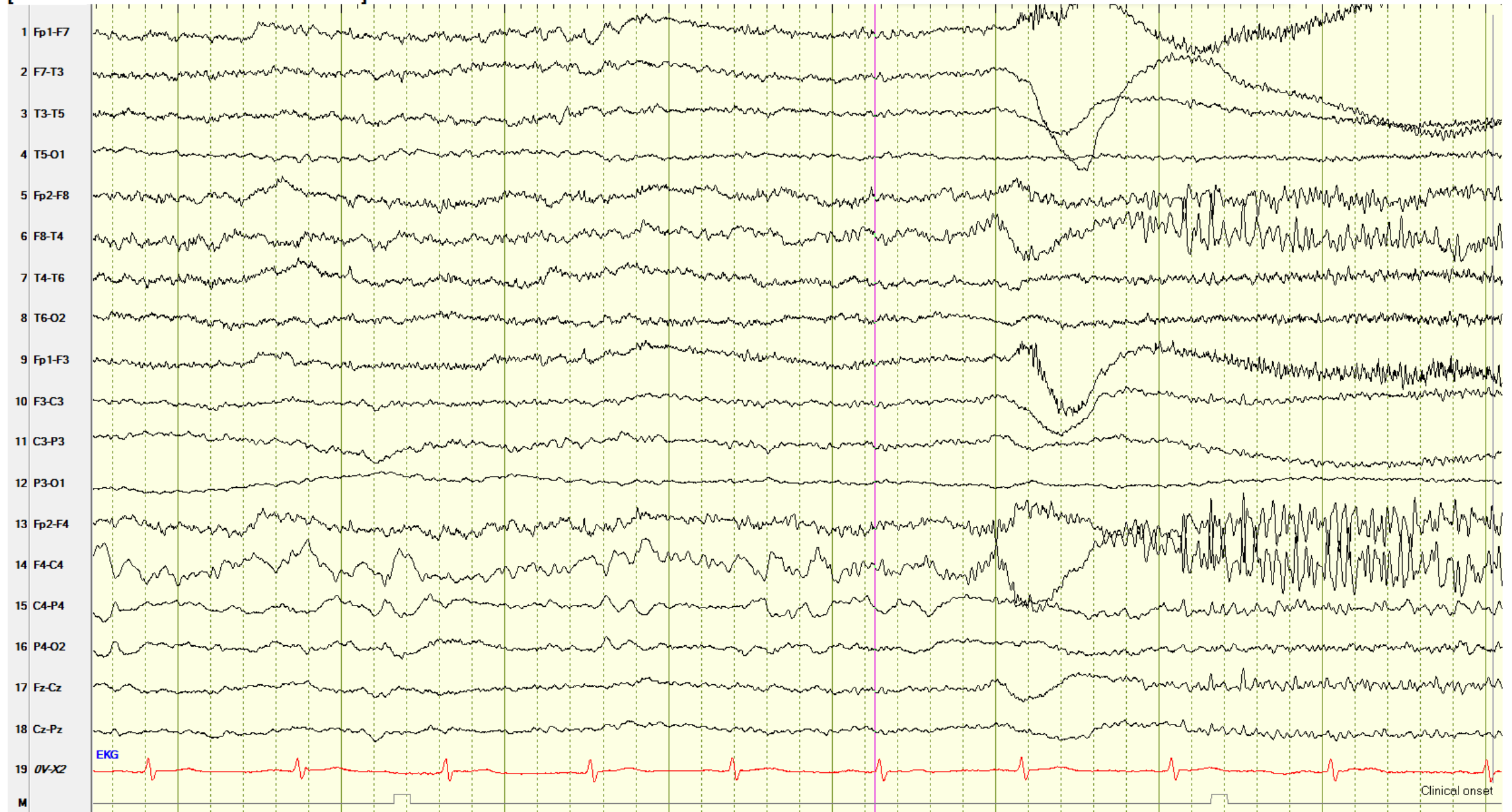
[SENS 7 HF 70 LF 0.53 CAL 50]



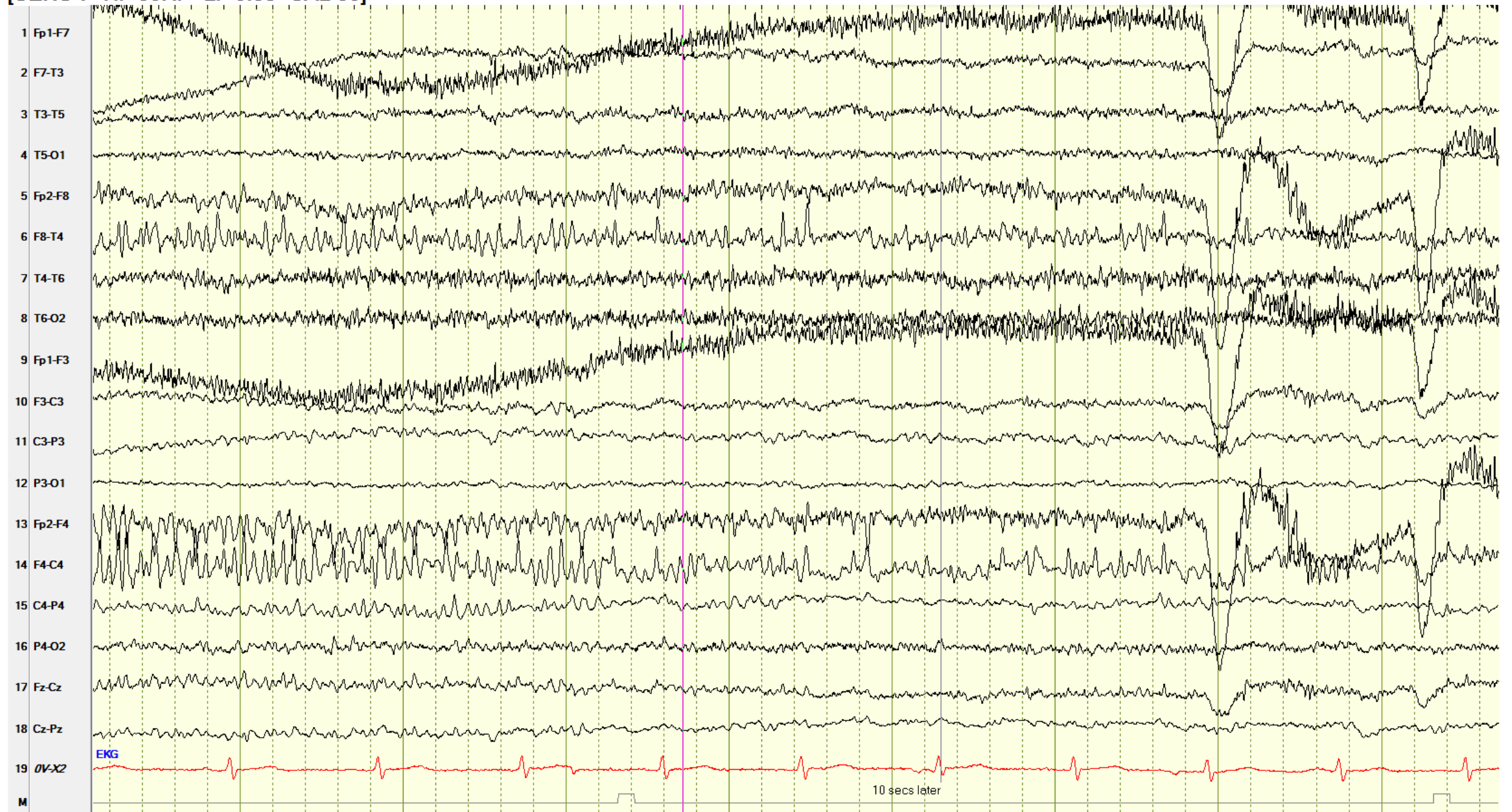
Case#5

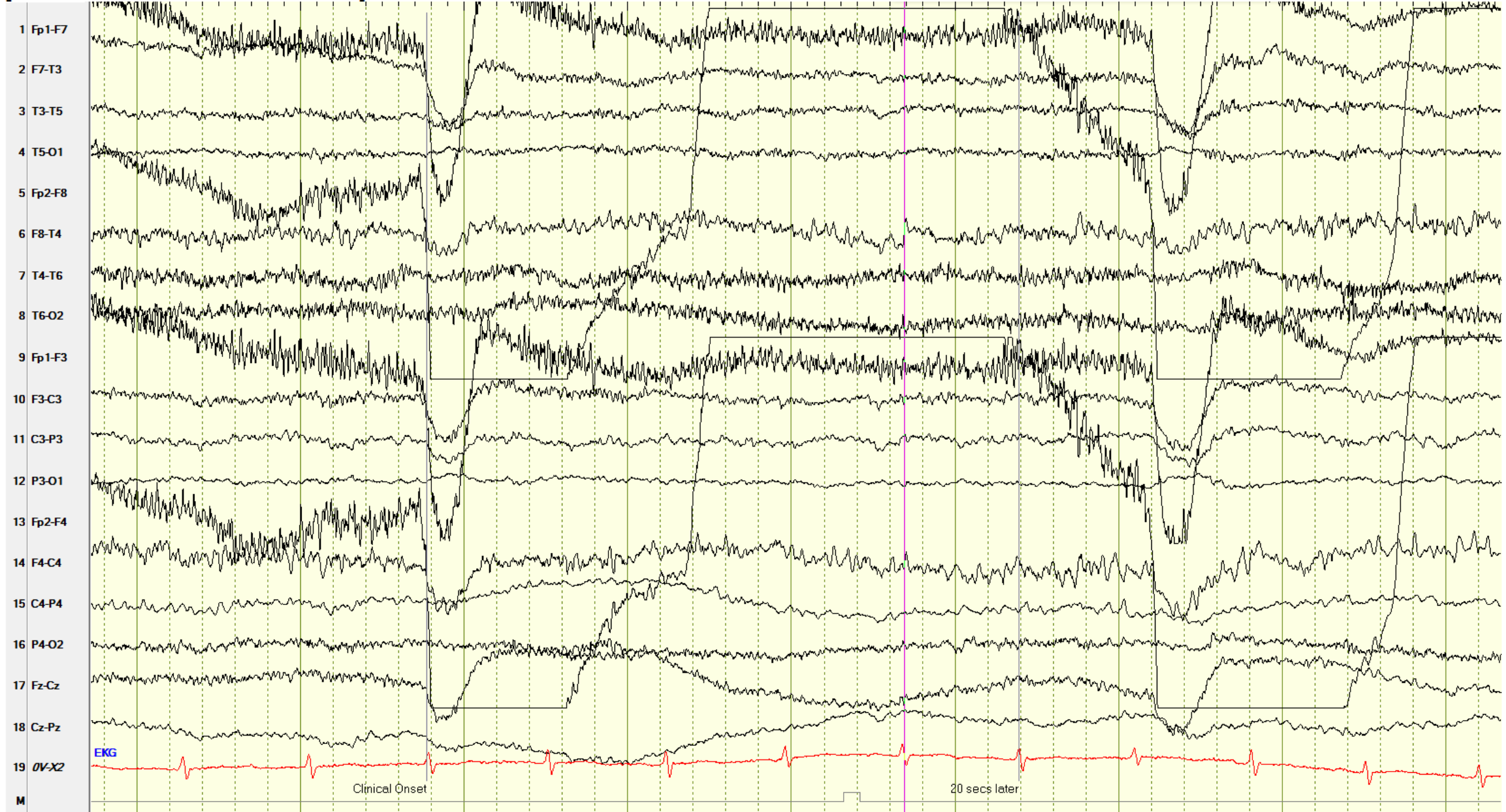
- A 30+yo male with history of posttraumatic epilepsy
 - Seizure type 1: left upper extremity tonic with preserved awareness

[SENS 7 HF 50RP LF 0.53 CAL 50]

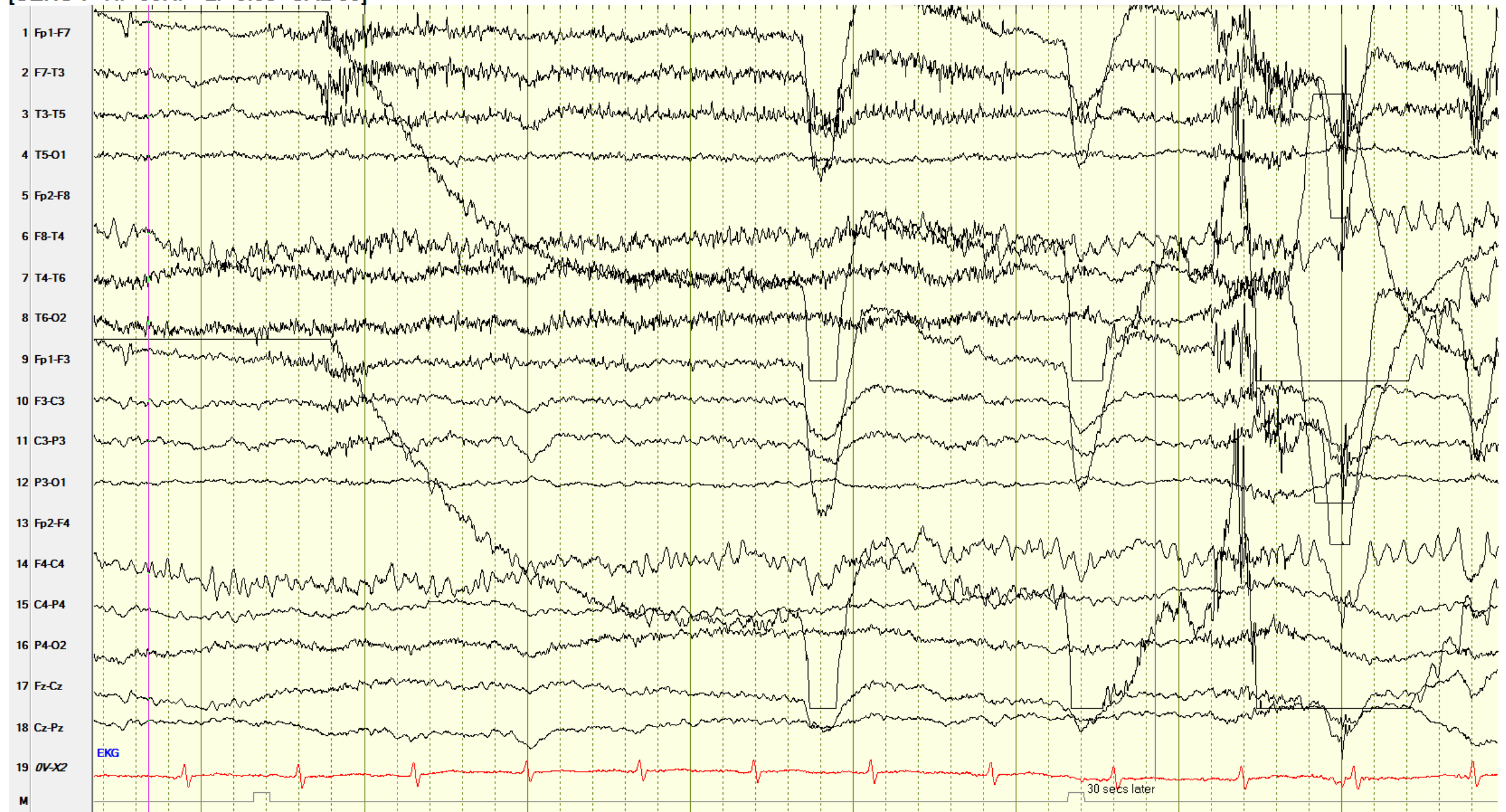


[SENS 7 HF 50RP LF 0.53 CAL 50]



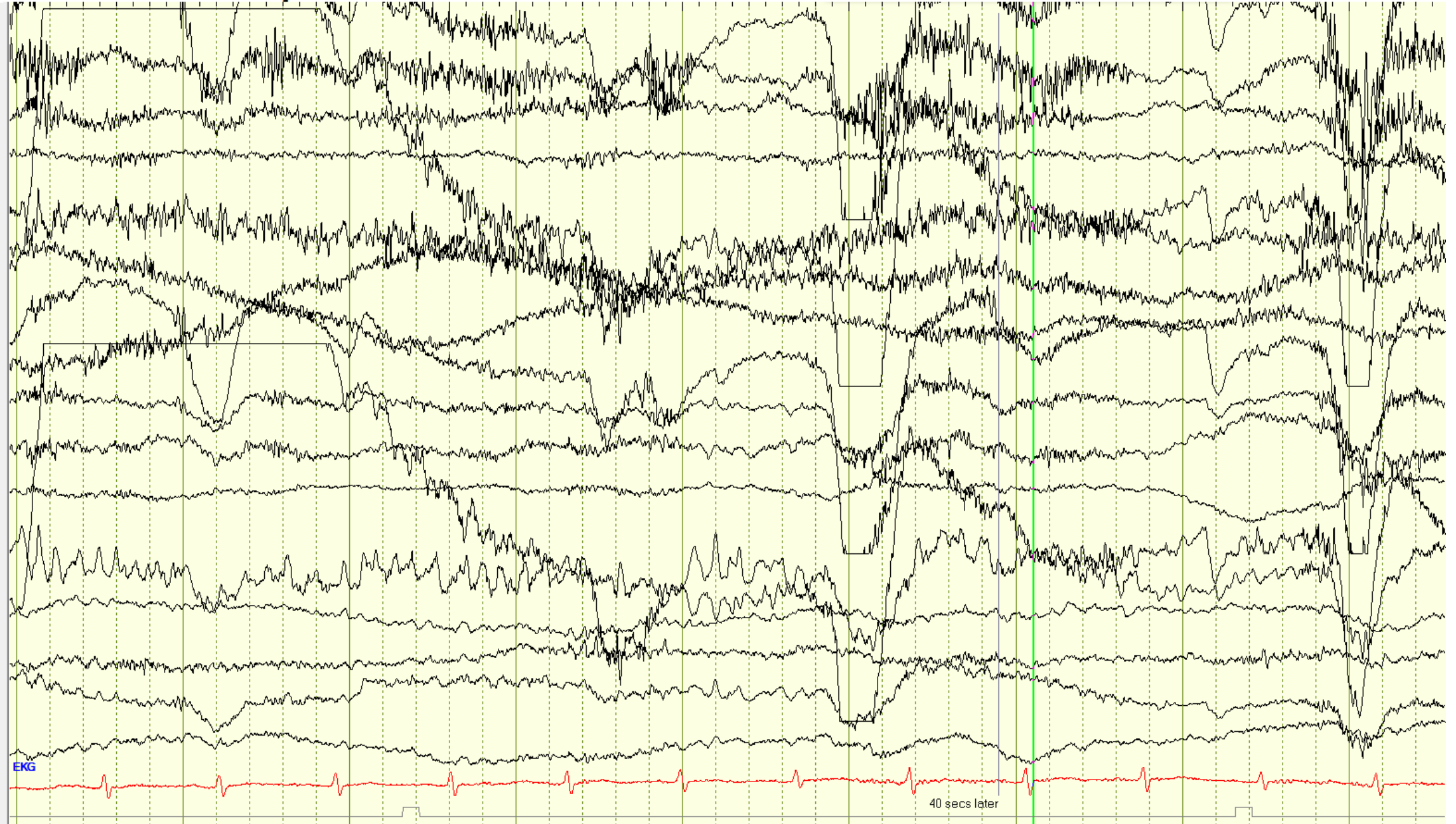


[SENS 7 HF 50RP LF 0.53 CAL 50]



[SENS 7 HF 50RP LF 0.53 CAL 50]

- 1 Fp1-F7
- 2 F7-T3
- 3 T3-T5
- 4 T5-O1
- 5 Fp2-F8
- 6 F8-T4
- 7 T4-T6
- 8 T6-O2
- 9 Fp1-F3
- 10 F3-C3
- 11 C3-P3
- 12 P3-O1
- 13 Fp2-F4
- 14 F4-C4
- 15 C4-P4
- 16 P4-O2
- 17 Fz-Cz
- 18 Cz-Pz
- 19 *OV-X2*



40 secs later

M

Ictal EEG in parietal lobe epilepsy

- No specific pattern of ictal scalp EEG has been described.
- Parietal lobe seizures are rarely localizable on scalp EEG; they can only be lateralized.

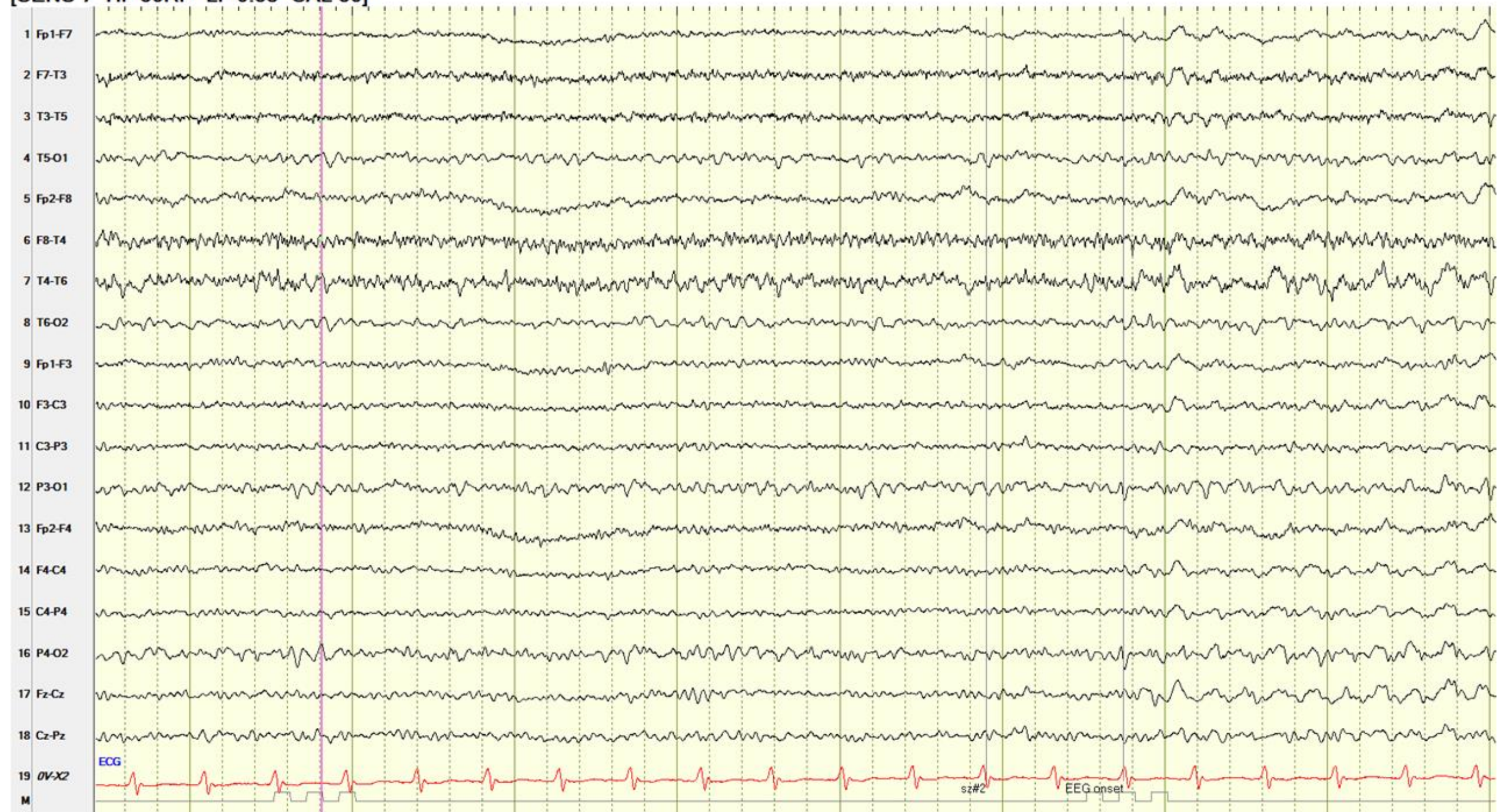
Case#6

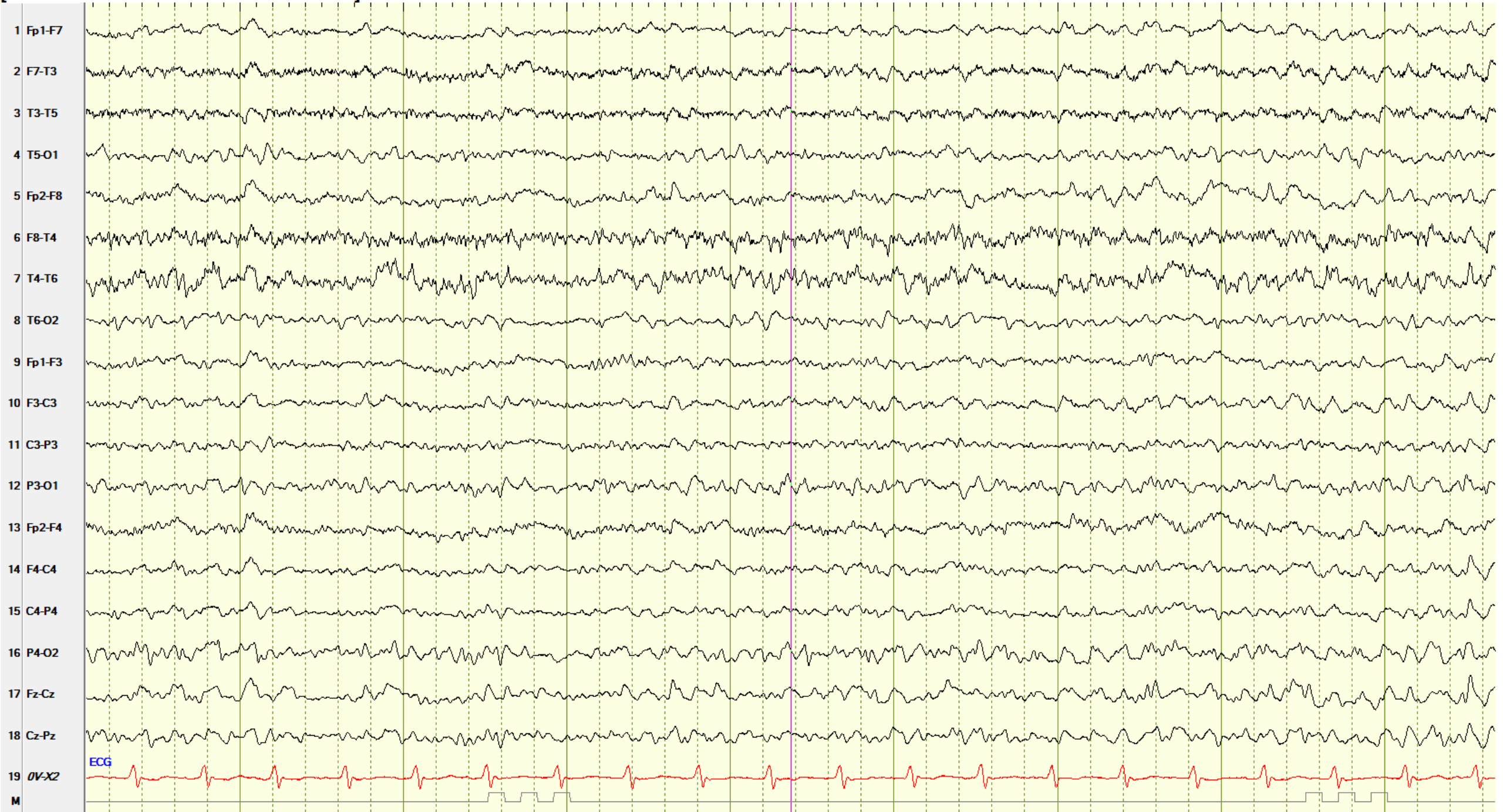
- A 30 yo+ female with drug-resistant epilepsy

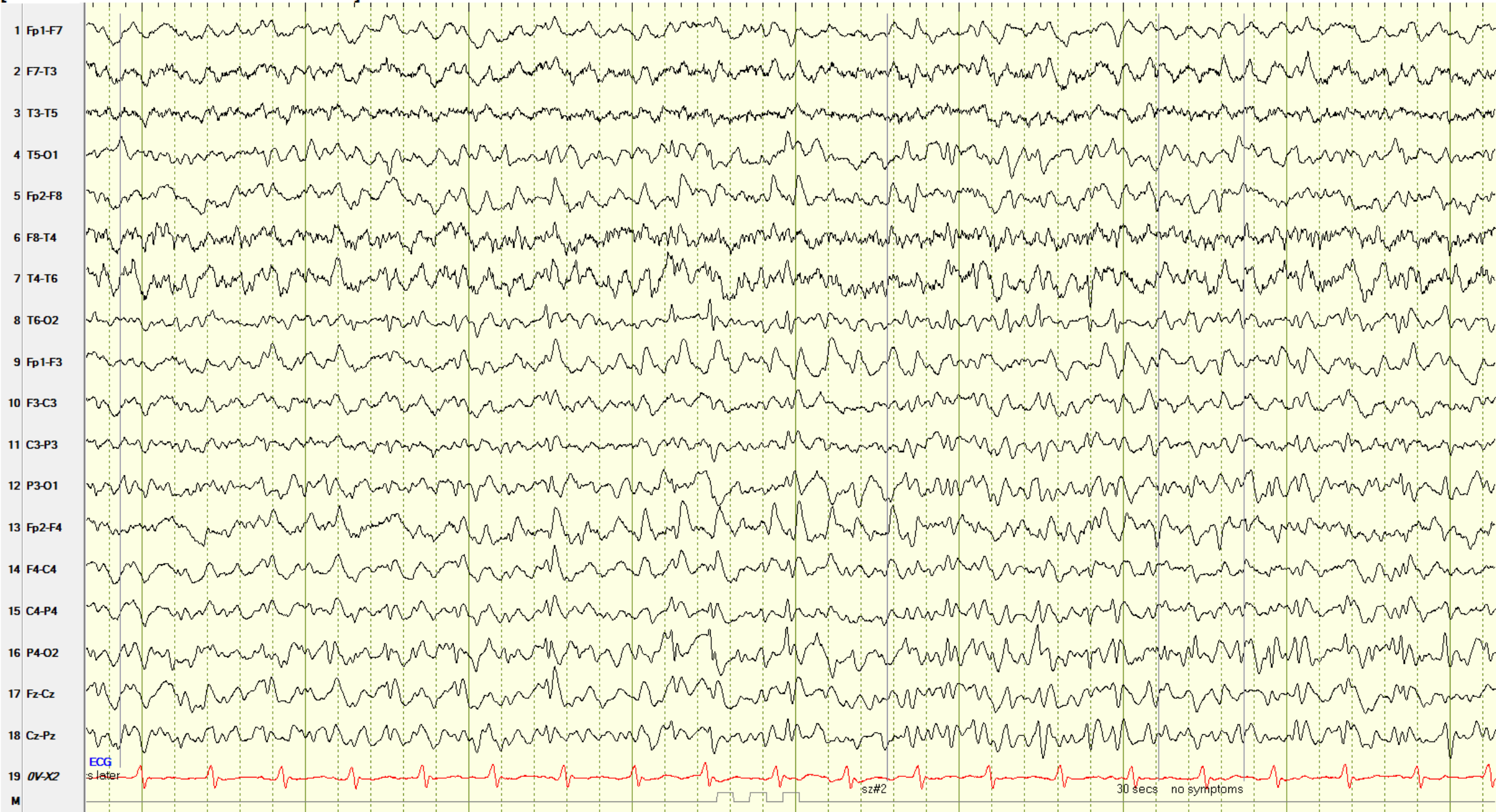
Seizure type 1: GTCs

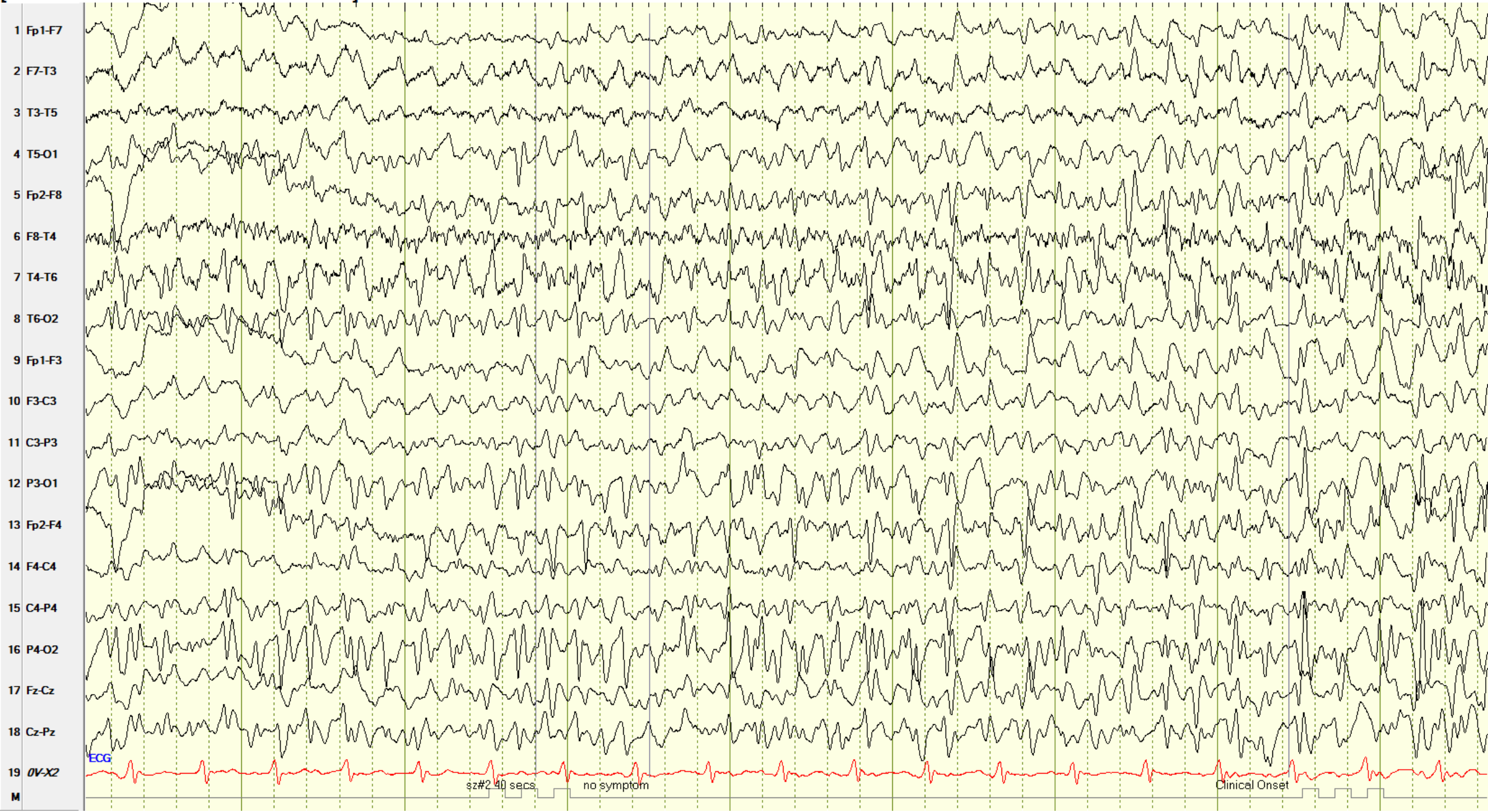
Seizure type 2: EPC of left index finger

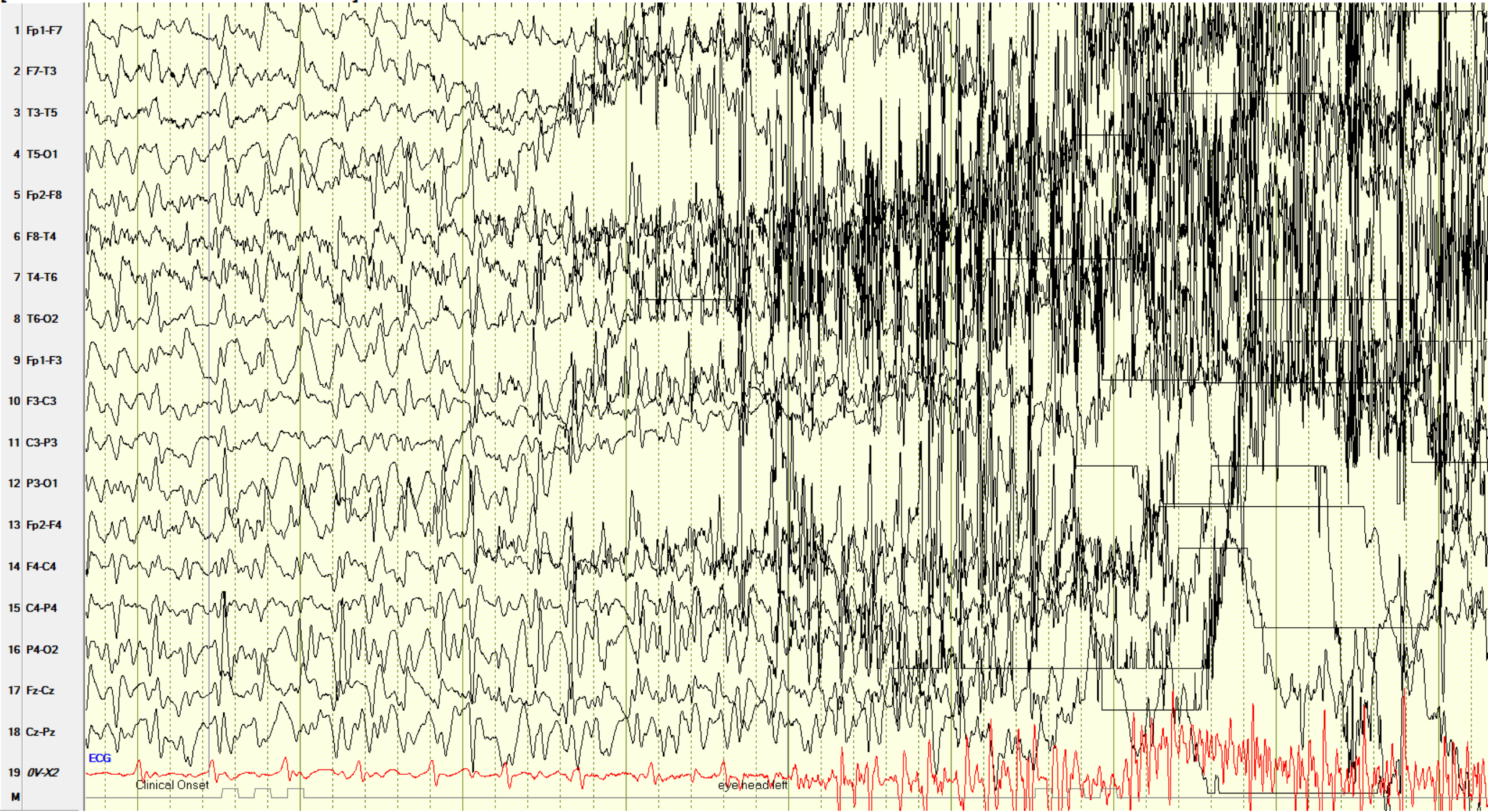
[SENS 7 HF 50RP LF 0.53 CAL 50]

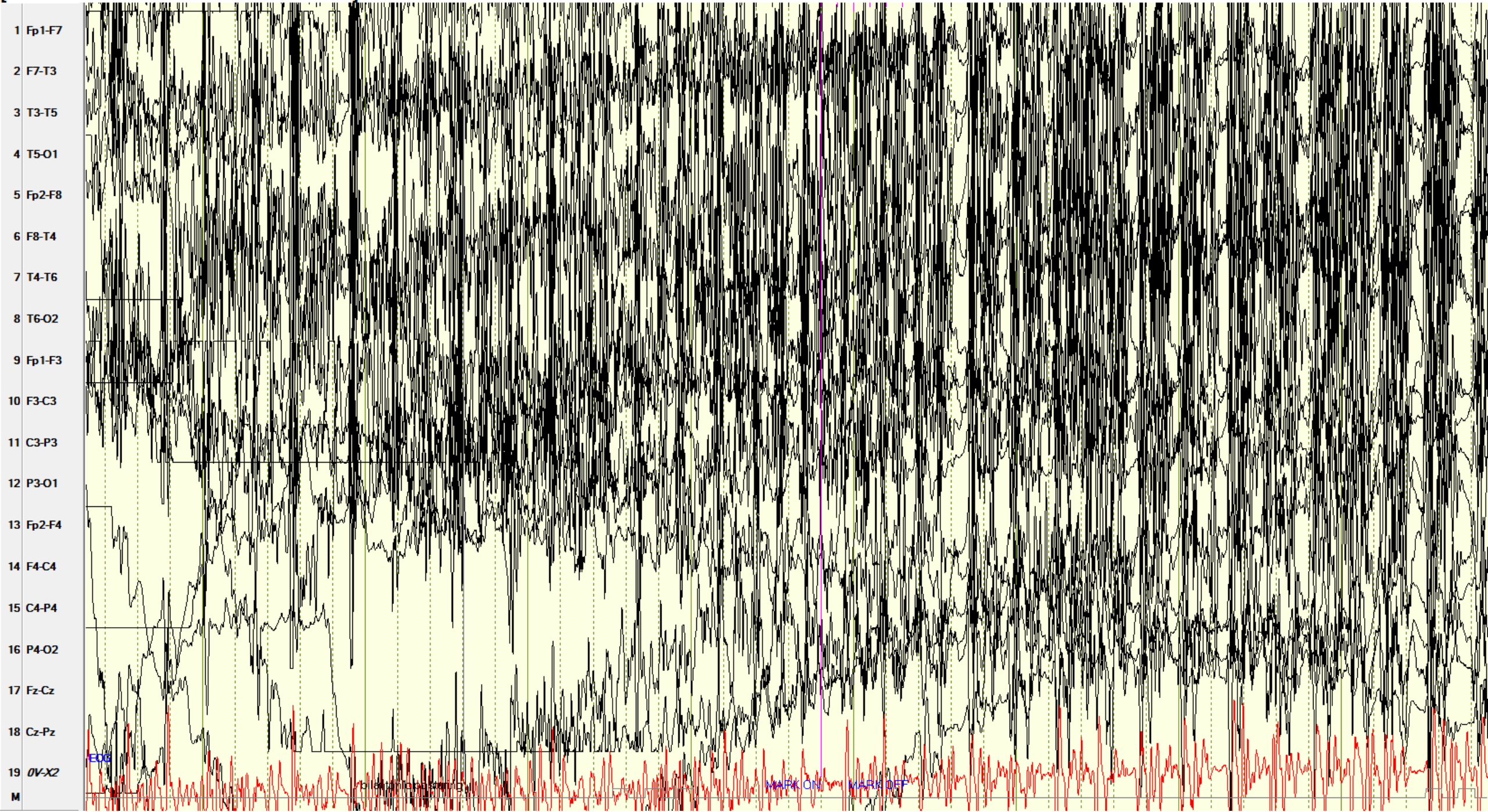


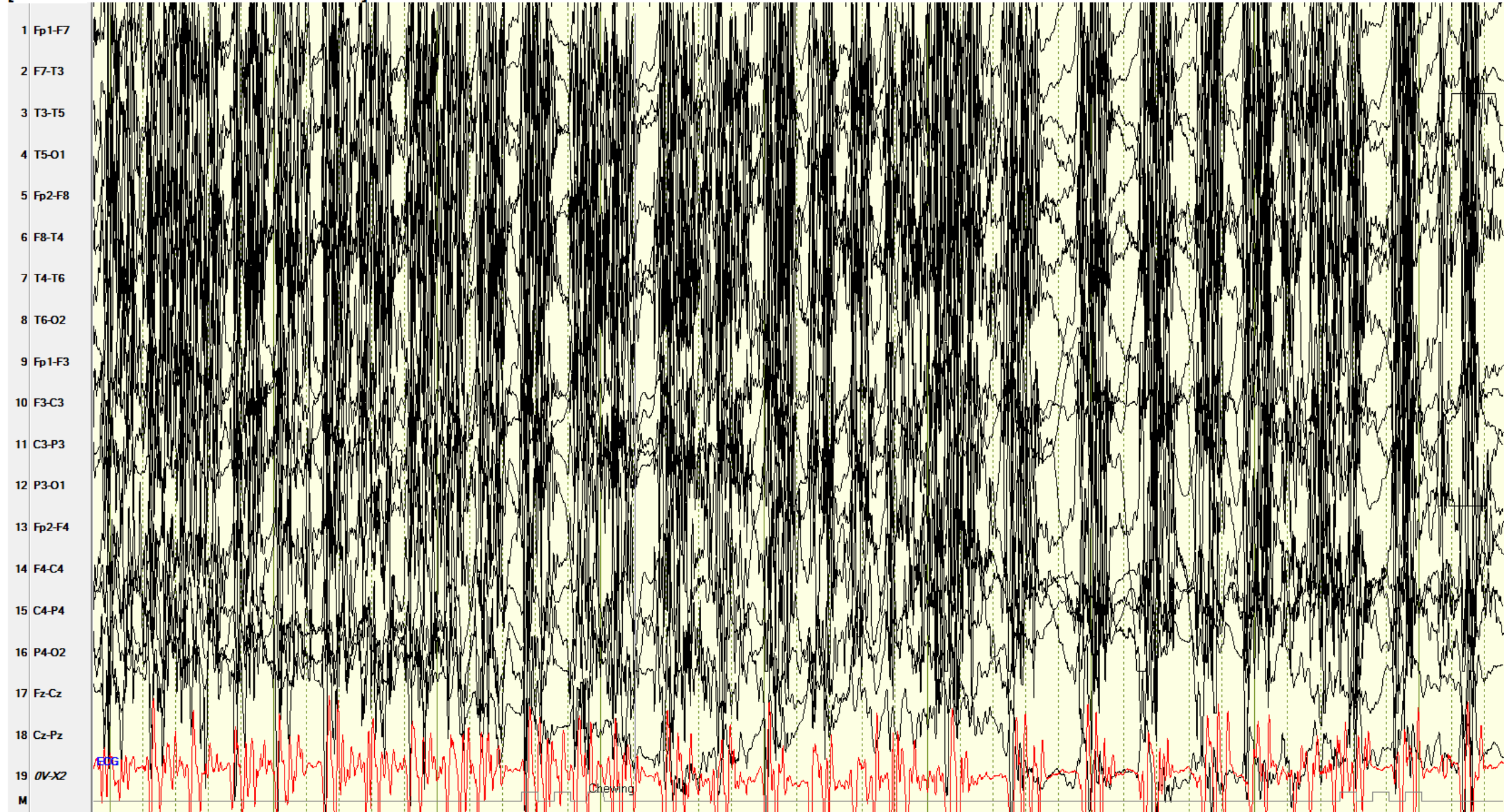


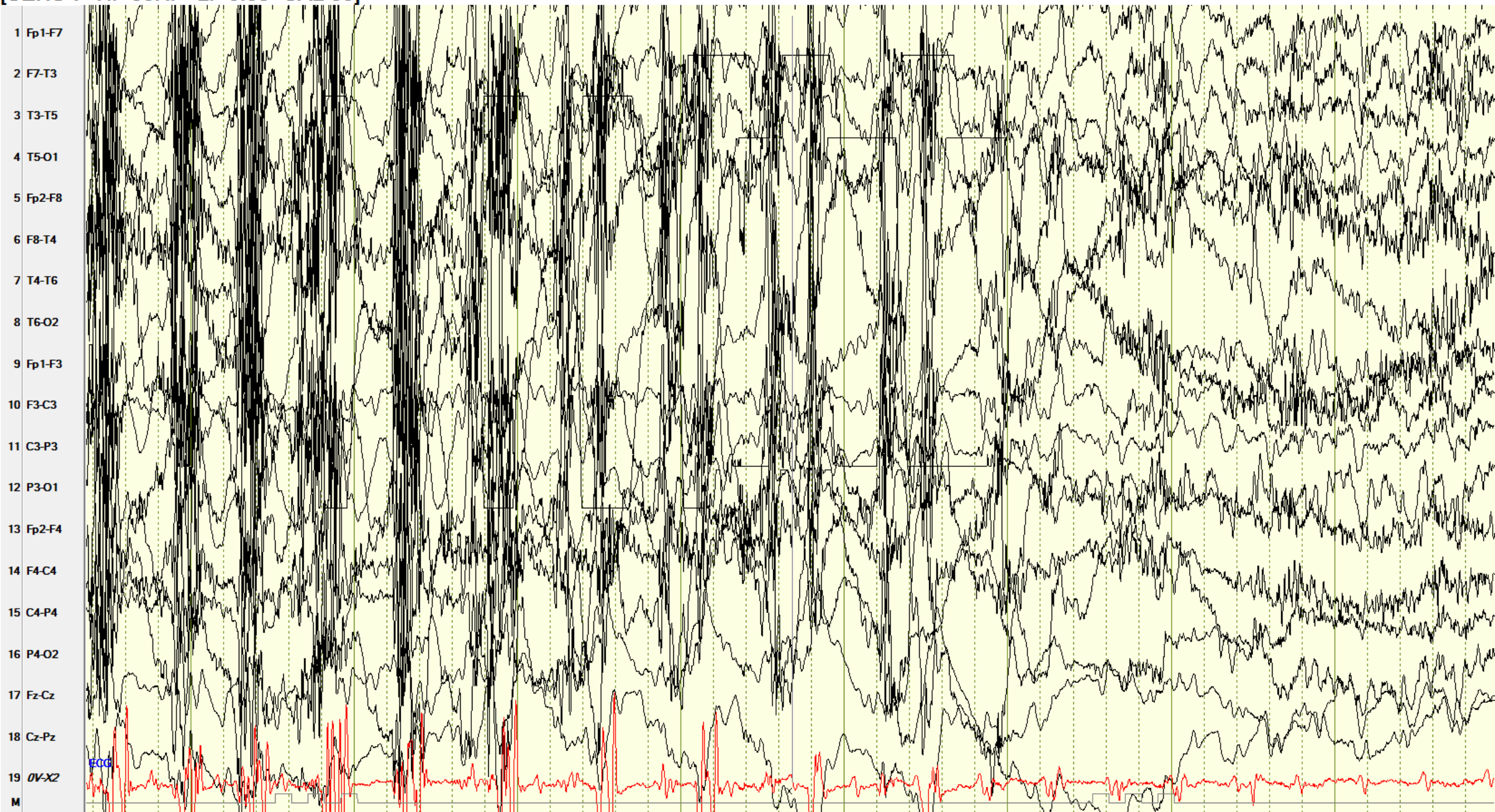


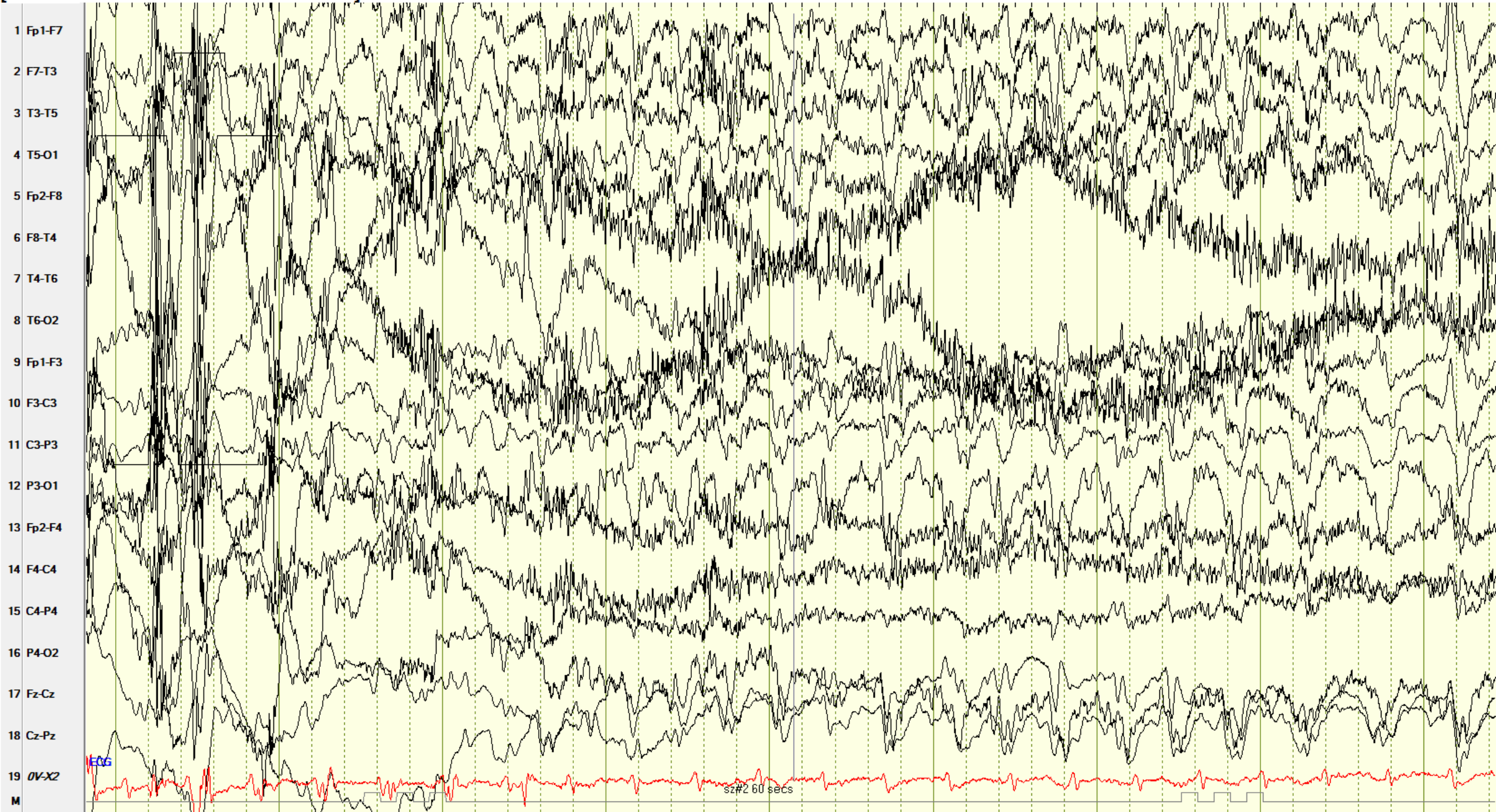


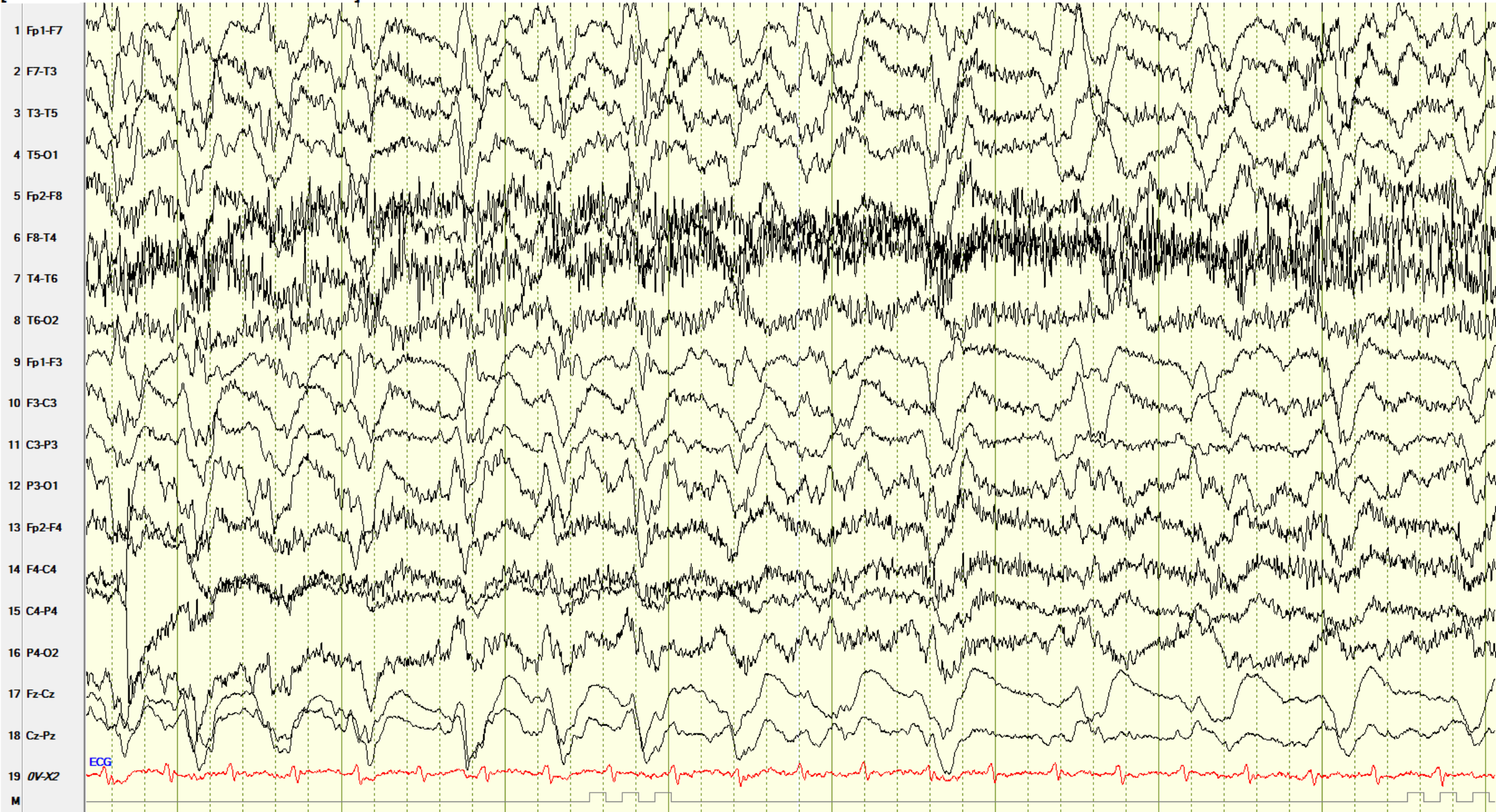


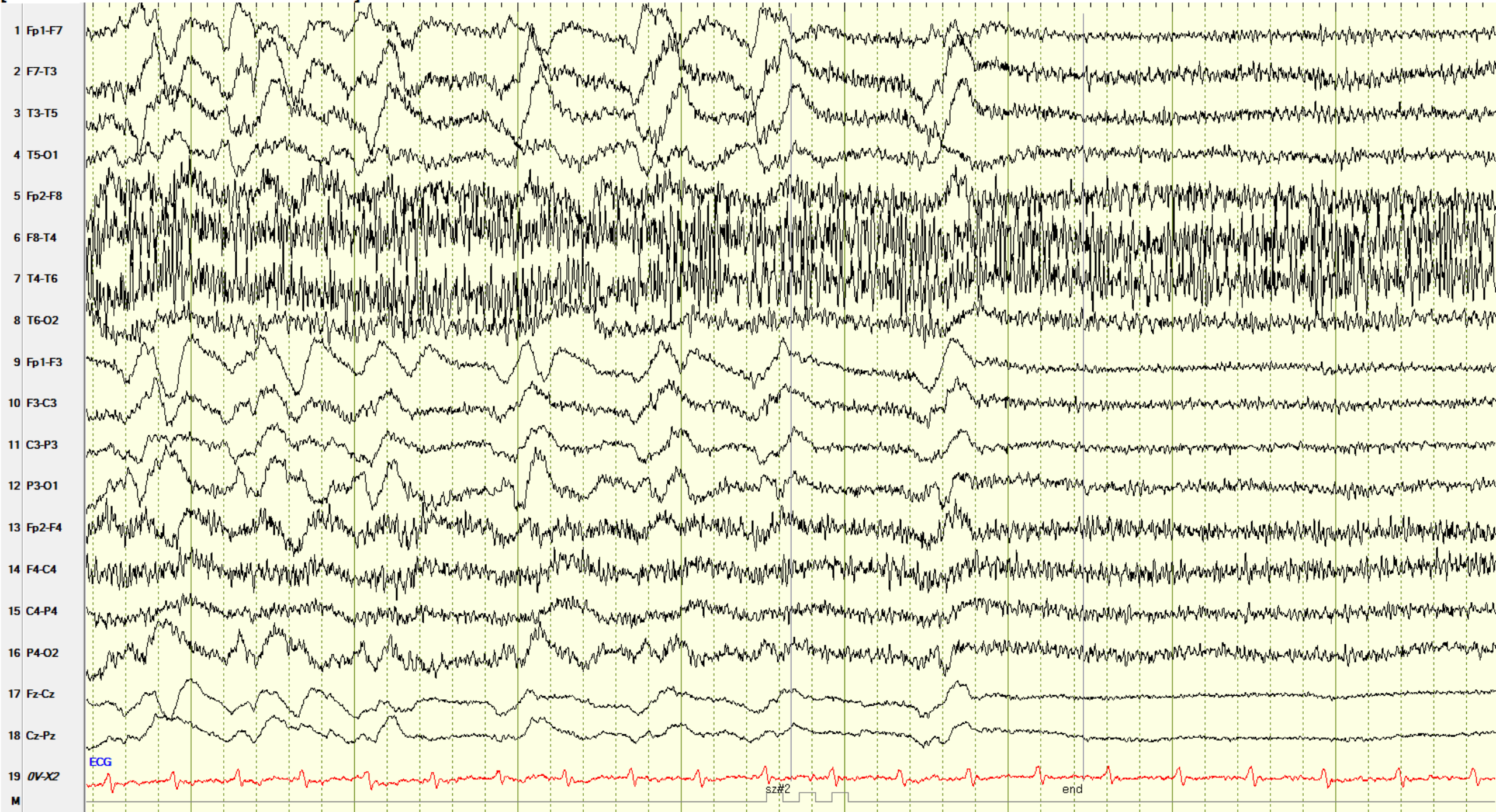










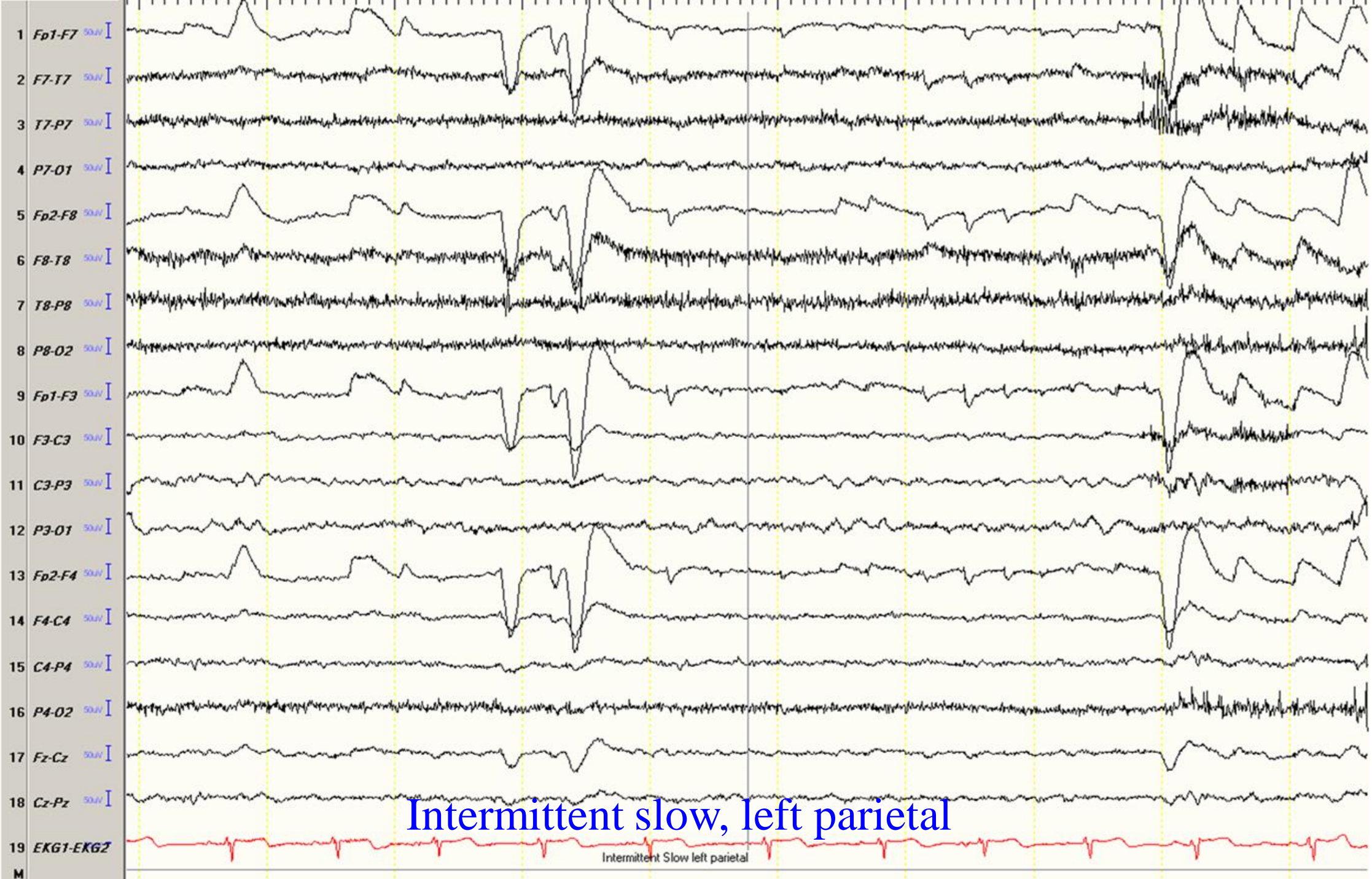
Ictal EEG in occipital lobe epilepsy

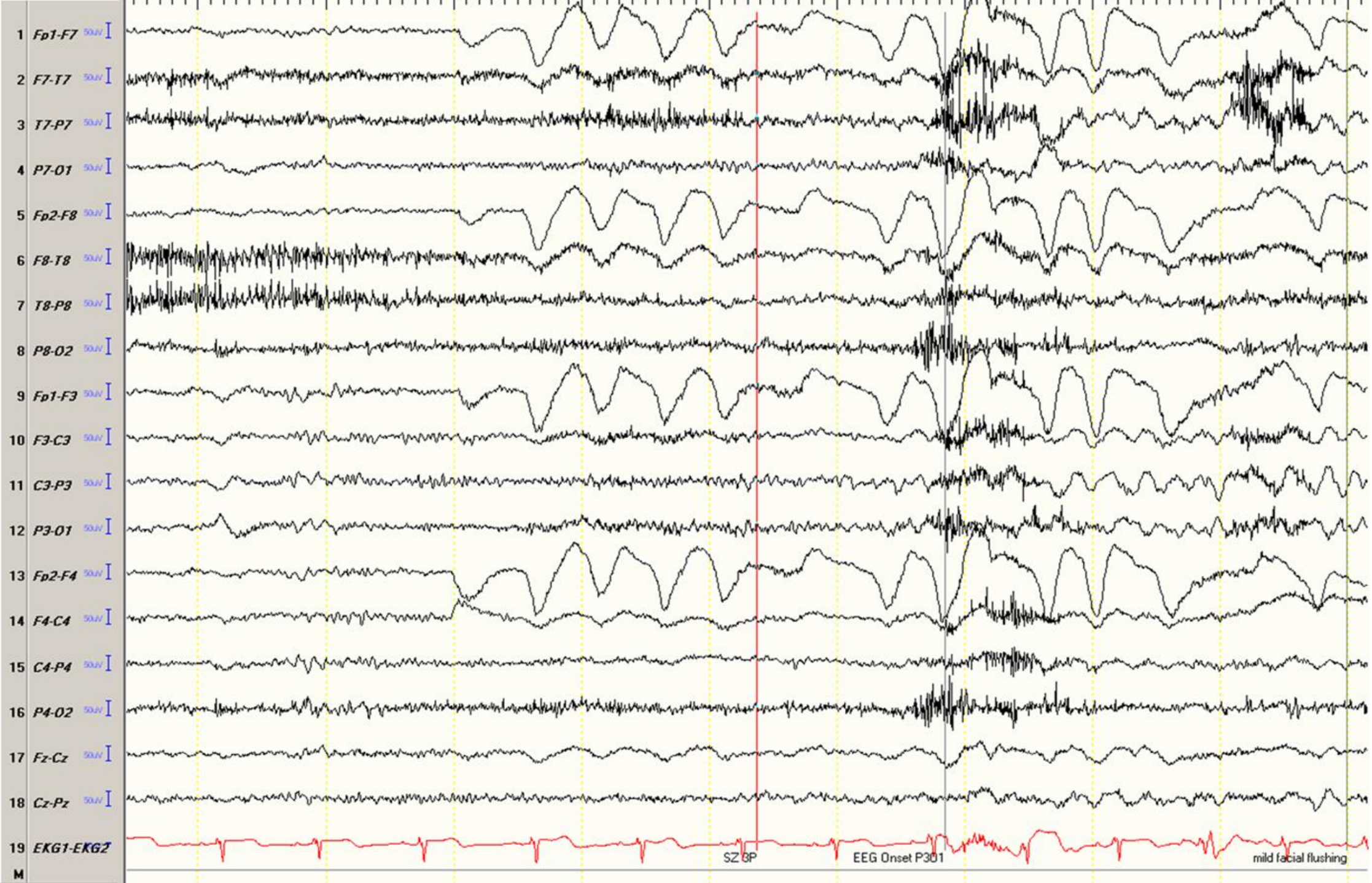
- No specific pattern of ictal scalp EEG has been described.
- Ictal EEG: paroxysmal fast activity, fast spiking or both, localized in the occipital regions

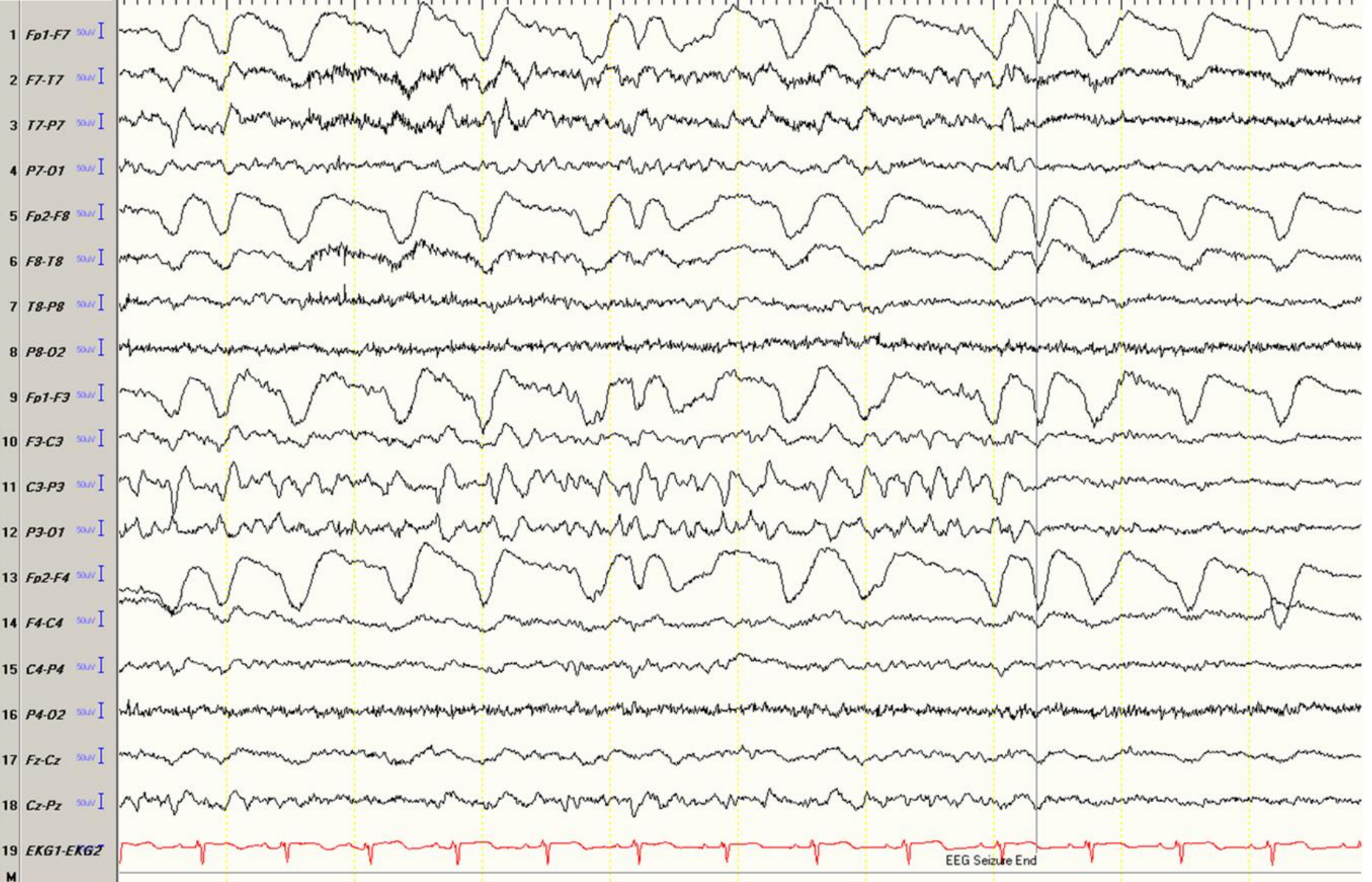
Case#7

- A 15+ yo female with left occipital lobe mass s/p surgery presents with recurrent seizures.

Seizure type1: Her family reports that her expression changes, she can't focus and her face turns red. She then gets lip smacking, eyes deviating to right, eye fluttering with clonic jerking of right arm and leg.







Take home messages

- Epilepsy is a clinical diagnosis.
- The various forms of focal epilepsy generate seizure presentations that are dependent on the anatomic structures that are involved in the seizure.
- Most forms of epilepsy have clear changes on EEG that permit accurate localization, but several pitfalls exist. Thus, the EEG results should be interpreted in the context of the whole clinical setting.

สมาคมโรคลมชักแห่งประเทศไทย



Thank you

